



Arthroscopy-assisted fixation of Ideberg-type Vb glenoid fracture: A case report

Ideberg tip Vb glenoid kırığının artroskopi yardımlı fiksasyonu: Olgu sunumu

Gökhan Ragıp Ulusoy, MD 

Department of Orthopedics and Traumatology, Medical Faculty of Kafkas University, Kars, Turkey

ABSTRACT

In this article, we report a 41-year-old right-handed male patient with Ideberg-type Vb fracture who was treated with arthroscopic reduction and fixation. The patient was a laborer who suffered from a high-energy trauma (fall from height). X-ray revealed an intra-articular fracture of the left scapula. Computed tomography with three-dimension reconstruction confirmed the fracture type to be an Ideberg-type Vb glenoid fracture. The patient was operated, discharged on postoperative day two, and was able to continue his daily activities even at two months postoperatively. At six months, the University of California at Los Angeles shoulder score was 33 of 35 and the Disabilities of the Arm, Shoulder, and Hand questionnaire score was 2 of 100. Arthroscopic reduction and fixation of Ideberg-type Vb fracture appears to be safe with good radiological and clinical outcomes.

Keywords: Arthroscopic, fixation, fracture, glenoid.

ÖZ

Bu yazıda, artroskopik redüksiyon ve fiksasyon ile tedavi edilen, Ideberg tip Vb kırığı olan 41 yaşında, sağ elini kullanan bir hasta sunuldu. Hasta yüksek enerjili travmaya (yüksekten düşme) maruz kalmış bir erkek işçi idi. Radyografisinde sol skapulanın eklem içi kırığı olduğu görüldü. Bilgisayarlı tomografinin üç boyutlu rekonstrüksiyonda kırık tipinin Ideberg tipi Vb glenoid kırığı olduğu saptandı. Hasta ameliyat edildi, ameliyat sonrası ikinci günde taburcu edildi ve ameliyattan iki ay sonra bile günlük aktivitelerine devam edebildi. Altı ayda, Los Angeles California Üniversitesi omuz skoru 35 üzerinden 33; Kol, Omuz ve El Sorunları anketi skoru 100 üzerinden 2 idi. Ideberg tip Vb kırığının artroskopik redüksiyon ve fiksasyonu iyi radyolojik ve klinik sonuçlarla güvenilir görünmektedir.

Anahtar sözcükler: Artroskopik, fiksasyon, kırık, glenoid.

Scapular fractures, particularly those involving extension into the glenoid articular surface, are rare, with most of the literature comprising case series.^[1] Glenoid fractures can be divided into different patterns: avulsions, rim fractures, and fossa fractures. While fossa fractures largely result from the direct impact of the humeral head onto the glenoid fossa, avulsions and rim fractures are associated with shoulder dislocations. These fractures are usually caused due to high-energy trauma. Most of the extra-articular scapular fractures are nonoperatively

managed, but those involving the articular surface often require surgical treatment.^[2]

There are few classification systems for glenoid fractures such as the Ideberg classification, which was developed based on conventional radiographs and comprises six primary fracture types. These fracture types, which were later modified by Goss,^[3] are often reported in the literature. In this article, we demonstrated arthroscopic evaluations as well as reductions and fixations of the Ideberg-type Vb glenoid fracture.

Received: July 09, 2018 Accepted: October 24, 2018

Correspondence: Gökhan Ragıp Ulusoy, MD. Kafkas Üniversitesi Tıp Fakültesi Ortopedi ve Travmatoloji Anabilim Dalı, 36040 Kars, Turkey.
Tel: +90 545 - 457 57 73 e-mail: ulusoyg@hotmail.com

Citation:

Ulusoy GR. Arthroscopy-assisted fixation of Ideberg-type Vb glenoid fracture: A case report. Eklem Hastalıkları Cerrahisi 2019;30(1):61-64.

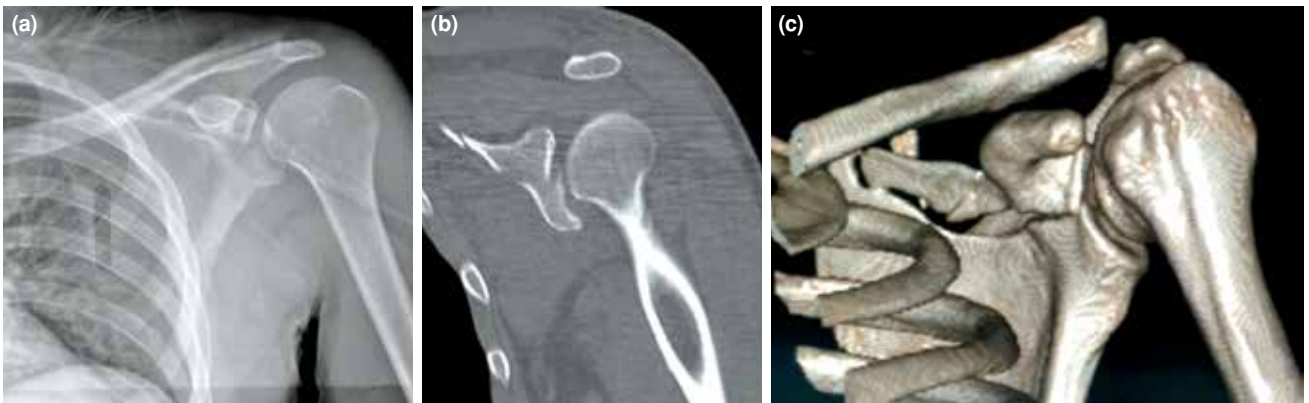


Figure 1. (a) Preoperative anteroposterior radiograph, (b) coronal computed tomography image, (c) three-dimension computed tomography image of left shoulder.

CASE REPORT

A 41-year-old right-handed male patient who worked as a laborer was involved in a high-energy trauma (fall from height). X-ray examinations revealed an intra-articular fracture of the left scapula. Computed tomography (CT) with three-dimension (3D) reconstruction enabled determination of the fracture type to be Ideberg-type Vb. Radiological evaluation was initiated with plain radiographs (Figure 1a), leading to enhanced definition of the fracture pattern, followed by CT (Figure 1b) using 3D images (Figure 1c). In addition, neurological and vascular examinations were performed because these fractures are frequently associated with high-energy trauma. A written informed consent was obtained from the patient.

Under general anesthesia, the patient was placed in beach-chair position. The C-arm was placed from the opposite side. Following prepping and draping, the arthroscopic procedure was initiated. First, the posterior portal was established at 3-cm distal and 1-cm medial positions to the posterolateral tip of the acromion. A 30° arthroscope was inserted, and

the articular surface was evaluated (Figure 2a). Further, the anterior portal was made under direct visualization. The fracture line was palpated using an arthroscopic hook probe to mobilize small fragments followed by removal of all intra-articular and interposed bony fragments using an arthroscopic shaver (Figure 2b). Once the debridement was completed, the superior fragment was examined with a probe to investigate if an anatomic reduction is possible. After confirming the possibility of an anatomic reduction, the Neviaser portal was made in the notch between the posterior acromioclavicular joint and the spine of the scapula. Next, a 3-mm Kirschner wire (K-wire) was inserted from this portal and advanced from the superior glenoid rim under fluoroscopic imaging. The superior glenoid fragment was reduced using a K-wire inserted from the Neviaser portal under direct visualization once the anatomic reduction was achieved; the K-wire was advanced into the inferior glenoid. The two cannulated screw guidewires were placed again from the Neviaser portal from the anterior and posterior regions of the K-wire under fluoroscopic imaging to avoid passing into the far glenoid cortex.

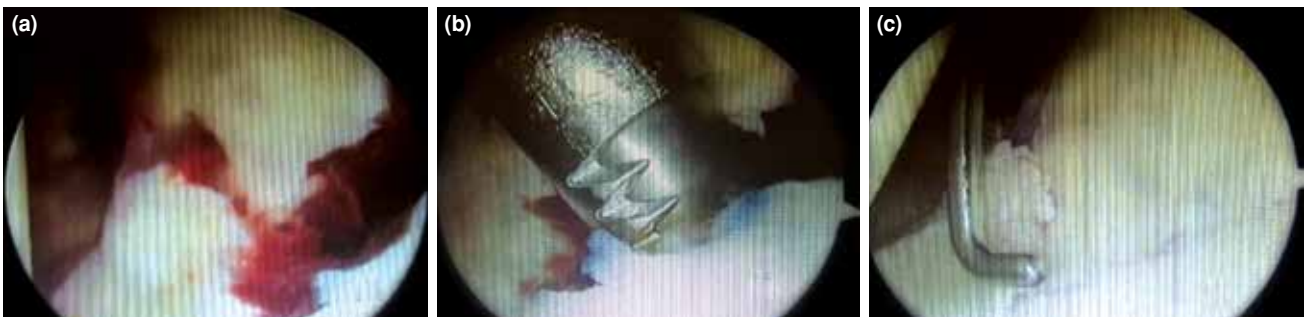

Figure 2. Peroperative images: (a) View from posterior portal of fracture, (b) debridement of small fragments, (c) view of fracture line after fixation.

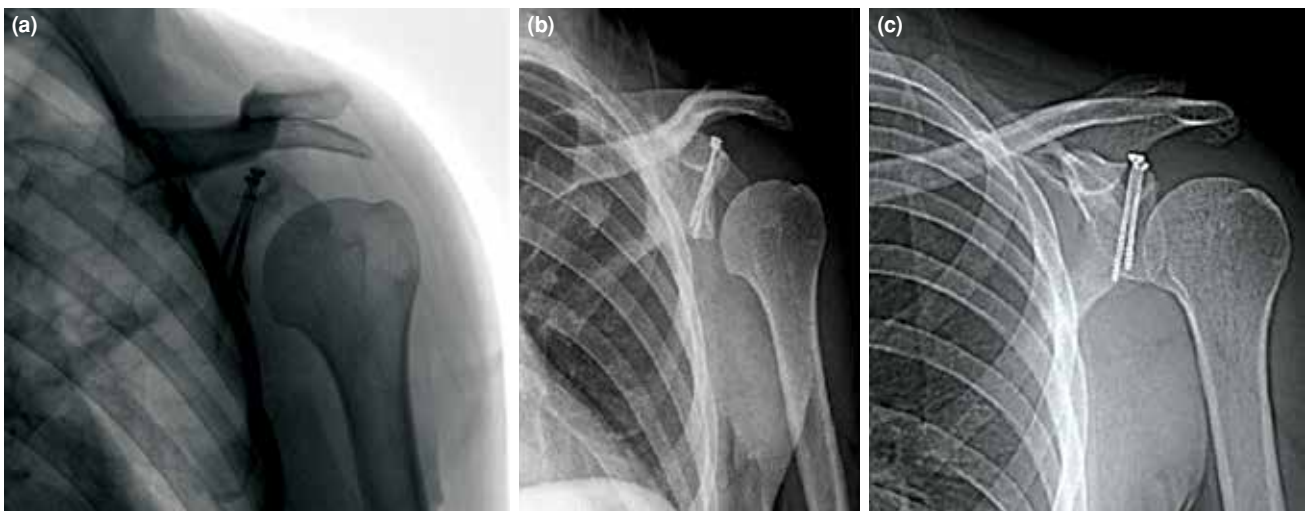


Figure 3. (a) Early postoperative radiograph, (b) radiograph at six weeks, (c) radiograph at six months of left shoulder.

Next, the guidewires were measured to determine the screw length. Fluoroscopy was used during drilling with a 2.7-mm cannulated drill. The partially threaded 4.0-mm cannulated screws were inserted; the fracture site was visualized (Figure 2c) through the posterior portal to avoid any loss of reduction; and fluoroscopy was used to control the advancement of screws. The K-wire was removed before any compression of fracture could occur. Once the compression was achieved, the guidewires were removed, and the final fluoroscopic control was used. After irrigation and evacuation of any remaining debris, the arthroscope was removed, and the skin portals were closed.

The affected upper extremity was placed in a sling for six weeks. A passive range of motion (ROM) was immediately initiated the day after the operation or once after the control X-ray (Figure 3a) was obtained. At four weeks, controlled active ROM was allowed. The control X-rays were also observed at six weeks (Figure 3b) and three months (Figure 3c) postoperatively. At six months, ROM was 170° for flexion, 45° for extension, and 140° for abduction. The external rotation was 45°, and the internal rotation was found to be at L1 level. The University of California at Los Angeles shoulder score was 33 of 35, and the Disabilities of the Arm, Shoulder, and Hand questionnaire score was 2 of 100. At this moment, the patient was allowed to return to work.

DISCUSSION

The treatment of most scapular fractures is conservative, whereas that of glenoid fossa fractures depends on the fragment size and degree

of displacement. A fracture gap or step-off of >4 mm, along with any evidence of instability, requires anatomic reduction and internal fixation of the fracture. A displaced anterior rim fracture with >25% involvement of the articular surface or >33% involvement of the posterior articular surface can result in instability, thereby requiring surgical treatment.^[4] A posterior approach is used for fractures involving the glenoid fossa, whereas anterior deltopectoral approach is used in case of an anterior or inferior rim of the glenoid fractures. Although excellent or good results were reported, the disadvantages of an open approach are large incisions, postoperative weakness, and large soft tissue stripping. Infection, heterotopic ossification, and infraspinatus nerve palsy have been reported as complications.^[5-9]

Shoulder arthroscopy is a minimally invasive procedure, which leads to less scar tissue, quick healing, and early rehabilitation. Arthroscopic percutaneous fixation of the different types of glenoid fractures have been reported in the literature. The first discussion was for the Ideberg-type 1a fracture.^[10] Bauer et al.^[11] described a fixation technique for the Ideberg-type Ia and Ib fractures. There are few reports on the Ideberg-type III fractures,^[12-14] although they tend to have excellent outcomes. Arthroscopic fixation of the Ideberg-type V variant with an inferior fragment has been reported by Tuman et al.^[1] In this report, the arthroscopic technique addresses only the glenoid articular surface and not the scapular extension.

In this article, we report the case of a patient with Ideberg-type Vb fracture.^[15] The scapular extension

of the fracture remains to be addressed; however, our primary goal was to restore the articular surface, which was carefully achieved using two cannulated screws inserted from the Neviaser portal. This reduction was handled by manipulating the superior fragment with a K-wire inserted from the Neviaser portal and held in place by advancing the K-wire from the inferior fragment. As emphasized in the literature, it is important to use fluoroscopy during advancement of the guidewires and the drill bit over the guidewires in order to prevent any injury to the axillary neurovascular structures from the tip of the guidewires.^[16]

In conclusion, the arthroscopic reduction and fixation of the Ideberg-type Vb fracture seems to be a safe procedure with good radiological and clinical outcomes.

Declaration of conflicting interests

The author declared no conflicts of interest with respect to the authorship and/or publication of this article.

Funding

The author received no financial support for the research and/or authorship of this article.

REFERENCES

1. Tuman JM, Bishop JA, Abrams GD. Arthroscopic Reduction and Internal Fixation of an Inferior Glenoid Fracture With Scapular Extension (Ideberg V). *Arthrosc Tech* 2015;4:869-72.
2. Frich LH, Larsen MS. How to deal with a glenoid fracture. *EFORT Open Rev* 2017;2:151-7.
3. Goss TP. Fractures of the glenoid cavity. *J Bone Joint Surg [Am]* 1992;74:299-305.
4. Cole PA, Freeman G, Dubin JR. Scapula fractures. *Curr Rev Musculoskelet Med* 2013;6:79-87.
5. Adam FF. Surgical treatment of displaced fractures of the glenoid cavity. *Int Orthop* 2002;26:150-3.
6. Anavian J, Gauger EM, Schroder LK, Wijdicks CA, Cole PA. Surgical and functional outcomes after operative management of complex and displaced intra-articular glenoid fractures. *J Bone Joint Surg [Am]* 2012;94:645-53.
7. Hardegger FH, Simpson LA, Weber BG. The operative treatment of scapular fractures. *J Bone Joint Surg [Br]* 1984;66:725-31.
8. Kavanagh BF, Bradway JK, Cofield RH. Open reduction and internal fixation of displaced intra-articular fractures of the glenoid fossa. *J Bone Joint Surg [Am]* 1993;75:479-84.
9. Mayo KA, Benirschke SK, Mast JW. Displaced fractures of the glenoid fossa. Results of open reduction and internal fixation. *Clin Orthop Relat Res* 1998;347:122-30.
10. Cameron SE. Arthroscopic reduction and internal fixation of an anterior glenoid fracture. *Arthroscopy* 1998;14:743-6.
11. Bauer T, Abadie O, Hardy P. Arthroscopic treatment of glenoid fractures. *Arthroscopy* 2006;22: 569.e1-6.
12. Tao MA, Garrigues GE. Arthroscopic-Assisted Fixation of Ideberg Type III Glenoid Fractures. *Arthrosc Tech* 2015;4:119-25.
13. Yang HB, Wang D, He XJ. Arthroscopic-assisted reduction and percutaneous cannulated screw fixation for Ideberg type III glenoid fractures: a minimum 2-year follow-up of 18 cases. *Am J Sports Med* 2011;39:1923-8.
14. Bonczek SJ, Hutchinson R, Chakravarthy J. An innovative method of fracture reduction in an arthroscopically assisted cannulated screw fixation of an Ideberg type III glenoid fracture. *Int J Shoulder Surg* 2015;9:56-9.
15. Atik OŞ. Are all case reports worth publishing? *Eklem Hastalıkları Cerrahisi* 2016;27:61.
16. Papadonikolakis A. Arthroscopic reduction and fixation of transverse intra-articular glenoid fractures with scapular extension. *Arthrosc Tech* 2017;6:e879-e85.