Joint Diseases and Related Surgery

Jt Dis Relat Surg
2026;37(1):i-xi

ORIGINAL ARTICLE

Comparison of unilateral biportal and percutaneous endoscopic discectomy in treating far lateral lumbar disc herniation

Yisong Sun, MD, Dasheng Tian, MD, Lei Chen, MD, Bin Zhu, MD, Huazhang Zhong, MD, Juehua Jing, MD

Department of Orthopaedics, The Second Affiliated Hospital of Anhui Medical University, Hefei, China

ABSTRACT

Objectives: This study aims to investigate the clinical efficacy of managing far lateral lumbar disc herniation (FLLDH) through two surgical approaches: unilateral biportal endoscopy (UBE) and percutaneous endoscopic lumbar discectomy (PELD).

Patients and methods: Between December 2019 and September 2024, a total of 45 patients (18 males, 27 females; mean age: 59.76±11.82 years; range, 31 to 89 years) who were diagnosed with FLLDH were retrospectively analyzed. Based on the surgical technique used, the patients were randomly divided into two groups: the PELD group (n=17) and the UBE group (n=28). Perioperative indicators, including operative time, postoperative hospital stay and mean fluoroscopy times, were recorded. Pre- and postoperative assessments were conducted at the time of admission and at one, three, and six months after surgery, using the Visual Analog Scale (VAS) and the Oswestry Disability Index (ODI) scores. The modified MacNab criteria were used to assess patient satisfaction.

Results: Both groups demonstrated a reduction in VAS and ODI scores after surgery ($p<0.05$). However, no statistically significant differences were observed between the groups at one, three, or six months postoperatively. Operative times were also comparable, with the UBE group mean 97.39±26.78 min and the PELD group 88.18±27.52 min. The postoperative length of hospital stay was similar, with the UBE group staying a mean of 3.93±1.81 days and the PELD group 3.06±1.21 days ($p>0.05$). The mean fluoroscopy times were significantly lower in the UBE group, with 6.25±1.30 times compared to 16.76±6.02 times in the PELD group ($p<0.05$).

Conclusion: Our study results suggest that UBE is a viable alternative to PELD for treating FLLDH, offering comparable clinical outcomes with reduced radiation exposure.

Keywords: Clinical efficacy, far lateral lumbar disc herniation, minimally invasive spine surgery, percutaneous endoscopic lumbar discectomy, unilateral biportal endoscopy.

Far lateral lumbar disc herniation (FLLDH) is a distinct type of lumbar disc problem, characterized by its unique clinical features, diagnostic challenges and treatment difficulties. Although less common than standard lumbar disc herniations, FLLDH accounts for approximately 3 to 12% of all lumbar disc herniations and is associated with intense radicular pain due to compression of the exiting nerve root in the narrow extraforaminal space.[1-3]

Historically, the treatment of FLLDH has included both conservative and surgical interventions, with varying degrees of success.[4] Traditional open surgeries provide sufficient decompression but often involve extensive disruption of muscle and soft tissue. In recent years, minimally invasive techniques, particularly endoscopic approaches, have become increasingly popular due to reduced trauma, faster recovery and comparable efficacy.[5,6] However, these procedures also carry risks such as nerve injury, incomplete decompression and symptom recurrence.[7,8]

Received: April 15, 2025
Accepted: July 28, 2025
Published online: October 31, 2025

Correspondence: Juehua Jing, MD. Department of Orthopaedics, The Second Affiliated Hospital of Anhui Medical University, Hefei, Anhui Province, 230601, China.

E-mail: jingjhhu@sina.cn

Doi: 10.52312/jdrs.2026.2326

Citation: Sun Y, Tian D, Chen L, Zhu B, Zhong H, Jing J. Comparison of unilateral biportal and percutaneous endoscopic discectomy in treating far lateral lumbar disc herniation. Jt Dis Relat Surg 2026;37(1):i-xi. doi: 10.52312/jdrs.2026.2326.

©2026 All right reserved by the Turkish Joint Diseases Foundation

This is an open access article under the terms of the Creative Commons Attribution-NonCommercial License, which permits use, distribution and reproduction in any medium, provided the original work is properly cited and is not used for commercial purposes (http://creativecommons.org/licenses/by-nc/4.0/).

Recent developments in spinal endoscopy, most notably unilateral biportal endoscopy (UBE) and percutaneous endoscopic lumbar discectomy (PELD), have broadened the scope of minimally invasive spine surgery. Both techniques have shown promising results in general lumbar disc herniations,[9,10] but their application in FLLDH remains relatively underexplored. Although a few retrospective studies and small case series have examined their use in FLLDH, they differ in methodology, patient selection, outcome definitions and follow-up duration, limiting generalizability of the results. Some studies lack a direct comparison between UBE and PELD in the context of FLLDH, whereas others report only short-term outcomes or do not stratify data by herniation location.[11-13]

To the best of our knowledge, no large-scale, prospective, randomized trials or meta-analyses have specifically addressed the comparative effectiveness of UBE versus PELD in FLLDH. Existing meta-analyses on UBE and PELD focus largely on central or paracentral disc herniations,[14,15] thereby creating a knowledge gap for surgeons managing far lateral lesions, which involve different anatomical considerations and require distinct surgical strategies.

In the present study, we aimed to directly compare the clinical outcomes of UBE and PELD in patients with FLLDH and to analyze postoperative pain, functional recovery, operative time, fluoroscopy frequency and complications in order to provide valuable clinical evidence to guide treatment selection for this challenging condition.

PATIENTS AND METHODS

This single-center, retrospective study was conducted at Second Affiliated Hospital of Anhui Medical University, Department of Orthopaedics between December 2019 and September 2024. The patients who underwent surgical treatment for FLLDH and had a minimum follow-up period of six months were screened. Inclusion criteria were as follows: having a diagnosis of single-segment FLLDH confirmed by magnetic resonance imaging or computed tomography; presence of lower limb radicular pain and/or numbness corresponding to imaging findings; and failure of conservative treatment for at least three months or severe symptoms substantially affecting quality of life. Exclusion criteria were as follows: lumbar instability, tumors, deformities or infections; inability to complete follow-up assessments; substantial comorbidities constituting surgical contraindications; and multi-segmental surgical procedures. Finally, a total of 45 patients (18 males, 27 females; mean age: 59.76±11.82 years; range, 31 to 89 years) who met the inclusion criteria were recruited. Based on the surgical technique used, the patients were randomly divided into two groups: the PELD group (n=17) and the UBE group (n=28). Data were collected systematically at the time of admission and at one, three, and six months after surgery. Written informed consent was obtained from each patient. The study protocol was approved by the Second Affiliated Hospital of Anhui Medical University Ethics Committee (Date: 19.09.2019, No: slxjs2019-001). The study was conducted in accordance with the principles of the Declaration of Helsinki.

Surgical procedures

Two surgical techniques were used in this study: UBE and PELD. All procedures were performed by three senior spine surgeons with extensive experience in both UBE and PELD, all having completed more than 200 independent cases of each technique prior to the study. Assignment to UBE or PELD was based on the surgeon's clinical discretion after evaluating imaging features, anatomical considerations and patient preference.

Unilateral biportal endoscopy

After induction of general anesthesia, the patient was placed in the prone position on a radiolucent surgical pad, allowing the abdomen to hang freely and reducing intra-abdominal pressure. Using a right-sided L4/5 FLLDH case as an example, a Kirschner wire (K-wire) was placed perpendicular to the ground under anteroposterior fluoroscopy to identify the midline. Lateral fluoroscopy was then used to align the L4/5 intervertebral space horizontally. Another K-wire was placed 1 to 2 cm lateral to the midline at the L4 pedicle level to mark the target segment.

After skin preparation, two transverse incisions were made: the cranial incision at the lower edge of the transverse process and the caudal incision approximately 1.5 cm inferior to it. The cranial portal was designated for instruments, and the caudal portal was designated for endoscopic observation (Figure 1). Sequential dilators were employed for blunt dissection of soft tissues, followed by the insertion of a retractor. The paraspinal muscles were, then, separated to fully expose the transverse process (Figure 2).

A 30° endoscope was inserted through the observation portal, with continuous irrigation provided by a 3 L saline bag suspended 60 cm

above the wound. Soft tissues over the facet joint and transverse process were cleared. In some cases, large vessels between the transverse process and the facet joint were carefully preserved (Figure 3). The facet joint was marked under endoscopic vision using a K-wire (Figure 4). A high-speed burr was used to remove parts of the transverse process and lateral facet to expose the ligamentum flavum, which was, then, excised. The compressed nerve root and herniated disc fragments were visualized and removed (Figure 5). Hemostasis was achieved using a radiofrequency probe, followed by the placement of a drainage tube and layered closure of the incision.[13]

Percutaneous endoscopic lumbar discectomy

The patient was placed prone on a specialized surgical pad that allowed the abdomen to hang freely, reducing intra-abdominal pressure. In a representative case of right-sided L4/5 FLLDH, a K-wire was positioned vertically at the midline under C-arm fluoroscopy. Lateral fluoroscopy adjusted the intervertebral space to be perpendicular to the floor for optimal exposure, followed by anteroposterior fluoroscopic confirmation.

The puncture site was located approximately 8 cm lateral to the L4 pedicle and 10 cm from the midline, forming a 10 to 15° angle with the

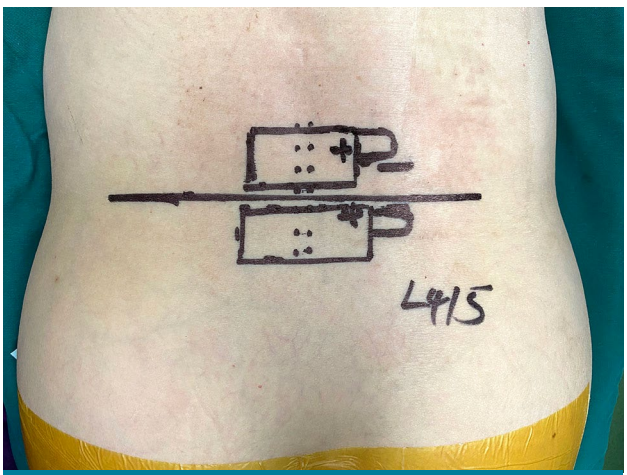

FIGURE 1. Unilateral biportal endoscopy body surface localization.

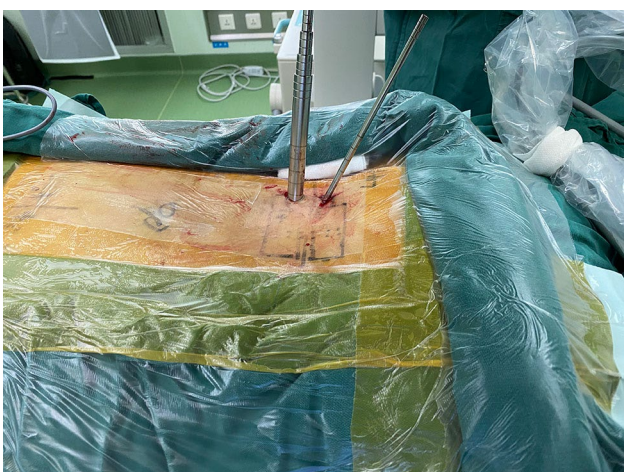

FIGURE 2. Operating portal and observation portal.

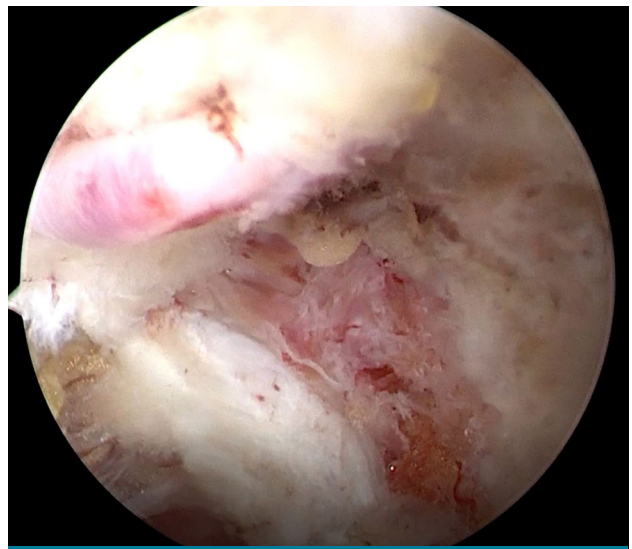

FIGURE 3. Vessels between transverse and articular processes under the endoscopic view during unilateral biportal endoscopy.

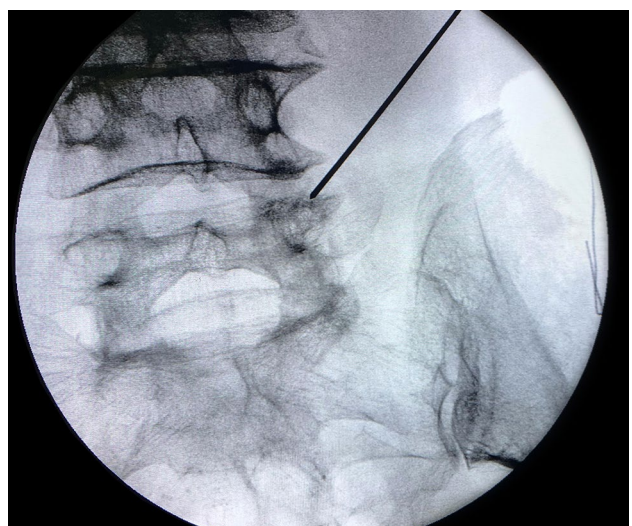

FIGURE 4. Anteroposterior fluoroscopic image showing K-wire localization of the facet joint. A K-wire is placed percutaneously and directed toward the surface of the superior articular process under C-arm guidance.

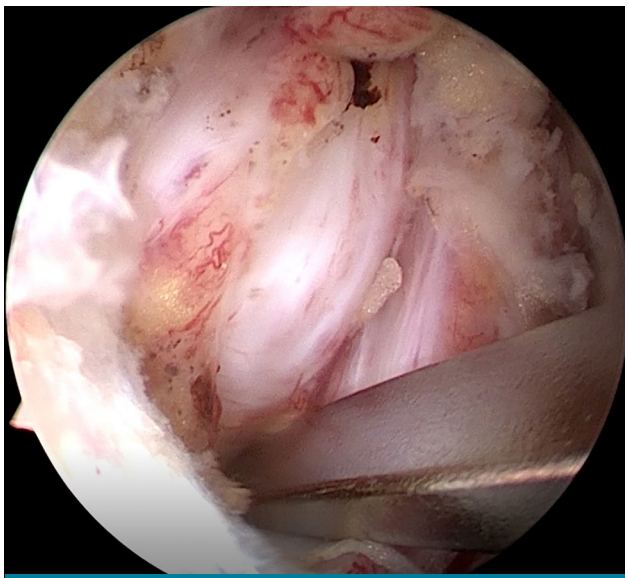

FIGURE 5. Nerve roots and herniated intervertebral discs under the endoscopic view during unilateral biportal endoscopy.

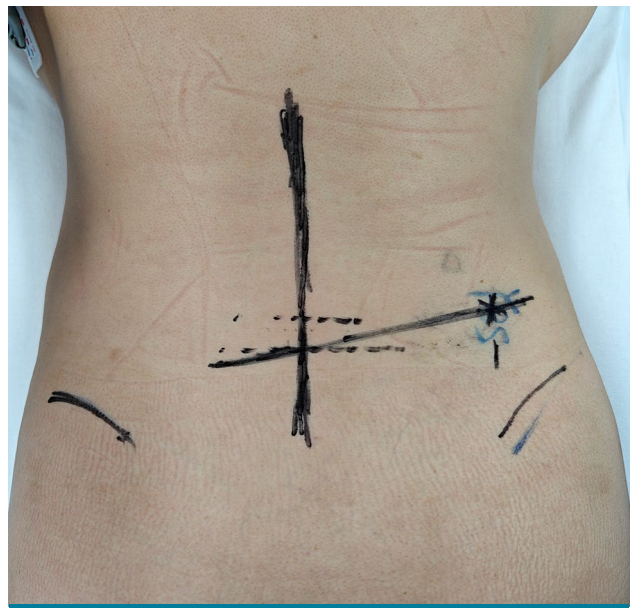

FIGURE 6. Body surface markers of surgical incision of percutaneous endoscopic lumbar discectomy.

intervertebral space (Figure 6). After sterile preparation, an 18-gauge puncture needle was advanced to the lateral surface of the superior articular process (SAP) and local anesthesia with 0.5% lidocaine was administered around the SAP and foramen. A 1-cm incision was made, and a guidewire was inserted to guide a blunt guiding rod to the bony surface. A working cannula was, then, placed laterally and confirmed fluoroscopically (Figures 7a, b). The endoscope (Spinendos System, München, Germany) was introduced.

Under endoscopic view, soft tissues over the SAP were dissected. A high-speed micro-drill was used to remove part of the lateral SAP to access the intervertebral foramen, avoiding damage to the joint capsule. Meticulous hemostasis was maintained.

The endoscope was advanced into the foramen to visualize the upper margin of the L5 vertebra. Nerve roots and herniated disc material were exposed. Numerous small vessels around the nerve were carefully coagulated using

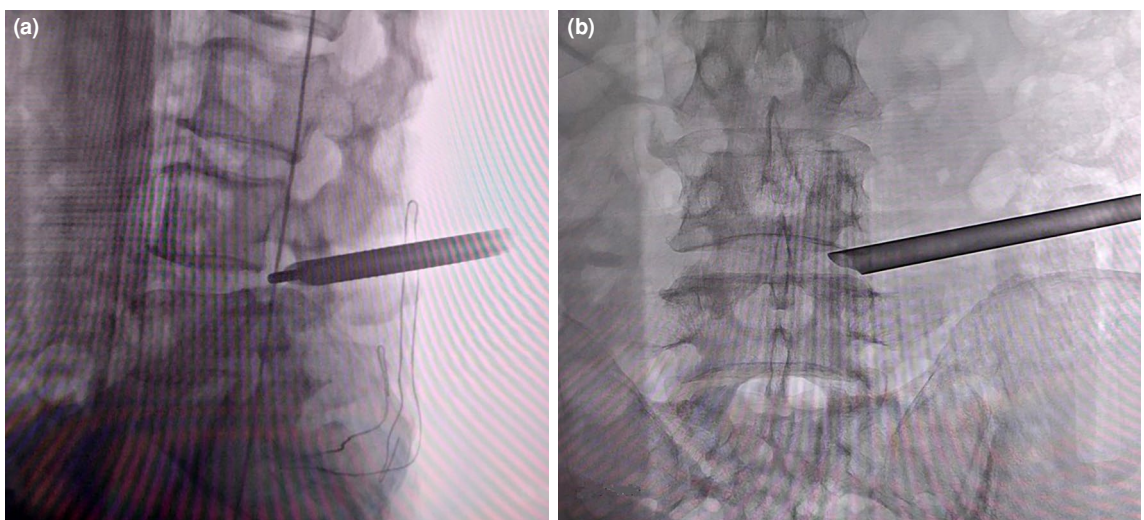

FIGURE 7. A working cannula was inserted laterally, confirmed by C-arm fluoroscopy. **(a)** Lateral cannula. **(b)** Anteroposterior cannula.

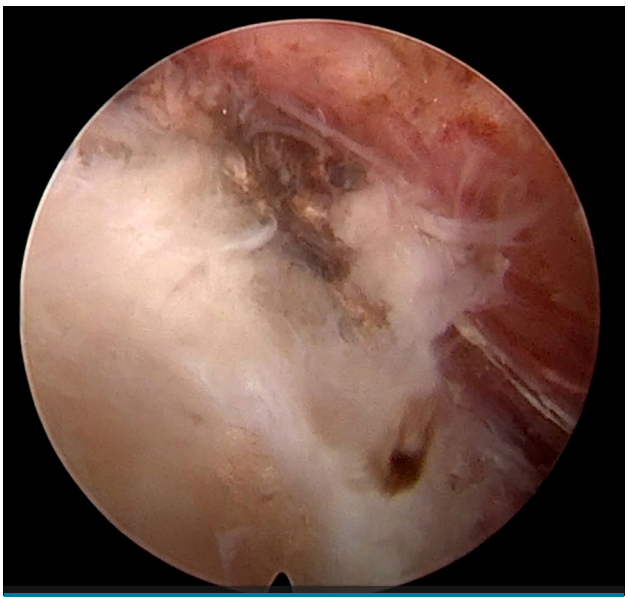

FIGURE 8. Nerve roots and herniated intervertebral discs under the endoscopic view during percutaneous endoscopic lumbar discectomy.

radiofrequency (Figure 8). The herniated disc was completely removed, and final hemostasis was achieved using a radiofrequency probe. The working sheath was removed, and the incision was sutured.[14]

Data collection

Data were retrospectively collected from the electronic medical records of all patients included in the study. Patients were followed in the clinical setting at one, three, and six months postoperatively. During these visits, recurrence of symptoms, reoperation rates and other postoperative complications such as adverse events related to the surgical procedure, such as dural tear, incision site infection or nerve root injury were recorded.

The following parameters were systematically documented at baseline (on admission) and at one, three, and six months postoperatively: demographic and clinical characteristics, including age, sex and body mass index (BMI); clinical assessment, including Visual Analog Scale (VAS) scores for pain intensity[15] and Oswestry Disability Index (ODI) scores for functional impairment;[16] and patient satisfaction and clinical outcome, assessed using the modified MacNab criteria.[17] For perioperative evaluation, operative time, length of postoperative hospital stay and mean fluoroscopy exposures were measured.

All data were extracted by a trained research assistant from electronic medical records and surgical reports to ensure accuracy and completeness. Any missing or unclear data were clarified exclusively through a review of supplementary documentation, such as imaging reports, surgical notes and follow-up records.

Statistical analysis

Statistical analysis was performed using the IBM SPSS version 26.0 software (IBM Corp., Armonk, NY, USA). Continuous data were presented in mean ± standard deviation (SD) or median (min-max), while categorical data were presented in number and frequency. Comparisons between groups were conducted using the independent samples t-test for normally distributed continuous variables, including VAS scores, ODI scores and perioperative indicators. Categorical variables were analyzed using the chi-square test or Fisher exact test, where applicable. A p value of <0.05 was considered statistically significant.

RESULTS

There were no significant differences between the two groups in terms of age, sex, BMI, duration of symptoms, segment of disc herniation, presence of comorbidities such as chronic medical conditions potentially affecting surgical risk or postoperative recovery or clinical symptoms ($p>0.05$) (Table I). No patients in either group experienced symptomatic recurrence or required reoperation during the six-month follow-up period.

The mean operative time (97.39±26.78 min in the UBE group *vs.* 88.18±27.52 min in the PELD group, $p>0.05$) and postoperative hospital stay (3.93±1.18 days in the UBE group *vs.* 3.06±1.21 days in the PELD group; $p>0.05$) did not differ significantly between the groups. However, the mean intraoperative fluoroscopy exposure was significantly lower in the UBE group (6.25±1.30) than in the PELD group (16.76±6.02) ($p<0.05$). The surgical cost of UBE was also significantly higher than that of PELD (Table II).

The VAS and ODI scores in both groups were significantly reduced from preoperative values ($p<0.05$). Additionally, there were no significant differences in VAS or ODI scores between the PELD and UBE groups at one, three, and six months postoperatively ($p>0.05$) (Figures 9 and 10). According to the modified MacNab criteria, the excellent/good rate in the PELD group was 94.12%, whereas in the UBE group, it was 85.17% indicating no statistically significant difference ($p=0.635$) (Table III).

TABLE I
Baseline characteristics of the patients

Characteristic	UBE group (n=28) n	UBE group (n=28) Mean±SD	PELD group (n=17) n	PELD group (n=17) Mean±SD	*p*
Age (year)		58.96±10.99		61.06±12.98	0.575
Sex					0.90
Male	11		7		
Female	17		10		
Body mass index (kg/m^2)		25.26±2.61		25.22±2.74	0.762
Segment					0.904
L3-4	3		1		
L4-5	11		8		
L5-S1	14		8		
Presence of comorbidities	5		3		0.590
Clinical symptoms					
Numbness	18		12		0.34
Low back pain	23		13		0.71

UBE: Unilateral biportal endoscopy; PELD: Percutaneous endoscopic lumbar discectomy; SD: Standard deviation.

TABLE II
Perioperative outcomes

Outcome	UBE group (n=28) Mean±SD	PELD group (n=17) Mean±SD	*p*
Operative time (min)	97.39±26.78	88.18±27.52	0.285
Postoperative hospital stay (day)	3.93±1.18	3.06±1.21	0.093
Intraoperative fluoroscopy (times)	6.25±1.30	16.76±6.02	<0.001
Surgical cost (¥)	20883.62±3139.73	12566.88±1688.73	0.014

UBE: Unilateral biportal endoscopy; PELD: Percutaneous endoscopic lumbar discectomy; SD: Standard deviation.

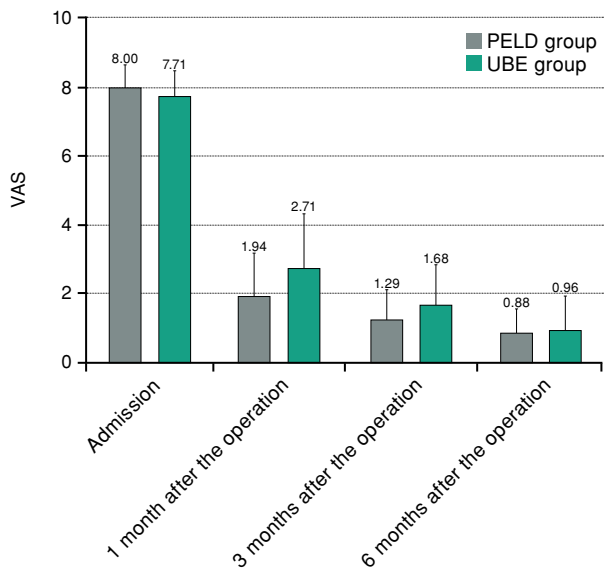

FIGURE 9. The VAS for radicular leg pain preoperatively on admission and at 1-month, 3-month, and 6-month postoperatively. There were no significant differences between the two groups.
VAS: Visual Analog Scale.

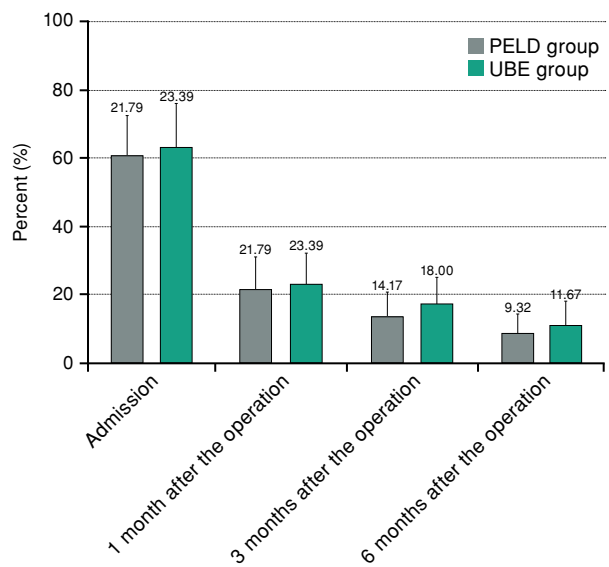

FIGURE 10. The ODI on admission and at 1-month, 3-month,and 6-month postoperatively. There were no significant differences between the two groups.
ODI: Oswestry disability index; PELD: Percutaneous endoscopic lumbar discectomy; UBE: Unilateral biportal endoscopy.

TABLE III
Clinical outcomes

Parameters	UBE group (n=28) n	UBE group (n=28) %	PELD group (n=17) n	PELD group (n=17) %	*p*
Modified MacNab evaluation					
Excellent	19		14		
Good	5		2		
Fair	3		1		
Poor	1		0		
Excellent/good rate		85.71		94.12	0.635

UBE: Unilateral biportal endoscopy; PELD: Percutaneous endoscopic lumbar discectomy.

Complications

In the UBE group, one patient experienced postoperative dorsal root ganglion irritation, presenting as residual numbness and intermittent radiating pain in the lower limb. Symptoms improved to a tolerable level with conservative treatment, and the patient reported functional improvement and reduced discomfort at the six-month follow-up, although mild numbness persisted. In the PELD group, one patient experienced similar ganglion irritation, which improved substantially after three months of conservative medication, with pain relief and partial resolution of numbness, although mild hypoesthesia remained. No cases of dural tear or incision-site infection were reported in either group.

DISCUSSION

In the present study, we compared the clinical outcomes of UBE and PELD for the treatment of FLLDH. Both techniques demonstrated substantial improvements in postoperative pain levels (VAS scores) and functional outcomes (ODI scores), with no statistically significant differences between the groups at one, three, and six months postoperatively. However, the UBE group exhibited significantly lower intraoperative fluoroscopy times, indicating reduced radiation exposure for both patients and healthcare providers.

Far lateral lumbar disc herniation is a distinct type of lumbar disc herniation in which the disc protrudes into or beyond the intervertebral foramen. It can sometimes be missed during diagnosis, and in some cases, patients may experience only mild pain, allowing for conservative management or interventional methods such as injections.[4,18] Although open surgery can achieve effective decompression of the foraminal and extraforaminal regions, it often requires the removal of a substantial portion of the lumbar facet joint and surrounding bone, potentially compromising lumbar stability and necessitating fusion surgery.[19]

In recent years, spinal endoscopic techniques have advanced substantially, and both surgeons and patients have increasingly embraced minimally invasive options.[20] Although previous studies have explored the effectiveness of individual approaches, the question of which surgical technique offers greater advantages remains under discussion.[21-24] Our study contributes to this debate by comparing clinical outcomes, including pain relief and functional recovery, between UBE and PELD in the context of FLLDH.

In the current study, we observed postoperative improvements in VAS and ODI scores for both groups, with no statistically significant difference, consistent with earlier findings.[10,19,20] Park et al.[25] reported favorable outcomes using UBE to treat L5/S1 far lateral disc herniation. Similarly, Li and Zhang[10] assessed both percutaneous transforaminal endoscopic discectomy (PTED) and UBE for the same condition and found substantial postoperative improvements in VAS and ODI scores for both techniques, although no notable difference at the final follow-up. More interestingly, the aforementioned authors found a significantly longer surgery duration in the PTED group (108.0±35.3 min *vs.* 84.3±25.4 min). In contrast, this study revealed no significant difference in surgical time between UBE and PELD, suggesting that further multi-center validation is warranted.

Of note, our study differs from Li and Zhang's[10] in key aspects. We used only local anesthesia, enabling immediate patient feedback and reducing nerve irritation, while Li and Zhang[10] used

combined local and intravenous anesthesia. We also employed a diamond burr for foraminoplasty, offering better visibility and potentially less nerve root stimulation than Li and Zhang trephine. These differences may explain the different results between our study and Li and Zhang's study. Surgical time differences may reflect operator experience.

Meta-analyses have shown that UBE is superior to microendoscopic discectomy (MED) in relieving back pain one day postoperatively, although both procedures appear similar in terms of leg pain relief at one day, long-term outcomes and safety profiles.[26,27] Therefore, further evidence is needed to evaluate the relative efficacy and safety of UBE versus PELD in the treatment of FLLDH.

Operator-dependent variability is a well-known factor in minimally invasive spine surgery due to the steep learning curve. In our study, this potential bias was minimized, as all procedures were performed by a single experienced surgeon, which strengthens the consistency and reliability of the comparative outcomes between UBE and PELD. Both UBE and PELD pose distinct technical challenges and learning curves. Unilateral biportal endoscopy separates the visual and working portals, more closely mimicking open surgery and potentially offering a smoother learning path for spine surgeons transitioning from open techniques.

Liu et al.[28] conducted a meta-analysis exploring the learning curve associated with UBE, revealing that an average of 37.5 cases is needed to achieve surgical proficiency, with a range from 14 to 58 cases. In contrast, PELD presents challenges due to its confined operating portal and reliance on precise trajectory planning under fluoroscopy. Sun et al.[29] found that even surgeons with prior selective nerve root block (SNRB) experience required around 47 cases to master PELD, whereas those without SNRB experience needed up to 56 cases. Notably, the surgeon's experience level substantially influences both the duration of surgery and outcomes, highlighting the importance of repeated practice to optimize surgical performance and minimize intraoperative risks.

During FLLDH surgery, the incision for PELD is located further from the posterior midline of the spine, whereas the incision for UBE is closer. This results in differences in the microscopic field and operative manipulation. The PELD technique first exposes the facet joints and intervertebral foramen area then identifies the herniated intervertebral disc based on the position of the nerve root and foramen. The UBE technique initially exposes the lower edge of the transverse process or the isthmus, followed by exposure of the nerve root.

Between the transverse process and the isthmus, the dorsal branch of the segmental artery runs through this region and requires particular attention during the procedure. Improper handling may lead to microscopic bleeding and prolong the surgical time. It is recommended to first expose this vessel and use electrocautery for pre-hemostasis or to ligate it before nerve root exposure. This vessel may also serve as a useful microscopic anatomical landmark. The study by Kang et al.[30] also identified this vessel as a substantial reference point, aiding in identifying the direction of the facet joint, avoiding excessive damage to the joint capsule and potentially reducing surgical time.

Due to the need for PELD instruments to pass through the endoscopic portal, there are high technical requirements, necessitating specialized surgical tools and endoscopic systems. The UBE technique separates the operating portal, allowing standard open surgical instruments to be used effectively, which may help reduce equipment costs. However, as instruments must repeatedly enter and exit the operating portal and a larger working space than in PELD must be created under the endoscope, UBE may cause more tissue damage than PELD.[31]

There are also notable differences between the two techniques. Percutaneous endoscopic lumbar discectomy requires the placement of a metal operating cannula, and the use of local anesthesia allows monitoring of the patient's nerve root symptoms during cannula placement, helping to avoid serious nerve injury. Ren et al.[32] compared general anesthesia and epidural anesthesia for PELD and recommended that novice surgeons perform PELD under local anesthesia to obtain patient feedback, avoid nerve damage and reduce radiation exposure. Patients under local anesthesia remain awake during the procedure, which may lead to elevated blood pressure due to anxiety, increasing the risk of bleeding under the microscope and complicating the surgical process. Gadjradj et al.[33] reported favorable results using dexmedetomidine during full-endoscopic transforaminal discectomy, though this may require cooperation from the anesthesiologist. For patients with multiple underlying conditions and higher anesthetic risk, local anesthesia for PELD is a

suitable option. However, in patients with severe nerve root pain who cannot maintain the surgical position independently, local anesthesia should be considered with caution or appropriate analgesia and sedation should be administered during the procedure.

In UBE procedures, general anesthesia is typically used, providing a stable surgical environment and allowing anesthesiologists to manage vital signs such as blood pressure, potentially facilitating the operation. However, general anesthesia carries inherent risks and is not exclusive to UBE. Percutaneous endoscopic lumbar discectomy, on the other hand, can be performed under local anesthesia, offering advantages such as real-time patient feedback and reduced anesthetic risk, particularly in high-risk populations. Unilateral biportal endoscopy employs two portals, one for video visualization and the other for operative instruments, providing greater flexibility compared with PELD and a potentially shorter learning curve.[20,21] It is now widely accepted by spinal surgeons. Our findings indicate that, despite the differences in operative and anesthetic techniques between UBE and PELD, there was no significant difference in the length of postoperative hospital stay between the two groups. Therefore, the choice of surgical method can be tailored to the patient's specific condition.

Our radiation count revealed significant disparities between PELD and UBE: The PELD required 16.76 fluoroscopic exposures per level versus 6.25 for UBE ($p<0.05$), indicating a significant reduction in the number of exposures. The study by Merter et al.[34] reached similar conclusions. They investigated radiation exposure in UBE, PELD and MED and found that PELD had the highest radiation exposure among the three surgical methods. This reduction in radiation exposure is particularly important given the increasing concerns regarding the long-term health risks associated with fluoroscopic guidance in spinal surgeries.

The costs associated with hospitalization are a crucial factor that both patients and surgeons must consider carefully. Although PELD typically involves a higher initial equipment investment due to its reliance on advanced endoscopic systems and specialized instruments, UBE is not necessarily more cost-effective. Unilateral biportal endoscopy procedures often require a broader array of surgical tools, including dual working portals, two types of radiofrequency electrocoagulation devices and high-flow irrigation systems, all of which can increase procedural and maintenance costs. Additionally, UBE is usually performed under general anesthesia, which may further elevate overall costs due to anesthesia-related resources and postoperative monitoring. In contrast, PELD is often performed under local anesthesia, potentially reducing anesthetic and recovery costs.

Nevertheless, overall hospitalization cost is not solely determined by equipment use; it also depends on factors such as surgery duration, complication rates, recovery speed and length of hospital stay. Our current findings indicate no significant difference in hospitalization duration between the two groups. As medical technology continues to advance and becomes more widely adopted, it is expected that the cost of these devices and procedures would decrease over time, potentially leading to more cost-effective treatment options in the future.[35]

Nonetheless, the present study has several limitations. First, the study uses a retrospective design with a relatively small sample size. Second, the follow-up duration for both cohorts was limited, which may restrict our ability to assess long-term clinical outcomes such as disease recurrence. Finally, as this study was conducted at a single institution, it underscores the need for further studies across multiple centers to validate these findings and explore their broader clinical implications.

In conclusion, both techniques exhibited a favorable safety profile with minimal complications. Taken together, UBE represents a viable alternative to PELD for the treatment of FLLDH, offering comparable clinical outcomes with reduced radiation exposure. Future research should focus on multi-center, large-scale trials with extended follow-up to further validate these findings.

Data Sharing Statement: The data that support the findings of this study are available from the corresponding author upon reasonable request.

Author Contributions: Material preparation, data collection and analysis were performed: Y.S., D.T., L.C., H.Z.; The first draft of the manuscript was written: Y.S.; The final draft of the manuscript was reviewed: J.J. All authors read and approved the final manuscript. All authors contributed to the study conception and design.

Conflict of Interest: The authors declared no conflicts of interest with respect to the authorship and/or publication of this article.

Funding: The authors received no financial support for the research and/or authorship of this article.

REFERENCES

1. Berra LV, Di Rita A, Longhitano F, Mailland E, Reganati P, Frati A, et al. Far lateral lumbar disc herniation part 1: Imaging, neurophysiology and clinical features. World J Orthop 2021;12:961-9. doi: 10.5312/wjo.v12.i12.961.
2. Lin L, Ke ZY, Chu L, Cheng Y, Zhao GS, Zhong D, et al. Full-endoscopic lumbar discectomy via lateral superior articular process approach for treating far lateral lumbar disc herniation: A retrospective study and technical note. Int Orthop 2023;47:2843-50. doi: 10.1007/s00264-023-05937-0.
3. Greil ME, Ogunlade JI, Bergquist J, Williams JR, Kashlan ON, Hofstetter CP. Full-endoscopic trans-pars interarticularis approach for far lateral lumbar discectomy. Eur Spine J 2023;32:2709-16. doi: 10.1007/s00586-023-07698-1.
4. Serifoglu L, Etli MU. Transforaminal epidural injection for far lateral lumbar disc herniations: An alternative to surgery or just a delay? Cureus 2024;16:e52530. doi: 10.7759/cureus.52530.
5. Connolly J, Borja AJ, Kvint S, Glauser G, Strouz K, McClintock SD, et al. Postoperative outcomes and resource utilization following open vs endoscopic far lateral lumbar discectomy. Int J Spine Surg 2023;17:350-5. doi: 10.14444/8443.
6. Kaya M, Keskin E, Ceylan D, Kacira T, Kitiki Kacira Ö. Surgical treatment of far lateral lumbar disc herniation: Outcomes of the safe and simple midline approach. Cureus 2022;14:e27907. doi: 10.7759/cureus.27907.
7. Jarebi M, Awaf A, Lefranc M, Peltier J. A matched comparison of outcomes between percutaneous endoscopic lumbar discectomy and open lumbar microdiscectomy for the treatment of lumbar disc herniation: A 2-year retrospective cohort study. Spine J 2021;21:114-21. doi: 10.1016/j.spinee.2020.07.005.
8. Liu JW, Li SX, Wang F, Yang Y, Yu H. Hidden blood loss in percutaneous endoscopic lumbar discectomy via the posterolateral approach. Jt Dis Relat Surg 2025;36:56-64. doi: 10.52312/jdrs.2025.2065.
9. Odent JB, Castel X, Vieira TD, Brahim EB, Fière V, d'Astorg H, et al. Beyond traditional surgery for far lateral lumbar herniation: Transforaminal full endoscopic discectomy. Neurochirurgie 2025;71:101620. doi: 10.1016/j.neuchi.2024.101620.
10. Li J, Zhang T. Comparison of clinical outcomes and complications of biportal and uniportal endoscopic decompression for the treatment of cervical spondylotic radiculopathy: A systematic review and meta-analysis. Jt Dis Relat Surg 2024;35:583-93. doi: 10.52312/jdrs.2024.1820.
11. Chun EH, Park HS. A modified approach of Percutaneous Endoscopic Lumbar Discectomy (PELD) for far lateral disc herniation at L5-S1 with foot drop. Korean J Pain 2016;29:57-61. doi: 10.3344/kjp.2016.29.1.57.
12. Wu CY, Huang HM, Lee HC, Tang CH, Chen YH, Chiu CD. Transforaminal unilateral biportal endoscopic spinal surgery for extraforaminal lumbar disc herniation: A retrospective observational study. World Neurosurg 2024;183:e658-67. doi: 10.1016/j.wneu.2023.12.162.
13. Park DK, Weng C, Zakko P, Choi DJ. Unilateral biportal endoscopy for lumbar spinal stenosis and lumbar disc herniation. JBJS Essent Surg Tech 2023;13:e22.00020. doi: 10.2106/JBJS.ST.22.00020.
14. Pan M, Li Q, Li S, Mao H, Meng B, Zhou F, et al. Percutaneous endoscopic lumbar discectomy: Indications and complications. Pain Physician 2020;23:49-56.
15. Qiao X, Yan L, Feng Y, Li X, Zhang K, Lv Z, et al. Efficacy and safety of corticosteroids, hyaluronic acid, and PRP and combination therapy for knee osteoarthritis: A systematic review and network meta-analysis. BMC Musculoskelet Disord 2023;24:926. doi: 10.1186/s12891-023-06925-6.
16. Pennings JS, Devin CJ, Khan I, Bydon M, Asher AL, Archer KR. Prediction of Oswestry Disability Index (ODI) using PROMIS-29 in a national sample of lumbar spine surgery patients. Qual Life Res 2019;28:2839-50. doi: 10.1007/s11136-019-02223-8.
17. Yu L, Dong H, Tan H, Xie X, Liu N, Zhang G, et al. Uniportal full-endoscopic foraminotomy for lumbar foraminal stenosis: Clinical characteristics and functional outcomes. Orthop Surg 2024;16:1861-70. doi: 10.1111/os.14102.
18. Cui H, Ye Y, Liu A. Letter to the editor regarding: "Transforaminal unilateral biportal endoscopic spinal surgery for extraforaminal lumbar disc herniation: A retrospective observational study". World Neurosurg 2024;191:335. doi: 10.1016/j.wneu.2024.07.115.
19. Ahuja S, Moideen AN, Dudhniwala AG, Karatsis E, Papadakis L, Varitis E. Lumbar stability following graded unilateral and bilateral facetectomy: A finite element model study. Clin Biomech (Bristol) 2020;75:105011. doi: 10.1016/j.clinbiomech.2020.105011.
20. Tang K, Goldman S, Avrumova F, Lebl DR. Background, techniques, applications, current trends, and future directions of minimally invasive endoscopic spine surgery: A review of literature. World J Orthop 2023;14:197-206. doi: 10.5312/wjo.v14.i4.197.
21. Van Isseldyk F, Padilla-Lichtenberger F, Guiroy A, Asghar J, Quillo-Olvera J, Quillo-Reséndiz J, et al. Endoscopic treatment of lumbar degenerative disc disease: A narrative review of full-endoscopic and unilateral biportal endoscopic spine surgery. World Neurosurg 2024;188:e93-107. doi: 10.1016/j.wneu.2024.05.047.
22. Leyendecker J, Prasse T, Rückels P, Köster M, Rumswinkel L, Schunk V, et al. Full-endoscopic spine-surgery in the elderly and patients with comorbidities. Sci Rep 2024;14:29188. doi: 10.1038/s41598-024-80235-2.
23. Heo DH, Kim JY, Park JY, Kim JS, Kim HS, Roh J, et al. Clinical experiences of 3-dimensional biportal endoscopic spine surgery for lumbar degenerative disease. Oper Neurosurg 2022;22:231-8. doi: 10.1227/ONS.0000000000000090.
24. Wang Z, Wen J, Ren C, Xue W, Song Y, Liu L. Anterior endoscopy combining with modified total en block spondylectomy for synovial sarcoma in thoracic paraspine causing neurological deficits: Case report and literature review. Orthop Surg 2022;14:2776-81. doi: 10.1111/os.13389.
25. Park JH, Jung JT, Lee SJ. How i do it: L5/S1 foraminal stenosis and far-lateral lumbar disc herniation with unilateral bi-portal endoscopy. Acta Neurochir (Wien) 2018;160:1899-903. doi: 10.1007/s00701-018-3630-9.
26. Zheng B, Xu S, Guo C, Jin L, Liu C, Liu H. Efficacy and safety of unilateral biportal endoscopy versus other spine surgery: A systematic review and meta-analysis. Front Surg 2022;9:911914. doi: 10.3389/fsurg.2022.911914.
27. Ma X, Li W, Gao S, Cao C, Li C, He L, et al. Comparison of unilateral biportal endoscopic discectomy versus percutaneous endoscopic lumbar discectomy for the treatment of lumbar disc herniation: A systematic review and meta-analysis. Medicine (Baltimore) 2022;101:e30412. doi: 10.1097/MD.0000000000030612.

28. Liu SX, Chen RS, Chen CM, He LR, Jhang SW, Lin GX. Unilateral biportal endoscopic spine surgery: A meta-analysis unveiling the learning curve and clinical benefits. Front Surg 2024;11:1405519. doi: 10.3389/fsurg.2024.1405519.
29. Sun B, Wu H, Xu Z, Lu J, Wang Y, Zhang K, et al. Is selective nerve root block necessary for learning percutaneous endoscopic lumbar discectomy: A comparative study using a cumulative summation test for learning curve. Int Orthop 2020;44:1367-74. doi: 10.1007/s00264-020-04558-1.
30. Kang MS, Hwang JY, Park SM, Yang JH, You KH, Hong SH, et al. Comparison of biportal endoscopic and microscopic tubular paraspinal approach for foraminal and extraforaminal lumbar disc herniation. J Neurosurg Spine 2024;41:473-82. doi: 10.3171/2024.4.SPINE23707.
31. Qian J, Lv X, Luo Y, Liu Y, Jiang W. Unilateral biportal endoscopic discectomy versus percutaneous endoscopic lumbar discectomy in the treatment of lumbar disc herniation linked with posterior ring apophysis separation: A retrospective study. World Neurosurg 2025;193:957-63. doi: 10.1016/j.wneu.2024.09.102.
32. Ren Z, He S, Li J, Wang Y, Lai J, Sun Z, et al. Comparison of the safety and effectiveness of percutaneous endoscopic lumbar discectomy for treating lumbar disc herniation under epidural anesthesia and general anesthesia. Neurospine 2020;17:254-9. doi: 10.14245/ns.1938366.183.
33. Gadjradj PS, Arjun Sharma JRJ, Harhangi BS. Quality of conscious sedation using dexmedetomidine during full-endoscopic transforaminal discectomy for sciatica: A prospective case series. Acta Neurochir (Wien) 2022;164:1209-16. doi: 10.1007/s00701-021-05100-x.
34. Merter A, Karaeminogullari O, Shibayama M. Comparison of radiation exposure among 3 different endoscopic diskectomy techniques for lumbar disk herniation. World Neurosurg 2020;139:e572-9. doi: 10.1016/j.wneu.2020.04.079.
35. Gu N, Zhang J, Liu A. Letter to the editor regarding "Comparative study between unilateral biportal endoscopic discectomy and percutaneous interlaminar endoscopic discectomy for the treatment of L5/S1 disc herniation". World Neurosurg 2025;195:123650. doi: 10.1016/j.wneu.2024.123650.