



# Rare coexistence of X-linked hyper immunoglobulin M syndrome and polyarticular juvenile idiopathic arthritis in a Chinese child: A case report

Jing-Wei Li, MD\*<sup>ORCID</sup>, Xue Xie, MD\*<sup>ORCID</sup>, Xin-Yi Wei, MD<sup>ORCID</sup>, Wei Zhang, PhD<sup>ORCID</sup>

Pediatric Immunology and Rheumatology Department, School of Medicine, Chengdu Women's and Children's Central Hospital, University of Electronic Science and Technology of China, Chengdu, China

Juvenile idiopathic arthritis (JIA) is one of the most common autoimmune diseases in children, with an estimated incidence of 1 to 4 per 1,000. It is characterized by persistent joint inflammation, leading to pain, swelling, and stiffness.<sup>[1,2]</sup> Juvenile idiopathic arthritis is classified into several subtypes, including oligoarticular, polyarticular and systemic forms. Among these, rheumatoid factor (RF)-negative polyarticular JIA (PJIA) accounts for approximately 15 to 20% of all cases. This subtype typically affects five or more joints and is distinguished by the absence of RF, often presenting with various systemic symptoms. The underlying mechanisms involve a complex interplay of genetic predisposition, environmental triggers

## ABSTRACT

Immune dysregulation in children can lead to a variety of health issues, including infections, allergies and autoimmune diseases. However, the coexistence of autoimmune diseases and primary immunodeficiency disorders is extremely rare in clinical practice. A 4-year-old male patient was admitted in July 2017 with joint swelling and pain, alongside a history of recurrent respiratory infections and severe pneumonia. Physical examination revealed tenderness and swelling in multiple joints, and laboratory tests indicated elevated inflammatory markers. Imaging studies showed joint effusion and inflammatory lesions in the lungs. He was diagnosed with rheumatoid factor-negative polyarticular juvenile idiopathic arthritis (PJIA) and treatment was initiated with naproxen, methotrexate and etanercept, leading to significant symptom improvement. In July 2019, following a decline in immunoglobulin (Ig) M levels (IgM 0.36 g/L) and recurrent infections, genetic testing was conducted, revealing a frameshift mutation in the *CD40LG* gene (c.621dup A, p.A208Sfs \* 23), which confirmed the diagnosis of X-linked hyper IgM syndrome (XHIGM). The treatment regimen was adjusted to include monthly intravenous Ig infusions and prophylactic antibiotics, significantly reducing the frequency of respiratory infections. By January 2021, PJIA was in clinical remission, allowing for the discontinuation of immunosuppressive therapy, with follow-ups indicating continued recovery without discomfort. In conclusion, this case underscores the rare coexistence of XHIGM and PJIA in the field of pediatrics and identified a new pathogenic variant in *CD40LG*, enhancing our understanding of the clinical management of individuals with concurrent autoimmune and immunodeficiency disorders.

**Keywords:** *CD40LG*, genetic testing, juvenile idiopathic arthritis, X-linked hyper immunoglobulin M syndrome.

Received: September 24, 2024

Accepted: November 24, 2024

Published online: June 13, 2025

**Correspondence:** Wei Zhang, PhD. Pediatric Immunology and Rheumatology Department, School of Medicine, Chengdu Women's and Children's Central Hospital, University of Electronic Science and Technology of China, Chengdu 611731, China.

E-mail: gczhangwei@uestc.edu.cn

DOI: 10.52312/jdrs.2025.1988

\* These authors contributed equally to this work as co-first authors.

**Citation:** Li JW, Xie X, Wei XY, Zhang W. Rare coexistence of X-linked hyper immunoglobulin M syndrome and polyarticular juvenile idiopathic arthritis in a Chinese child: A case report. *Jt Dis Relat Surg* 2025;36(3):751-756. doi: 10.52312/jdrs.2025.1988.

©2025 All right reserved by the Turkish Joint Diseases Foundation

This is an open access article under the terms of the Creative Commons Attribution-NonCommercial License, which permits use, distribution and reproduction in any medium, provided the original work is properly cited and is not used for commercial purposes (<http://creativecommons.org/licenses/by-nc/4.0/>).

and immune system dysregulation.<sup>[3,4]</sup> Untreated JIA can lead to significant joint damage and long-term disability, severely impacting a child's quality of life. Early diagnosis and effective management are crucial for improving prognosis and minimizing complications.

Conversely, X-linked hyper immunoglobulin M syndrome (XHIGM) is a rare primary immunodeficiency disorder caused by mutations in the *CD40LG* gene. This condition results in elevated levels of immunoglobulin (Ig) M and impaired production of other antibody classes, leading to ineffective immune responses.<sup>[5]</sup> Clinically, XHIGM typically manifests in early childhood, with >50% of male patients showing symptoms by age one year and >90% by age four years. Patients frequently experience recurrent bacterial infections, including respiratory tract infections and opportunistic infections, such as *Pneumocystis jirovecii* pneumonia, as well as chronic diarrhea, which can lead to growth retardation.<sup>[6,7]</sup>

Rheumatoid factor-negative PJIA is characterized by autoreactive antigen-specific T cells and high titers of autoantibodies, while Ig levels are usually normal. The coexistence of PJIA and XHIGM is rare, but highlights the complexities of immune dysregulation. In this article, we report details the clinical characteristics of a case diagnosed with both conditions, successfully treated at our hospital, to enhance our understanding of rheumatic immune diseases amid concurrent immunodeficiency.

## CASE REPORT

In July 2017, a four-year-old male patient was hospitalized due to joint swelling and pain persisting for two months. His medical history included over seven respiratory infections annually and severe pneumonia once a year. The family history noted the death of an older brother from severe pneumonia and respiratory failure. Upon admission, the physical examination revealed tenderness in the bilateral wrist and hip joints, swelling in both knees, increased local skin temperature, mild activity limitations, a positive bilateral four-character sign and suspected tenderness in the lumbosacral region.

Within 24 h of admission, a complete blood count showed a white blood cell count of  $8.26 \times 10^9/L$ , with 26% neutrophils and 56.6% lymphocytes. The red blood cell count was  $4.2 \times 10^{12}/L$ , the hemoglobin level was 115 g/L and the platelet count was  $372 \times 10^9/L$ . C-reactive protein (CRP) was elevated at 17.3 mg/L. Other biochemical tests, including liver and kidney function, myocardial enzyme levels, erythrocyte sedimentation rate (ESR), procalcitonin and routine urine and stool analyses, were normal. Infectious disease screenings, including nucleic acid tests for respiratory pathogens, tuberculosis tests and serologies for hepatitis viruses, syphilis and human

immunodeficiency virus (HIV), were negative, as were blood cultures for bacteria and fungi.

Humoral and cellular immunity tests showed no abnormalities. The anti-nuclear antibody spectrum, anti-cyclic citrullinated peptide (anti-CCP), RA433, anti-keratin antibody (AKA), human leukocyte antigen-B27 (HLA-B27), anti-O and RF tests were all negative. A bone marrow smear revealed active hyperplasia, with 37% granulocytes and visible eosinophils.

Joint ultrasound indicated effusion in the right hip joint (0.4 cm) and synovial thickening, while the left hip joint was normal. Both knee joints showed effusion (0.4 cm) and synovial thickening, and the bilateral wrist joints exhibited effusion without thickening. Plain radiographs of the knee joints showed no bone abnormalities. A computed tomography scan of the abdomen and pelvis revealed multiple mildly enlarged mesenteric lymph nodes and inflammatory lesions in the lower lobe of the left lung.

The timeline of the patient's diagnosis and treatment process is shown in Figure 1. Following a thorough evaluation, the patient was diagnosed with RF-negative PJIA. Treatment was initiated with naproxen (0.25 mg, t.i.d.) for inflammation, total glucosides of paeony (0.6 g, t.i.d.) for immune regulation and cefdinir (100 mg, t.i.d.) for infection prophylaxis. On July 10<sup>th</sup>, 2017, oral methotrexate was initiated at 5 mg weekly with folic acid supplementation 24 h after each dose. Due to persistent swelling and pain in both knees, the methotrexate dosage was increased to 7.5 mg weekly on July 24<sup>th</sup>, 2017.

Between August 2017 and April 2018, the patient experienced intermittent joint swelling and pain. The medical team recommended starting subcutaneous etanercept, which led to a gradual improvement in symptoms. In February 2018, the patient experienced a recurrence of knee symptoms with elevated inflammatory markers (CRP: 31 mg/L, ESR: 30 mm/h), but without local redness or increased skin temperature. Although alternatives to etanercept were suggested, the parents opted to continue with it due to financial constraints. Prednisone was added later that month at 15 mg daily to manage joint symptoms. As the patient's symptoms improved, the prednisone dosage was gradually reduced and was ultimately discontinued in August 2018. Thereafter, the patient showed no joint swelling or pain, and inflammatory markers returned to normal.

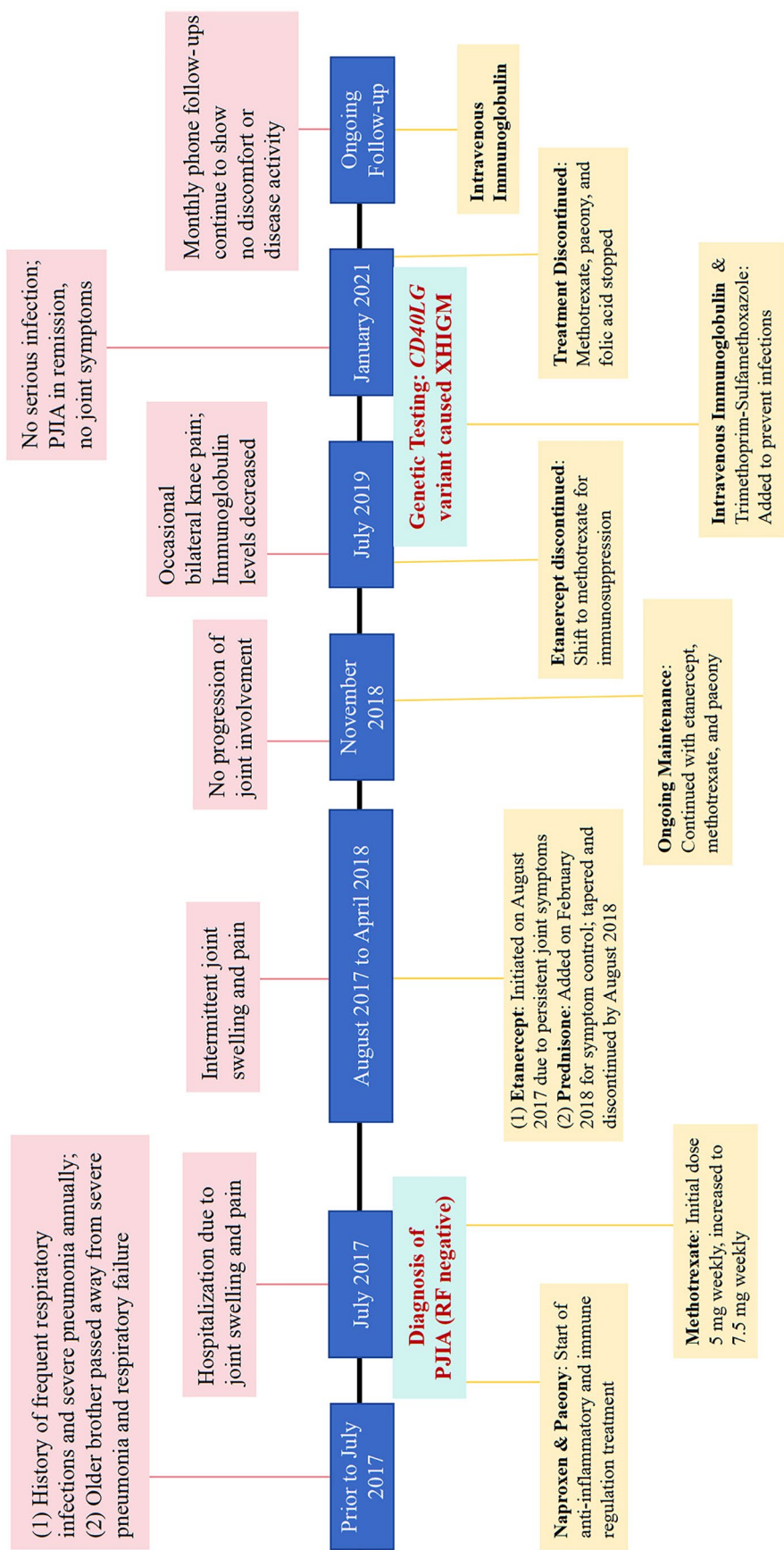
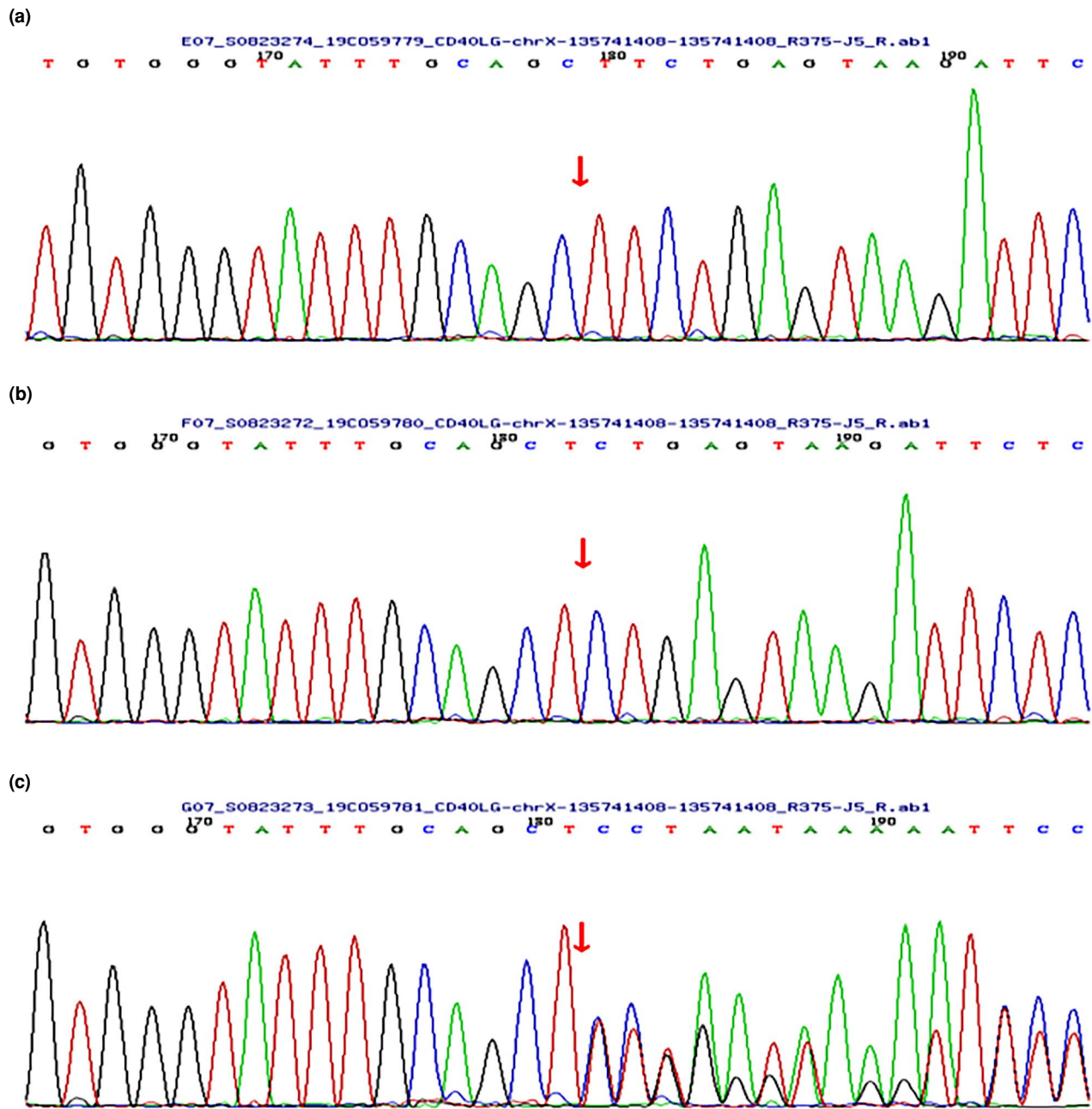


FIGURE 1. Timeline of the patient's diagnosis and treatment process.

In November 2018, a pelvic magnetic resonance imaging scan revealed fluid in the right hip joint and slight synovial thickening, along with patchy abnormal signals around both femoral heads and acetabula, indicating inflammatory disease. However, there was no progression of joint involvement, confirming treatment effectiveness. The ongoing treatment plan included subcutaneous etanercept, oral methotrexate for immune suppression, folic acid supplementation, and total glucosides of paeony for immune regulation.

In July 2019, the patient discontinued etanercept and continued with methotrexate for immunosuppression. Although occasional bilateral knee pain was reported, there was no significant discomfort. During hospitalization, Ig levels decreased, with the lowest values recorded at IgG 0.78 g/L, IgA 0.27 g/L and IgM 0.36 g/L, while B cell counts remained normal.

Given the patient's history of recurrent respiratory infections and a family history of



**FIGURE 2.** Genetic testing results for the proband (a) and his parents (b) father, (c) mother.



a sibling who died from a severe infection, an informed consent was obtained for genetic testing. In September 2019, a primary immunodeficiency gene panel was conducted by MyGenostics Technology Co., Ltd. (Beijing, China), covering 350 genes associated with immune disorders ([see Supplementary Materials for details](#)). The average coverage exceeded 97% at a depth of 20X or greater. Genetic testing revealed a frameshift mutation in *CD40LG* exon 5 (c.621dup A, p.A208Sfs \* 23), confirmed by Sanger sequencing. Family analysis indicated that the patient's mother was a carrier of this variant, while the father was not (Figure 2). This variant has not been reported in the literature, and according to the 2015 American College of Medical Genetics and Genomics (ACMG) standards and guidelines,<sup>[8]</sup> it was classified as likely pathogenic based on PVS1 criteria (indicating potential loss of gene function) and PM2 (indicating low-frequency variation).

Consequently, the patient was diagnosed with RF-negative PJIA and XHIGM. Monthly infusions of intravenous Ig (400 to 600 mg/kg) were initiated, along with oral trimethoprim-sulfamethoxazole, to prevent bacterial and *Pneumocystis carinii* infections. The treatment significantly reduced the frequency of respiratory infections, and no serious infections or relapses of arthritis symptoms occurred. In April 2020, a joint color Doppler ultrasound revealed a small amount of effusion in both knee joints, with no synovial thickening or abnormalities in the hip and wrist joints. By January 2021, PJIA was considered to be in clinical remission, leading to the discontinuation of methotrexate, total glucosides of paeony and folic acid tablets. Monthly telephone follow-ups to date have indicated continued recovery without any discomfort. A written informed consent was obtained from the parent of the patient.

## DISCUSSION

The coexistence of autoimmune disease and primary immunodeficiency disorder, X-linked hyper IgM syndrome (XHIGM) and PJIA, presents a unique and significant clinical challenge.<sup>[8]</sup> This case report details the experience of a four-year-old male diagnosed with both PJIA and XHIGM, illustrating the complexities of immune dysregulation and the necessity for meticulous management in pediatric patients.

Juvenile idiopathic arthritis is one of the most prevalent autoimmune disorders in children, typically characterized by persistent joint inflammation. Rheumatoid factor-negative

PJIA, a subtype affecting five or more joints, is particularly notable for its association with autoantibody production and overall immune system dysregulation. In this case, the patient exhibited significant joint swelling, pain and recurrent respiratory infections—common features of PJIA. Early intervention with non-steroidal anti-inflammatory drugs, disease-modifying anti-rheumatic drugs and biological agents effectively managed his arthritis symptoms. Through comprehensive management, he achieved clinical remission, underscoring the critical importance of early and effective treatment to prevent long-term joint damage and disability.<sup>[1-3]</sup>

Conversely, XHIGM is a rare primary immunodeficiency disorder caused by mutations in the *CD40LG* gene. According to the Human Gene Mutation Database (HGMD<sup>®</sup>), over 200 mutations in the *CD40LG* gene have been reported to date, with missense/nonsense mutations, small deletions, splicing mutations and small insertions being the most common. This condition disrupts the normal Ig class-switching process, resulting in elevated IgM levels while reducing the production of other antibody classes. Clinically, XHIGM presents with recurrent bacterial infections and various immune-related complications.<sup>[6,9]</sup> In this case, the patient's history of recurrent respiratory infections and notably low Ig levels prompted genetic testing, which ultimately revealed a frameshift mutation in the *CD40LG* gene that has not been previously reported in the literature. This significant finding not only expands the mutation spectrum of the *CD40LG* gene and confirms the diagnosis of XHIGM, but also provides valuable insight into the patient's immune dysregulation, further complicating his autoimmune condition.

While previous literature has documented cases of JIA in conjunction with X-linked agammaglobulinemia,<sup>[10,11]</sup> reports specifically addressing PJIA coexisting with XHIGM are exceedingly rare. This article focuses on this unique situation, emphasizing the intricate interplay between PJIA and XHIGM in our patient, highlighting the complexities involved in managing coexisting immune disorders. The standard management of PJIA often includes immunosuppressive therapies, which could potentially exacerbate the immunodeficiency associated with XHIGM. Consequently, careful consideration of the treatment regimen becomes essential. After confirming the diagnosis of XHIGM, the treatment plan was modified to include

monthly intravenous Ig infusions and prophylactic antibiotics. This adjustment significantly reduced the frequency of respiratory infections and enabled the patient to manage his arthritis symptoms better. The rarity of this case draws attention to the urgent need for heightened awareness among clinicians regarding the possibility of concurrent autoimmune and immunodeficiency disorders. Given the overlapping symptoms, such as joint pain and recurrent infections, distinguishing between these conditions can be particularly challenging. This case also exemplifies the necessity for thorough immunological assessments in children presenting with autoimmune symptoms, particularly when there is a background of recurrent infections.<sup>[12]</sup>

In conclusion, the coexistence of XHIGM and PJIA in this pediatric patient presents a rare and intricate clinical scenario. This case underscores the importance of early diagnosis, genetic testing and a tailored treatment approach to manage the dual challenges posed by autoimmune and immunodeficiency disorders effectively. However, it is essential to acknowledge the limitations of this report, including the single-case nature of the study, which may not fully represent the broader population of patients with similar coexisting conditions. Future research should aim to expand our understanding of the mechanisms underlying these complex interactions and explore more extensive case series, which may ultimately lead to improved outcomes for children affected by similar conditions. By recognizing and addressing these rare co-occurrences, healthcare providers can enhance the quality of care and the overall quality of life for affected children.

**Data Sharing Statement:** The data that support the findings of this study are available from the corresponding author upon reasonable request.

**Author Contributions:** Idea/concept, critical review: J.W.L., W.Z.; Design: J.W.L., X.X., X.W.; Control/supervision: W.Z.; Data collection and/or processing, materials, analysis and/or interpretation: J.W.L., X.X.; Literature review: J.W.L., X.W.; Writing the article: J.W.L.

**Conflict of Interest:** The authors declared no conflicts of interest with respect to the authorship and/or publication of this article.

**Funding:** The authors received no financial support for the research and/or authorship of this article.

## REFERENCES

1. Bansal N, Pasricha C, Kumari P, Jangra S, Kaur R, Singh R. A comprehensive overview of juvenile idiopathic arthritis: From pathophysiology to management. *Autoimmun Rev* 2023;22:103337. doi: 10.1016/j.autrev.2023.103337.
2. Prakken B, Albani S, Martini A. Juvenile idiopathic arthritis. *Lancet* 2011;377:2138-49. doi: 10.1016/S0140-6736(11)60244-4.
3. Ambler WG, Nanda K, Onel KB, Shenoi S. Refractory systemic onset juvenile idiopathic arthritis: Current challenges and future perspectives. *Ann Med* 2022;54:1839-50. doi: 10.1080/07853890.2022.2095431.
4. Twilt M, Stoustrup P, Rumsey D. Challenges in treating juvenile idiopathic arthritis. *Curr Opin Rheumatol* 2023;35:293-7. doi: 10.1097/BOR.0000000000000950.
5. Leite LFB, Máximo TA, Mosca T, Forte WCN. CD40 ligand deficiency. *Allergol Immunopathol (Madr)* 2020;48:409-13. doi: 10.1016/j.aller.2019.08.005.
6. Yazdani R, Fekrvand S, Shahkarami S, Azizi G, Moazzami B, Abolhassani H, et al. The hyper IgM syndromes: Epidemiology, pathogenesis, clinical manifestations, diagnosis and management. *Clin Immunol* 2019;198:19-30. doi: 10.1016/j.clim.2018.11.007.
7. Qamar N, Fuleihan RL. The hyper IgM syndromes. *Clin Rev Allergy Immunol* 2014;46:120-30. doi: 10.1007/s12016-013-8378-7.
8. Atik OŞ. Writing for Joint Diseases and Related Surgery (JDRS): There is something new and interesting in this article! *Jt Dis Relat Surg* 2023;34:533. doi: 10.52312/jdrs.2023.57916.
9. Richards S, Aziz N, Bale S, Bick D, Das S, Gastier-Foster J, et al. Standards and guidelines for the interpretation of sequence variants: A joint consensus recommendation of the American College of Medical Genetics and Genomics and the Association for Molecular Pathology. *Genet Med* 2015;17:405-24. doi: 10.1038/gim.2015.30.
10. de la Morena MT. Clinical phenotypes of Hyper-IgM syndromes. *J Allergy Clin Immunol Pract* 2016;4:1023-36. doi: 10.1016/j.jaip.2016.09.013.
11. Zhu Z, Kang Y, Lin Z, Huang Y, Lv H, Li Y. X-linked agammaglobulinemia combined with juvenile idiopathic arthritis and invasive *Klebsiella pneumoniae* polyarticular septic arthritis. *Clin Rheumatol* 2015;34:397-401. doi: 10.1007/s10067-014-2537-y.
12. Patiroglu T, Akar HH, Gunduz Z, Sisko S, Ng YY. X-linked agammaglobulinemia in two siblings with a novel mutation in the BTK gene who presented with polyarticular juvenile idiopathic arthritis. *Scand J Rheumatol* 2015;44:168-70. doi: 10.3109/03009742.2014.995699.