



## The silent threat under the nail: Evaluation of Seymour fractures in pediatric patients

Ahmet Yiğitbay, MD<sup>1</sup>, Gökhan Yıldırım, MD<sup>1</sup>, Muhammed Can Ari, MD<sup>2</sup>,  
Hakan Çetin, MD<sup>3</sup>, Cemal Kural, MD<sup>4</sup>

<sup>1</sup>Department of Orthopedics and Traumatology, Siverek State Hospital, Şanlıurfa, Türkiye

<sup>2</sup>Department of Orthopedics and Traumatology, Çermik State Hospital, Diyarbakır, Türkiye

<sup>3</sup>Department of Orthopedics and Traumatology, Private Diyarlife Hospital, Diyarbakır, Türkiye

<sup>4</sup>Department of Orthopedics and Traumatology, Bakırköy Dr. Sadi Konuk Training and Research Hospital, İstanbul, Türkiye

Seymour fractures are distal phalanx fractures accompanied by nail bed disruption with a juxta-epiphyseal or Salter-Harris I/II fracture pattern in children.<sup>[1,2]</sup> It is a rare, but clinically significant injury in pediatric orthopedics. These fractures can lead to severe orthopedic complications if remained undiagnosed promptly and accurately, as they affect the growth plate, particularly in growing children. Differentiating Seymour fractures in the diagnostic process is crucial, as clinical findings are often confused with a simple nail bed injury. Early intervention and appropriate antibiotic therapy are critical in treating these fractures to prevent infection.<sup>[2]</sup>

Although Seymour<sup>[1]</sup> first described this fracture pattern in 1966, there are still various opinions regarding its precise definition. Its incidence is not

Received: November 17, 2024

Accepted: January 30, 2025

Published online: April 05, 2025

**Correspondence:** Ahmet Yiğitbay, MD. Siverek Devlet Hastanesi, Ortopedi ve Travmatoloji Kliniği, 63600 Siverek, Şanlıurfa, Türkiye.

E-mail: ahmetyigitbay@gmail.com

Doi: 10.52312/jdrs.2025.2066

**Citation:** Yiğitbay A, Yıldırım G, Ari MC, Çetin H, Kural C. The silent threat under the nail: Evaluation of Seymour fractures in pediatric patients. Jt Dis Relat Surg 2025;36(2):320-327. doi: 10.52312/jdrs.2025.2066.

©2025 All right reserved by the Turkish Joint Diseases Foundation

This is an open access article under the terms of the Creative Commons Attribution-NonCommercial License, which permits use, distribution and reproduction in any medium, provided the original work is properly cited and is not used for commercial purposes (<http://creativecommons.org/licenses/by-nc/4.0/>).

### ABSTRACT

**Objectives:** This study aims to examine the diagnosis, treatment methods, and outcomes of Seymour fractures and to address diagnostic challenges in these fractures.

**Patients and methods:** Between January 2020 and November 2023, a total of 28 pediatric patients (18 males, 11 females; mean age: 6.8±4.5 years; range, 1 to 15 years) who presented with Seymour fractures within 24 h of injury were retrospectively analyzed. Patients were treated either conservatively in the emergency department or surgically in the operating room if closed reduction was unsuccessful. All patients received intravenous antibiotics within the first 24 h, followed by oral antibiotics after discharge. Infection rates, physeal arrest, and nail dystrophy were evaluated during follow-up.

**Results:** The mean follow-up was 16.6±6.6 (range, 12 to 32) months. There was no statistically significant difference in the affected side (right/left) and fingers ( $p=0.43$  and  $p>0.05$ , respectively). The complication rate was significantly higher in surgically treated patients compared to those treated conservatively ( $p=0.02$  and  $p<0.05$ , respectively). Evaluation of patients based on finger mobility showed no motion loss in the conservatively treated group at the final follow-up. In the surgically treated group, however, motion restrictions were noted in only two patients. Early antibiotic administration within 24 h significantly reduced infection rates, with only 3.5% ( $n=1$ ) of patients developing osteomyelitis.

**Conclusion:** Stable Seymour fractures can be treated conservatively in the emergency setting, while complex cases may require surgical intervention in the operating room. Early antibiotic use is essential in minimizing infection risk. Antibiotherapy within the first 24 h after injury is an effective way to prevent infection.

**Keywords:** Antibiotic therapy, emergency department, fracture management, pediatric orthopedics, Seymour fractures.

fully known, with direct trauma or crush injuries being the most common injury mechanisms.<sup>[3]</sup> As with phalanx fractures in children, the third finger is the most frequently affected.<sup>[3]</sup> In the distal phalanx, the extensor pollicis longus tendon

attaches dorsally to the epiphyseal part of the finger. In contrast, the flexor digitorum profundus tendon attaches palmarly to the metaphyseal part of the finger. Due to this difference in tendon attachment sites, the injury results in a pseudo-mallet appearance in the finger. However, there is no tendon pathology in Seymour fractures<sup>[4]</sup> A lateral finger X-ray is essential for diagnosis, as with all finger injuries.

Treatment options include conservative and surgical methods. Although there is no consensus on treatment protocols, antibiotic therapy and open fracture treatment principles have become popular treatment methods recently.<sup>[5-7]</sup> If these fractures are not treated properly, they can lead to functional loss in the hand, osteomyelitis, physeal arrest, and consequent deformity in the finger.

In the present study, we aimed to examine the diagnosis, treatment methods, and outcomes of Seymour fractures in the light of current approaches and to address diagnostic challenges in these fractures.

## PATIENTS AND METHODS

This single-center, retrospective study was conducted at Siverek State Hospital, Department of Orthopedics and Traumatology between January 2022 and November 2023. Inclusion criteria were as follows: age under 18 years, presenting to the emergency department within 24 h of injury, and having a distal phalanx physeal injury accompanied by nail bed disruption. Exclusion criteria were as follows: Patients with a history of trauma to the same finger and those with a closed physis were excluded from the study. Finally, a total of 28 patients (18 males, 11 females; mean age:  $6.8 \pm 4.5$  years; range, 1 to 15 years) who met the inclusion criteria were recruited. A written informed consent was obtained from each parent and/or legal guardians of the patient. The study protocol was approved by the Harran University Clinical Research Ethics Committee (date: 09.09.2024, no: 42). The study was conducted in accordance with the principles of the Declaration of Helsinki.

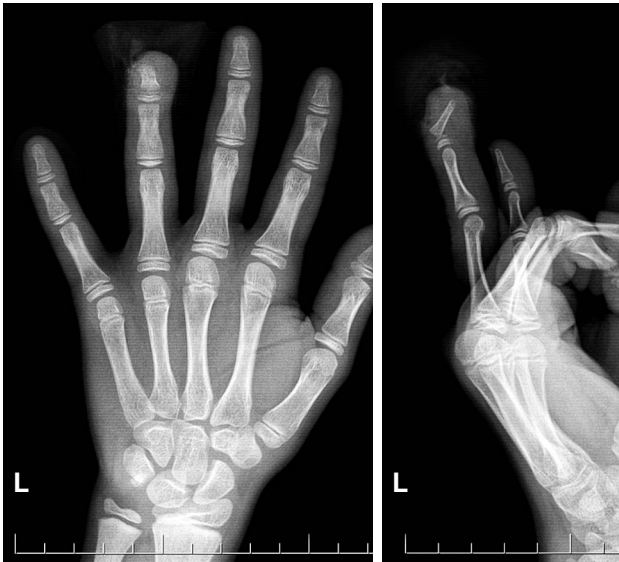
Upon initial presentation to the emergency department, the nail bed of all patients was washed with physiological saline. Cefazolin at a dose of 25 mg/kg was administered intravenously according to the patient's body weight, and intravenous antibiotic therapy was continued for 24 h postoperatively. Surgical treatment was planned for fractures which could not be reduced in a closed

manner. All surgical treatments were performed within the first 8 h by the same surgical team. Patients underwent surgery under sedation and digital block, and a 21-gauge (21G) needle was used for reduction. Nail bed injuries were repaired with 3/0 Prolene sutures. All patients were discharged within 24 h. Following discharge, all patients were prescribed oral amoxicillin + clavulanate and paracetamol at an appropriate dose according to their body weight for two weeks. Patients were called for weekly follow-up for one month, with evaluation using anteroposterior and lateral X-rays of the finger. Sutures were removed at the end of the second week. The finger splint was removed at the end of four weeks in conservatively followed patients, while the needle was removed at the end of four weeks in surgically treated patients. Patients were, then, called for follow-up at specific intervals. No physical therapy protocol was applied to any patient.

Patient data such as sex, age, fracture side, affected finger, fracture type, treatment type, and complications were recorded. All patients were followed for at least one year after trauma. The initial X-rays taken at the presentation were reviewed, and fractures were classified as Salter-Harris types 1 and 2. Patients treated with closed reduction, nail bed revision, and finger splint under local anesthesia in the emergency department were recorded as conservatively treated, while those treated with reduction using a 21G needle in the operating room were recorded as surgically treated. In the first three weeks after treatment, patients with erythema and discharge from the finger were considered to have superficial infections, while those with deeper involvement and bone involvement were considered to have positive deep infections. Patients with ongoing infections at the end of six weeks were considered to have osteomyelitis. At the end of the first year, patients with nail bed deformities were considered to have nail dystrophy. Patients with growth plate arrest detected in the final X-ray were evaluated as having physeal arrest. Two experienced orthopedic surgeons performed physeal arrest assessment. In addition, at the final follow-up, the range of motion of the patient's distal interphalangeal joints was compared with the same finger on the other hand, and any potential motion restriction was recorded.

### Statistical analysis

Statistical analysis was performed using the NCSS version 2020 software (NCSS LLC, Kaysville, UT, USA). Descriptive data were expressed in mean

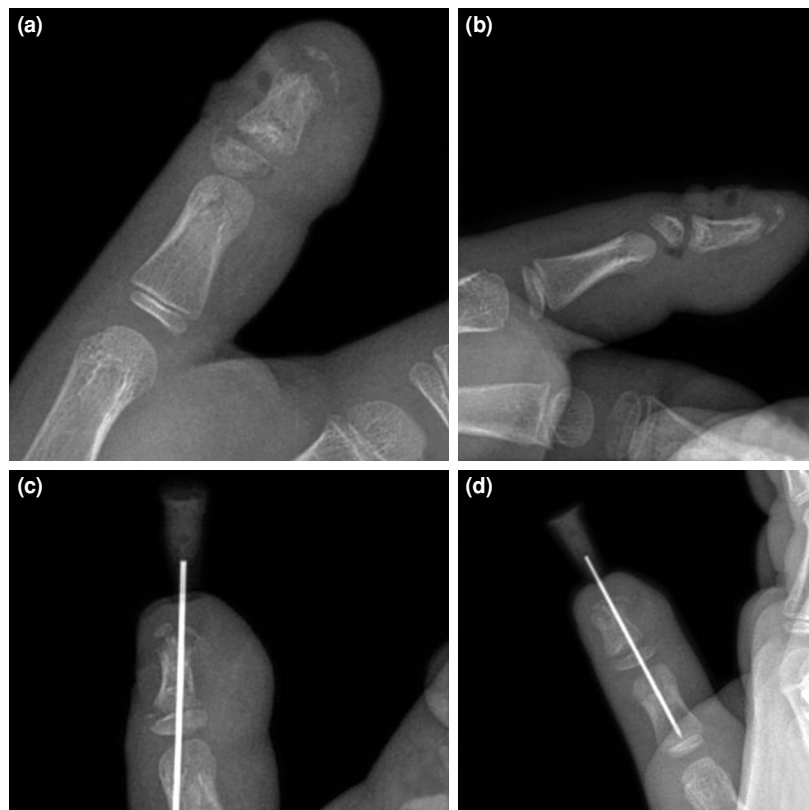


**FIGURE 1.** Anteroposterior and lateral X-rays of a 12-year-old patient with a Seymour injury to the 4<sup>th</sup> finger of the left hand.

± standard deviation (SD), median (min-max) or number and frequency, where applicable. The conformity of the quantitative data to the normal distribution was tested with the Shapiro-Wilk test and graphical examinations. The Student t-test was used for comparisons between two groups of normally distributed quantitative variables, and the Mann-Whitney U test was used for comparisons between two groups of non-normally distributed quantitative variables. The Pearson chi-square test, Fisher exact test, and Fisher-Freeman-Halton test were used to compare qualitative data. A  $p$  value of  $<0.05$  was considered statistically significant.

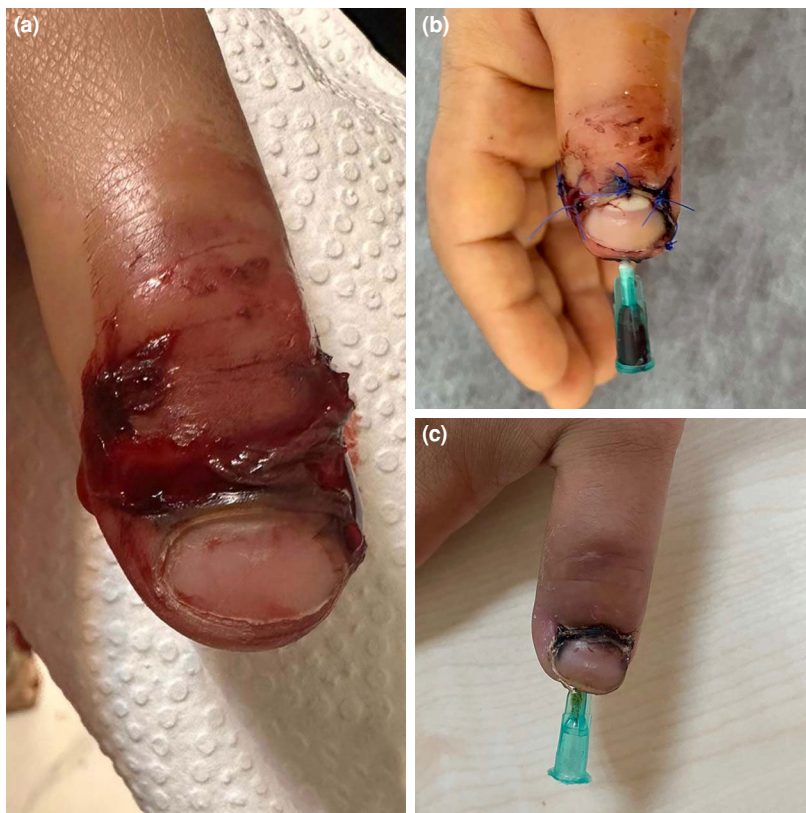## RESULTS

No statistically significant difference was observed between males and females ( $p=0.96$  and  $p>0.05$ , respectively). The mean follow-up was  $16.6\pm 6.6$  (range, 12 to 32) months.



**FIGURE 2.** Radiological images of a seven-year-old patient who underwent surgery for a Seymour injury to the 1<sup>st</sup> finger of the right hand, (a, b) Preoperative AP and lateral X-rays of the finger, (c, d) postoperative AP and lateral X-rays of the finger.

AP: Anteroposterior.



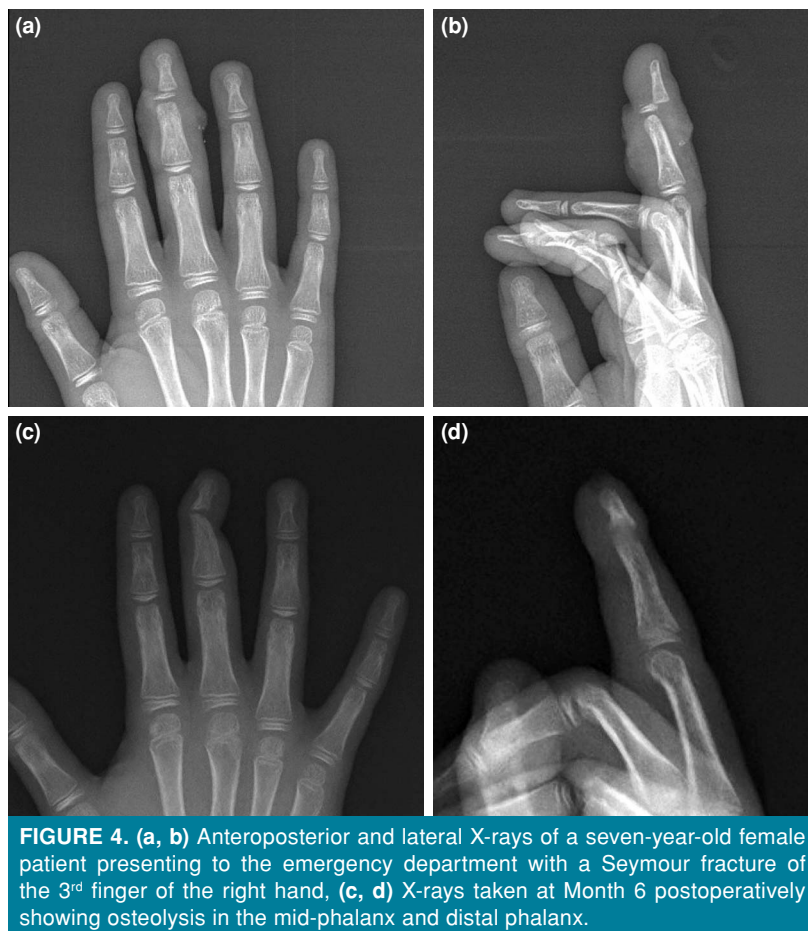**FIGURE 3.** (a) Image of a patient presenting with a Seymour fracture of the 1<sup>st</sup> finger of the left hand caused by a door-trapping injury, (b) Image at Week 1 postoperatively, (c) Image at Month 1 postoperatively.

The patients were evaluated in terms of the affected extremity side, and 11 (39.3%) patients had their right side affected, while 17 (59.7%) patients had their left side affected. Examination of the affected fingers revealed that the thumb was affected in 11 (39.3%) patients, the middle finger in nine (32.1%) patients, the little finger in three (10.7%) patients, the ring finger in three (10.7%) patients, and the index finger in two (7.1%) patients (Figures 1-3). There was no statistically significant difference in the affected side (right/left) and fingers ( $p=0.43$  and  $p>0.05$ , respectively) (Table I).

Patients evaluated radiologically based on the fracture type revealed that 26 (92.85%) had

Salter-Harris type 1 injuries, while two (7.15%) had Salter-Harris type 2 injuries. Analysis by treatment method revealed that 20 (71.4%) patients were treated conservatively, while eight (28.6%) patients underwent surgical treatment. Among the surgically treated patients, one (3.5%) experienced loss of reduction, and another one (3.5%) developed superficial infection, which later progressed to osteomyelitis. Early antibiotic administration within 24 h significantly reduced infection rates in the latter patient. In the long term, this patient developed a finger deformity due to physeal arrest (Figure 4). The patient with loss of reduction was found to have had the needle dislodged during

Side/affected finger	1 <sup>st</sup> finger	2 <sup>nd</sup> finger	3 <sup>rd</sup> finger	4 <sup>th</sup> finger	5 <sup>th</sup> finger	Total
Right	5	1	5	1	0	12
Left	6	1	4	2	3	16
Total	11	2	9	3	3	28



dressings, followed by a delayed presentation, which prevented revision surgery. The complication rate was significantly higher in surgically treated patients compared to those treated conservatively ( $p=0.02$  and  $p<0.05$ , respectively). However, this was attributed to the more complex nature of the injuries requiring surgical treatment.

Evaluation of patients based on finger mobility showed no motion loss in the conservatively treated group at the final follow-up. In the surgically treated group, motion restrictions were noted in only two patients: one with loss of reduction and the other with osteomyelitis. During follow-up, the fracture of the patient with loss of reduction was observed to remodel over time, leading to improved finger joint motion. At the final follow-up, this patient was able to use their hand functionally and experienced no difficulty holding a pencil.

In contrast, the patient with osteomyelitis and associated bone lysis developed a deformity over time, with the distal phalanx deviating ulnar (Figure 4).

## DISCUSSION

The Seymour fractures are a rare, but clinically significant type of injury in children, capable of leading to serious complications. This study emphasizes that early intervention and appropriate antibiotic use in the management of Seymour fractures significantly reduce the risks of infection and long-term deformities. Although conservative methods have been reported in the literature as a viable treatment option for these fractures, the importance of surgical intervention in unstable cases is also notable. In the present study, we examined the impact of different treatment approaches on outcomes to contribute to the literature by presenting comparative results of conservative and surgical treatments.

There is still no consensus on the treatment of acute Seymour fractures. Treatment methods vary in many centers, ranging from closed reduction and splinting in the emergency department to reduction with a Kirschner wire (K-wire)/injector needle under sedation in the operating room and nail bed

revision.<sup>[3,5,8,9]</sup> However, many surgeons recommend applying open fracture principles in treatment.<sup>[2,6,8-11]</sup> Lin et al.,<sup>[2]</sup> in a series of 65 cases, reported that 89% of patients were treated in the emergency department, indicating that most acute Seymour fractures could be successfully managed in the emergency setting without requiring surgical intervention. However, Pere-Lopez et al.,<sup>[11]</sup> in a series of 29 cases reported that 82.7% of patients were treated with a K-wire in the operating room. Al-Qattan,<sup>[6]</sup> in a study of 25 patients, reported conservative treatment for 18 (72%) patients with closed reduction and splinting. Abzug et al.<sup>[7]</sup> also recommended treating these fractures in the operating room under general anesthesia. In this study, we treated 28.6% (n=8) of patients in the operating room. In our study, surgical intervention in the operating room was prioritized for patients with fractures that could not be reduced closed in the emergency department or those with unstable fractures. This approach aligns with the varying treatment strategies in the literature, particularly those of Pere-Lopez et al.<sup>[11]</sup> and Lin et al.,<sup>[2]</sup> emphasizing decision-making based on the fracture type and complexity of the injury.

In Seymour injuries, the injured nail matrix can enter the fracture line, leading to contamination. Therefore, Seymour injuries carry a higher risk of infection than other open injuries of the distal phalanx. Surgical treatment is recommended to ensure that there is no soft tissue interposition in the fracture area.<sup>[7]</sup> Before reduction, soft tissue fragments should be removed with maneuvers such as hyperflexion of the finger or traction of the distal fragment.<sup>[9]</sup> Failure to remove these soft tissues properly can lead to nail deformity, osteomyelitis, or physeal arrest.<sup>[7]</sup> Early diagnosis and treatment of these injuries are therefore crucial. If patients are not treated properly, various complications may arise, with infection-related osteomyelitis being one of the most significant. In a study by Krusche-Mandl et al.,<sup>[5]</sup> 16 of 24 patients with Seymour fractures were treated surgically, with no infections reported. Lin et al.<sup>[2]</sup> reported that the most common complication in their study was superficial infection, which manifested as cellulitis and healed with oral antibiotics. They also reported that only one of the 65 patients developed a deep infection (osteomyelitis), which was treated with a second surgery and clindamycin. Reyes and Ho,<sup>[9]</sup> in a study of 34 Seymour fractures, classified patients into "appropriate," "partial," "acute," and "delayed" treatment groups, with two cases of superficial infection and five cases of osteomyelitis in total. No

infections were reported in the "acute, appropriately treated" group, while the infection rate was 45% (5/11) in the "delayed" group treated after 24 h of injury. They also reported two infections (15.4%) in the "acute, partially treated" group. Rask et al.<sup>[8]</sup> reported a general infection rate of 27.3% (15/54 fractures) in their study. This study detected osteomyelitis in 3.5% (n=1) of the patients. The treatment for this patient was completed with serial debridement and oral antibiotics, although a finger deformity developed. In our study, early diagnosis and treatment protocols were found to play a critical role in reducing infection rates. Compared to the higher infection rates reported in the literature (up to 27.3%), our early intravenous antibiotic administration and irrigation protocol appear to provide effective protection. These results underscore the importance of timing and methodology in treatment once again.

In the literature, some authors advocate conservative treatment of Seymour fractures, citing an increased risk of infection with K-wire use.<sup>[1,8,12,13]</sup> In his study, Seymour<sup>[1]</sup> reported pin-track infections in two of five patients treated with K-wire fixation and osteomyelitis in one patient, and concluded that K-wire fixation was unnecessary due to the risk of infection. In the aforementioned study, no perioperative antibiotic therapy, formal irrigation, or debridement was applied. Pere-Lopez et al.<sup>[11]</sup> reported infection rates of 4.8% with K-wire use and 50% without K-wire use in their study, concluding that the risk of infectious osteomyelitis was lower when K-wire was used as a synthesis method. The authors suggested that factors such as antibiotics, debridement, and nail bed repair, rather than the K-wire itself, might contribute to this situation. However, some authors argue that Seymour fractures should be treated as open fractures, with infection prevention achieved through early irrigation, debridement, and antibiotics, and that K-wire fixation can be applied in unstable fractures.<sup>[2,5-7,13]</sup> In this study, we reduced unstable fractures in the operating room, using a 21G needle for reduction. However, we did not find any association between needle use and infection. Our study suggests that the use of a 21G needle for reduction in unstable Seymour fractures may serve as an effective treatment method, avoiding the infection risks associated with K-wire fixation reported in the literature. This finding highlights that the effectiveness of methods to reduce infection risk is strongly associated not only with

the fixation material, but also with the protocols followed during treatment, such as irrigation and perioperative antibiotic administration.

One of the most critical steps in preventing infection in open fractures is early intravenous antibiotic therapy and adequate irrigation. The most commonly used agents in treatment are cephalosporin antibiotics. Antibiotic therapy, debridement, irrigation, and fracture reduction within the first 24 h after injury significantly reduce the infection rate.<sup>[8,9]</sup> Rask et al.,<sup>[8]</sup> in their study of 54 Seymour fractures, reported an infection rate of 6.9% (n=2) among 29 fractures treated with antibiotics within 24 h of injury, compared to 76.5% (n=13) among 17 fractures treated with antibiotics after 24 h. They also reported that patients with delayed antibiotic administration had a higher risk of early superficial infection or osteomyelitis. However, there are different opinions regarding the use of antibiotics in the postoperative period. The most commonly prescribed oral antibiotics for acute Seymour fractures are cephalexin, cefazolin, clindamycin, trimethoprim/sulfamethoxazole, and amoxicillin-clavulanate.<sup>[8]</sup> Though, in delayed cases, clindamycin is preferred due to its effective bone penetration<sup>[14]</sup> In a review by Kiely et al.,<sup>[15]</sup> which included 56 studies with 352 patients and 355 fractures, early (<48 h) debridement was associated with a significant reduction in infection and malunion risk, and prophylactic (<24 h) antibiotic use significantly reduced infection risk. Prophylactic antibiotics and debridement were associated with a 70% reduction in infection risk. They reported that more than a third of patients who presented late had an infected wound at the time of admission. In this study, we administered intravenous cefazolin in the emergency department at the time of initial presentation, and we recommended a two-week course of oral antibiotic therapy postoperatively. While no infections were observed in the conservatively followed group, one (3.5%) patient in the surgically treated group developed initial superficial infection and wound necrosis, which progressed to deep infection and osteomyelitis with bone osteolysis. Consequently, this patient developed physical arrest and finger deformity. In our study, the differences observed in infection rates between the conservative treatment group and the surgical treatment group can be attributed to the initial severity of the fractures being treated. However, early intravenous antibiotic therapy, thorough irrigation, and appropriate surgical protocols proved effective in maintaining

low infection rates.<sup>[16]</sup> These findings support the importance of early treatment and prophylactic antibiotic use as highlighted in the literature. Future large-scale studies could further enhance the understanding of this field by providing a more detailed comparison of surgical and conservative treatment outcomes.

Nail dystrophy and growth arrest resulting in finger growth cessation are other complications observed after Seymour fractures. Review of the literature reveals that growth arrest is due to deep infection rather than direct impact.<sup>[17-19]</sup> Nail deformities are reported to result from direct injury to the nail bed.<sup>[5]</sup> However, many studies lack sufficient data to assess nail deformities.<sup>[11]</sup> Lin et al.<sup>[2]</sup> reported growth arrest in only two patients, both of whom were treated in the emergency department with irrigation/debridement and reduction and discharged with cephalexin. They also reported that only 24 of the 65 patients were followed long enough after the initial injury to document any nail growth, with only one case of nail dystrophy recorded. In his study, Seymour<sup>[1]</sup> reported deformity in three of the conservatively treated patients, with one requiring surgery. Reyes and Ho et al.<sup>[9]</sup> reported a case complicated by malunion requiring surgery, with no complications noted two months after surgery. They also reported a case of fingertip necrosis following Seymour fracture, which required a series of surgical procedures, and noted that the wound healed without infection by the second postoperative month. In the current study, we did not observe any cases of nail dystrophy. The absence of nail dystrophy in any of the patients in our study is attributed to the effectiveness of our treatment protocols. Early intravenous antibiotic therapy, irrigation of the injury site, and nail bed repair may have played a critical role in preventing such complications. Furthermore, previous studies have suggested that nail dystrophy is sometimes not observed due to insufficient follow-up periods in certain cases. We believe that the one-year follow-up period in our study was sufficient to evaluate potential complications. Similarly, growth arrest is often reported to be associated with deep infections. The low infection rate in our study (3.5%) and the limited occurrence of severe infections such as osteomyelitis may have contributed to the prevention of growth plate arrest.<sup>[16]</sup>

Nonetheless, there are some limitations to this study. The main limitation is that this rare injury was studied retrospectively in a single

institution. In addition, the relatively small number of patients in each group limited the statistical power of comparisons. For more robust statistical data, it is essential to conduct prospective studies with a larger patient population and standardized treatment protocols.

In conclusion, our study results suggest that Seymour fractures can be treated in the emergency department, if stable reduction is achieved. However, for Seymour injuries which cannot be reduced in the emergency department or require internal fixation, treatment should be performed in the operating room. More importantly, antibiotherapy within the first 24 h after injury is an effective way to prevent infection.

**Data Sharing Statement:** The data that support the findings of this study are available from the corresponding author upon reasonable request.

**Author Contributions:** Idea/concept, design, analysis and/or interpretation, literature review, critical review: A.Y., C.K.; Control/supervision: A.Y., G.Y., M.C.A.; Data collection and/or processing: A.Y., G.Y., H.Ç., C.K.; Writing the article: A.Y., G.Y., H.Ç.; References and fundings: A.Y., G.Y., M.C.A., H.Ç.; Materials: A.Y., M.C.A., H.Ç.

**Conflict of Interest:** The authors declared no conflicts of interest with respect to the authorship and/or publication of this article.

**Funding:** The authors received no financial support for the research and/or authorship of this article.

## REFERENCES

- Seymour N. Juxta-epiphysal fracture of the terminal phalanx of the finger. *J Bone Joint Surg Br* 1966;48:347-9.
- Lin JS, Popp JE, Balch Samora J. Treatment of acute seymour fractures. *J Pediatr Orthop* 2019;39:e23-7. doi: 10.1097/BPO.0000000000001275.
- Nellans KW, Chung KC. Pediatric hand fractures. *Hand Clin* 2013;29:569-78. doi: 10.1016/j.hcl.2013.08.009.
- Ganayem M, Edelson G. Base of distal phalanx fracture in children: A mallet finger mimic. *J Pediatr Orthop* 2005;25:487-9. doi: 10.1097/01.bpo.0000158813.37225.fa.
- Krusche-Mandl I, Köttstorfer J, Thalhammer G, Aldrian S, Erhart J, Platzer P. Seymour fractures: Retrospective analysis and therapeutic considerations. *J Hand Surg Am* 2013;38:258-64. doi: 10.1016/j.jhsa.2012.11.015.
- Al-Qattan MM. Extra-articular transverse fractures of the base of the distal phalanx (Seymour's fracture) in children and adults. *J Hand Surg Br* 2001;26:201-6. doi: 10.1054/jhsb.2000.0549.
- Abzug JM, Kozin SH. Seymour fractures. *J Hand Surg Am* 2013;38:2267-70. doi: 10.1016/j.jhsa.2013.08.104.
- Rask DMG, Wingfield J, Elrick B, Chen C, Lalka A, Sibbel SE, et al. Seymour fractures: A retrospective review of infection rates, treatment and timing of antibiotic administration. *Pediatr Emerg Care* 2021;37:e1299-302. doi: 10.1097/PEC.0000000000002009.
- Reyes BA, Ho CA. The high risk of infection with delayed treatment of open seymour fractures: Salter-Harris I/II or Juxta-epiphyseal fractures of the distal phalanx with associated nailbed laceration. *J Pediatr Orthop* 2017;37:247-53. doi: 10.1097/BPO.0000000000000638.
- Kattan AE, AlShomer F, Alhujayri AK, Alfowzan M, Murrad KA, Alsajjan H. A case series of pediatric seymour fractures related to hoverboards: Increasing trend with changing lifestyle. *Int J Surg Case Rep* 2017;38:57-60. doi: 10.1016/j.ijscr.2017.06.058.
- Perez-Lopez LM, Parada-Avenidaño I, Cabrera-Gonzalez M, Fontecha CG. Seymour fracture: Better do not underestimate it. *Jt Dis Relat Surg* 2021;32:569-74. doi: 10.52312/jdrs.2021.330.
- Barton NJ. Fractures of the phalanges of the hand in children. *Hand* 1979;11:134-43. doi: 10.1016/s0072-968x(79)80025-x.
- Cha SM, Kang JW, Shin HD, Ga IH. Acute Seymour fractures in children/adolescents overlooked as a simple nail injury: Reduction without pinning. *Hand Surg Rehabil* 2021;40:171-6. doi: 10.1016/j.hansur.2020.11.009.
- Samade R, Lin JS, Popp JE, Samora JB. Delayed presentation of Seymour fractures: A single institution experience and management recommendations. *Hand (N Y)* 2021;16:686-93. doi: 10.1177/1558944719878846.
- Kiely AL, Nolan GS, Cooper LRL. Management of Seymour fractures in children and adolescents: A systematic review and meta-analysis. *J Hand Surg Am* 2022;47:1223.e1-3.e20. doi: 10.1016/j.jhsa.2021.08.022.
- Atik OŞ. Writing for Joint Diseases and Related Surgery (JDRS): There is something new and interesting in this article! *Jt Dis Relat Surg* 2023;34:533. doi: 10.52312/jdrs.2023.57916.
- Engber WD, Clancy WG. Traumatic avulsion of the finger nail associated with injury to the phalangeal epiphyseal plate. *J Bone Joint Surg [Am]* 1978;60:713-4.
- Wood VE. Fractures of the hand in children. *Orthop Clin North Am* 1976;7:527-42.
- Ganayem M, Edelson G. Base of distal phalanx fracture in children: A mallet finger mimic. *J Pediatr Orthop* 2005;25:487-9. doi: 10.1097/01.bpo.0000158813.37225.fa.