



# Hidden blood loss and risk factors in percutaneous endoscopic cervical discectomy

Fei Wang , Yun Yang 

Department of Orthopaedics, The Third People's Hospital of Chengdu, Chengdu, China

Cervical disc herniation is caused by degeneration of cervical intervertebral discs, which can compress the nerve roots, leading to cervical radicular pain, and the spinal cord, leading to symptoms such as numbness of the limbs, fatigue, and unsteady walking.<sup>[1,2]</sup> Anterior cervical discectomy and fusion is currently the standard surgery for the treatment of cervical disc disease. However, there are some challenges with anterior surgery, such as limited motion and adjacent segmental lesions.<sup>[3,4]</sup> Although artificial cervical disc replacement can preserve the motion segments, there are risks of endograft loosening, subsidence, and heterotopic ossification.<sup>[5-7]</sup>

With the maturity of spinal endoscopic technology, posterior cervical discectomy is increasingly used in the treatment of cervical disc herniation with the advantages of less trauma and satisfactory efficacy.<sup>[8]</sup> Due to these advantages, some spine surgeons have overlooked a potential problem known as hidden blood loss (HBL). This concept was first introduced in 2000 by Sehat et al.<sup>[9]</sup> and has received increasing

## ABSTRACT

**Objectives:** The study aimed to evaluate the hidden blood loss (HBL) and its possible risk factors in patients undergoing percutaneous endoscopic cervical discectomy (PECD) via posterior approach to better guide the management of perioperative anemia in patients.

**Patients and methods:** The study retrospectively analyzed the clinical data of 60 patients (33 males, 27 females; mean age: 55.3±7.9 years; range, 40 to 69 years) treated with PECD between March 2019 and January 2023. All patients had cervical disc herniation or radiculopathy. General information (age, sex, height, weight, body mass index, Visual Analog Scale pain score, and comorbidities), surgery-related data (surgical time, number of surgical segments, American Society of Anesthesiologists score, and blood transfusions), and laboratory-related results (hemoglobin, hematocrit, albumin, and blood glucose) of the patients were collected from the hospital database. The patients' HBL was calculated based on the patients' height, weight, and hematocrit levels, and then the risk factors were analyzed by multiple linear regression.

**Results:** Only five patients underwent two-segment PECD via a single channel. The mean surgical time and HBL were 110.3±34.0 min and 114.5±50.2 mL, respectively. Six patients who were not anemic preoperatively developed anemia postoperatively, and the difference in the incidence of anemia between preoperative and postoperative periods was statistically significant ( $p=0.013$ ). Multiple linear regression analysis showed that HBL was associated with surgical time and the number of surgical segments ( $p<0.001$ ).

**Conclusion:** Hidden blood loss after PECD may represent a significant issue, with a risk of causing anemia. The number of surgical segments and surgical time are independent risk factors for HBL. Spine surgeons should emphasize the adverse effects of HBL to ensure the safety of patients in the perioperative period.

**Keywords:** Hidden blood loss, percutaneous endoscopic cervical discectomy, posterior approach, risk factors, single-segment cervical myelopathy.

Received: June 26, 2024

Accepted: August 21, 2024

Published online: November 22, 2024

**Correspondence:** Yun Yang, MD, Department of Orthopaedics, The Third People's Hospital of Chengdu, Chengdu, China.

E-mail: xgzl23yy@163.com

Doi: 10.52312/jdrs.2024.1872

**Citation:** Wang F, Yang Y. Hidden blood loss and risk factors in percutaneous endoscopic cervical discectomy. *Jt Dis Relat Surg* 2025;36(1):24-30. doi: 10.52312/jdrs.2024.1872.

©2024 All right reserved by the Turkish Joint Diseases Foundation

This is an open access article under the terms of the Creative Commons Attribution-NonCommercial License, which permits use, distribution and reproduction in any medium, provided the original work is properly cited and is not used for commercial purposes (<http://creativecommons.org/licenses/by-nc/4.0/>).

attention. Numerous studies have shown that HBL accounts for a considerable proportion of total blood loss (TBL) in spinal surgery patients.<sup>[10-13]</sup> This shows that the amount of HBL is much higher than surgeons

think. Clarifying HBL can more accurately estimate TBL in the perioperative period, which can guide surgeons' precise treatment and guarantee the safety of patients in the perioperative period.

Studies on HBL after PECD via posterior approach are rare in the literature. Therefore, this study aimed to calculate the amount of HBL during PECD via posterior approach and determine the risk factors leading to HBL.

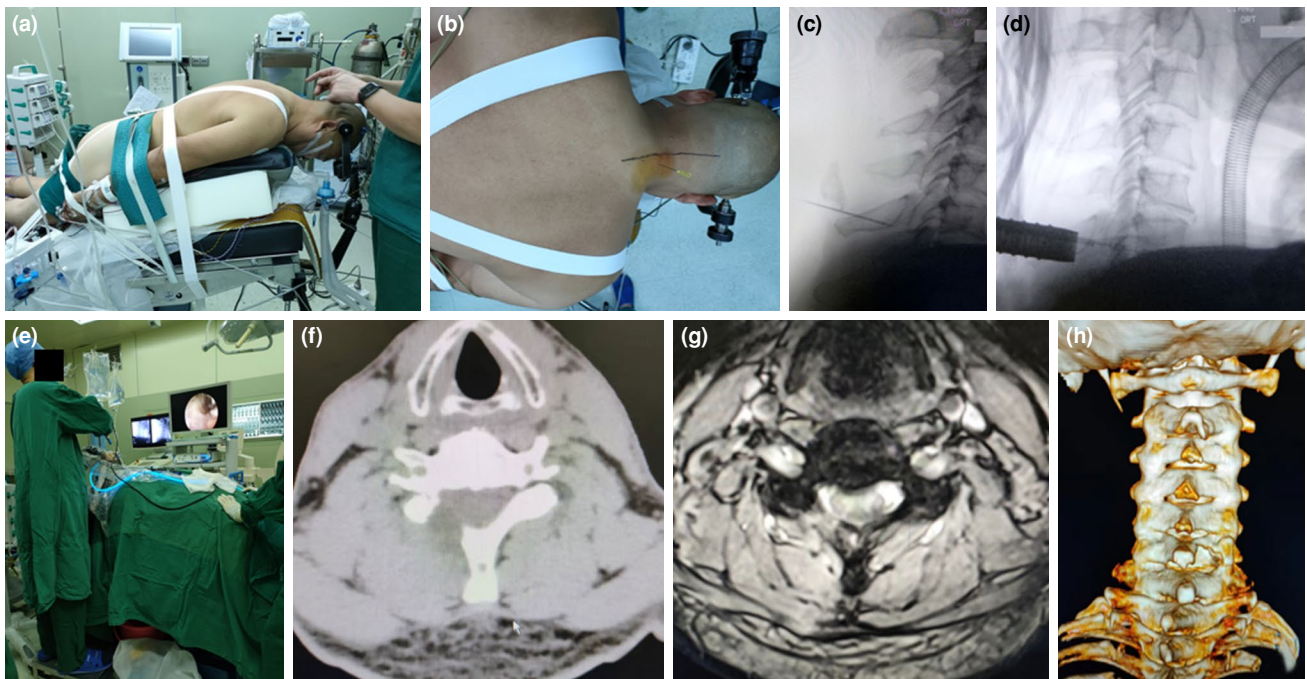
## PATIENTS AND METHODS

Sixty patients (33 males, 27 females; mean age:  $55.3 \pm 7.9$  years; range, 40 to 69 years) treated with PECD at the Third People's Hospital of Chengdu, Department of Orthopaedics between March 2019 and January 2023 were included in the retrospective study. The inclusion criteria were as follows: (i) diagnosis of cervical disc herniation or radiculopathy with a single- or double-segment lesion; (ii) receiving PECD with posterior approach; (iii) being 18 years of age or older. Exclusion criteria were as follows: (i) previous cervical spine surgery; (ii) coagulation disorders or prolonged use of oral antiplatelet drugs; (iii) use of antifibrinolytic drugs (tranexamic acid

or aminocaproic acid) during surgery. The study protocol was approved by the Third People's Hospital of Chengdu Ethics Committee (date: 03.01.2019, no: 2019-S-11). Written informed consent was waived given the retrospective, observational nature of the study and the anonymity of all data. The study was conducted in accordance with the principles of the Declaration of Helsinki.

All surgeries were performed under general anesthesia as per standard procedure (Figure 1).<sup>[14,15]</sup> In the case of a two-segment cervical disc herniation and the patient's request for PECD via posterior approach, we used a single-channel procedure for two-segment disc removal and decompression. We used the complete blood counts, including hematocrit (Hct), tested on the third postoperative day to calculate HBL. This approach was chosen because the patients' hemodynamics were stabilized and fluid shifts were largely completed on the second or third postoperative day.<sup>[16]</sup>

Patient-related data was collected from the hospital's electronic medical record system. The main demographic characteristics, laboratory data, and surgery-related data, such as age, sex, height,



**FIGURE 1.** Cervical disc herniation treated by PECD in six of seven patients with cervical disc herniation are presented as examples. (a) Special posture. (b, c) Localization of the lesion segment. (d) Refluoroscopy to confirm the lesion segment after the establishment of the working channel. (e) Intraoperative disc removal. (f-h) Postoperative imaging indicating that the herniated disc was removed and decompression was complete.

PECD: Percutaneous endoscopic cervical discectomy.

weight, body mass index, Visual Analog Scale pain score, hemoglobin (Hb), Hct, albumin, blood glucose, surgical time, number of surgical segments, and American Society of Anesthesiologists score. The Hb concentration was used to define anemia (<120 g/L for females and <130 g/L for males).<sup>[17]</sup>

We calculated the patient's preoperative blood volume (PBV) using sex, weight, and height, according to Nadler et al.<sup>[18]</sup> The formula used was as follows:  $PBV (L) = k1 \times \text{height (m)}^3 + k2 \times \text{weight (kg)} + k3$ . For males, the k1, k2, and k3 values were 0.3669, 0.03219, and 0.6041, respectively. The k1, k2, and k3 values for females were 0.3561, 0.03308, and 0.1833, respectively.

The preoperative and postoperative Hct reflects TBL in the perioperative period. Therefore, TBL was calculated according to the Gross's<sup>[19]</sup> formula:  $TBL (L) = PBV (L) \times (Hct_{pre} - Hct_{post}) / Hct_{ave}$ . The  $Hct_{pre}$  was the initial preoperative Hct, the  $Hct_{post}$  was the Hct on the third postoperative day, and the  $Hct_{ave}$  was the average of  $Hct_{pre}$  and  $Hct_{post}$ .

Hidden blood loss was calculated according to the method of Sehat et al.<sup>[16]</sup> and the visible blood loss (i.e., sum of intraoperative and postoperative blood loss) was deducted from the TBL. Since intraoperative bleeding was minimal and no drains were placed, the measured blood loss was negligible. Therefore, the TBL was approximately equal to the HBL.

TABLE I			
Patients' demographic data and related parameters			
Variables	n	%	Mean±SD
Age (year)			55.3±7.9
Sex			
Male	33	55.0	
Female	27	45.0	
Height (m)			1.64±0.07
Weight (kg)			56.5±6.9
Body mass index (kg/m <sup>2</sup> )			20.9±2.2
Comorbidity			
Hypertension	3	5.0	
Diabetes mellitus	12	20.0	
Coronary heart disease	4	6.7	
Visual Analog Scale			7.2±1.1
Preoperative hemoglobin (g/L)			125.0±8.7
Preoperative hematocrit (ratio)			0.37±0.03
Preoperative albumin (g/L)			35.6±3.2
Preoperative blood glucose (mmol/L)			5.74±1.18
ASA classification			
I	10	16.7	
II	44	73.3	
III	6	10.0	
Number of surgical segments			
1	55	91.7	
2	5	8.3	
Surgical time (min)			110.3±34.0
Hidden blood loss (mL)			114.5±50.2
Blood transfusion			
Yes	0	0	
No	60	100	
Total	60	100	

SD: Standard deviation; ASA: American Society of Anesthesiologists.

	Preoperative		Postoperative		<i>p</i>
	<i>n</i>	Mean±SD	<i>n</i>	Mean±SD	
Hemoglobin		125.0±8.7		118.9±9.5	<0.001
Hematocrit		0.37±0.03		0.36±0.03	<0.001
Anemia	30		36		0.013
Total	60		60		-

PECD: Percutaneous endoscopic cervical discectomy.

### Statistical analysis

All data analyses were performed with the IBM SPSS version 25.0 software (IBM Corp., Armonk, NY, USA). The difference between preoperative and postoperative anemia was measured by a paired sample t-test. Multivariate linear regression analysis was performed to identify independent risk factors associated with HBL, including one quantitative variable (surgical time) and one qualitative variable (the number of surgical segments). In the qualitative variables, a single segment was set as 1, and double segments were set as 2. A *p*-value <0.05 was considered statistically significant.

Variables	<i>p</i>	Correlation
Age	0.502	-0.088
Sex	0.889	0.018
Height	0.822	-0.030
Weight	0.278	-0.142
Body mass index	0.362	-0.120
Visual Analog Scale	0.672	-0.056
Hypertension	0.087	0.223
Diabetes mellitus	0.701	-0.051
Coronary heart disease	0.619	-0.066
Preoperative hemoglobin	0.175	-0.178
Preoperative hematocrit	0.147	-0.190
Preoperative albumin	0.710	-0.049
Preoperative blood glucose	0.549	0.079
ASA classification	0.094	0.218
Surgical time	<0.001	0.738
Number of surgical segments	0.001	0.427

HBL: Hidden blood loss; ASA: American society of Anesthesiologists.

### RESULTS

About one-fifth of the patients had comorbid diabetes. Five patients underwent two-segment PECD under a single channel. Since the visible blood loss during surgery was minimal, negligible treatment was required. The mean surgical time and HBL were 110.3±34.0 min and 114.5±50.2 mL, respectively (Table I). None of the patients underwent wound drainage or received blood transfusion.

The mean Hb of the patients decreased from 125.0±8.7 g/L preoperatively to 118.9±9.5 g/L postoperatively. The prevalence of anemia was 50% and 60% before and after the operation, respectively, and the difference was statistically significant (*p*=0.013; Table II). Surgical time (*p*<0.001) and the number of surgical segments (*p*=0.001) were associated with HBL (Table III). Multiple linear regression analysis showed a positive correlation between surgical time and number of surgical segments and HBL (*p*<0.001; Table IV).

### DISCUSSION

Posterior PECD has been recognized as a minimally invasive procedure over the past decade due to the incision length of less than 1 cm.<sup>[20-22]</sup> The procedure, using the “K-hole” technique, provides better exposure to treat existing nerve root compression caused by lateral disc herniation or osteophytes.<sup>[23]</sup> This procedure has the advantages of less trauma, less bleeding, faster recovery, and short hospital stay without destabilizing the cervical segments. In our study, the mean HBL was 114.5±50.2 mL. This amount was much higher compared to the intraoperative visible blood loss. In addition, we noted that six patients with normal preoperative Hb developed anemia postoperatively. In elderly patients, particularly those with preoperative anemia already present, additional HBL in the perioperative period may increase the



**TABLE IV**  
Multiple linear regression analysis of factors influencing HBL following PECD

Independent variables	B value	SE	$\beta$	t	$p$
Constant	-61.662	18.729	-	-3.292	0.002
Number of surgical segments	60.114	14.056	0.336	4.277	<0.001
Surgical time	1.010	0.115	0.688	8.755	<0.001

HBL: Hidden blood loss; PECD: Percutaneous endoscopic cervical discectomy;  $R^2=0.656$ , adjusted  $R^2=0.644$ ,  $F=54.268$ ,  $p<0.001$ ; In the qualitative variables, a single segment was set as "1," and double segments were set as "2."

incidence of adverse events. Therefore, it is important not to ignore the potential impact of HBL in the perioperative period due to the minimally invasive nature of the procedure.

Hidden blood loss is usually attributed to extravasation of blood into tissues and hemolysis.<sup>[24,25]</sup> One study found that approximately 60% of HBL was attributable to tissue extravasation during transfusion and 40% to hemolysis.<sup>[16]</sup> However, another study using labeled erythrocytes suggested that HBL was primarily caused by perioperative bleeding into the interstitial compartment of the tissue.<sup>[24]</sup> Despite these different hypotheses, the risk factors associated with the amount of HBL have not been clarified. In the present study, we found that the amount of HBL was higher in patients with a long surgical time and two-segment PECD.

The working channel was adjusted to ensure that two-segment PECD could be accomplished under a single channel. Although this was a bold attempt, it was worth exploring from the point of view of minimally invasiveness and efficacy. However, the realization of this approach required intraoperative stripping of the soft tissues on the surface of the adjacent two-segment vertebral plate, which increased intraoperative bleeding and artificially created a larger penetrable tissue compartment, allowing blood to infiltrate the tissue space. All of the above may explain why this approach may cause an increase in HBL, and these explanations were consistent with the results of a previous study in patients undergoing total knee arthroplasty.<sup>[26]</sup> Therefore, to minimize HBL, prophylactic hemostasis should be performed intraoperatively, and the soft tissues should be tightly stripped against the vertebral plate.

A retrospective study found that in patients undergoing anterior lumbar interbody fusion, surgical time and multisegment surgery were independently associated with HBL.<sup>[27]</sup> Similar results were found in our study. It was clear that the longer

the surgical time, the more severe the surgery-related injury. Therefore, adequate preoperative planning, careful study of imaging data, and good control of the extent of laminectomy are necessary to avoid excessive removal of bony structures causing bleeding. Moreover, after establishing the working channel intraoperatively, fluoroscopic confirmation is necessary to avoid prolonged surgical time and aggravated soft tissue injury caused by repeated adjustments due to segmental errors.

Blood management has always been a major concern for spine surgeons. A series of intraoperative techniques can reduce blood loss, such as bipolar electrocoagulation for precise hemostasis, hemostatic materials such as absorbable gelatin sponges, and the use of tranexamic acid and bone waxing for bleeding on the bone surface.<sup>[28-30]</sup> For PECD, in addition to the use of radiofrequency electrodes, precise hemostasis can be achieved using the traditional open spine surgery methods described above. These techniques of microscopic surgical maneuvers are important for the safety of the procedure.

This study had several limitations. First, this was a retrospective analysis with a small group of patients, and further prospective studies with large sample sizes are needed to confirm our findings. Second, we calculated HBL on the postoperative third day based on previous studies, which may not be the optimal time to perform the metric. More studies are needed to confirm the correct time to assess hemodynamic stability. Third, the lack of a control group was also one of the shortcomings of this study.

In conclusion, spine surgeons should consider that patients may develop more anemia in case of prolonged surgical time or two-segment PECD. Therefore, HBL needs to be emphasized during the perioperative period of PECD to ensure patient safety.

**Data Sharing Statement:** The data that support the findings of this study are available from the corresponding author upon reasonable request.

**Author Contributions:** Conception and design: F.W., Y.Y.; Collection and assembly of data: Y.Y.; Analysis and interpretation of the data: F.W., Y.Y.; Drafting of the article: F.W.; Statistical expertise: Y.Y.; Critical revision of the article for important intellectual content: Y.Y.; All authors read and approved the final manuscript.

**Conflict of Interest:** The authors declared no conflicts of interest with respect to the authorship and/or publication of this article.

**Funding:** The authors received no financial support for the research and/or authorship of this article.

## REFERENCES

- Ling T, Liu L, Song Y, Zhou S, Zhou C. Neurological impairment in a patient with concurrent cervical disc herniation and POEMS syndrome. *Eur Spine J* 2019;28(Suppl 2):51-5. doi: 10.1007/s00586-019-05914-5.
- Huang X, Ye L, Liu X, Weng R, Tan J, Xie P, et al. The relationship between facet tropism and cervical disc herniation. *J Anat* 2020;236:916-22. doi: 10.1111/joa.13151.
- Chung JY, Park JB, Seo HY, Kim SK. Adjacent segment pathology after anterior cervical fusion. *Asian Spine J* 2016;10:582-92. doi: 10.4184/asj.2016.10.3.582.
- Li L, Li N, Zhou J, Li H, Du X, He H, et al. Effect of cervical alignment change after anterior cervical fusion on radiological adjacent segment pathology. *Quant Imaging Med Surg* 2022;12:2464-73. doi: 10.21037/qims-21-732.
- Ji GY, Oh CH, Shin DA, Ha Y, Yi S, Kim KN, et al. Artificial disk replacement combined with fusion versus 2-level fusion in cervical 2-level disc disease with a 5-year follow-up. *Clin Spine Surg* 2017;30:E620-7. doi: 10.1097/BSD.0000000000000316.
- Tabanlı A, Eren TK. Comparison of fusion, arthroplasty and hybrid surgery outcomes in patients with two-level cervical disc disease. *Jt Dis Relat Surg* 2024;35:596-602. doi: 10.52312/jdrs.2024.1663.
- Häckel S, Gaff J, Pabbruwe M, Celenza A, Kern M, Taylor P, et al. Heterotopic ossification, osteolysis and implant failure following cervical total disc replacement with the M6-C™ artificial disc. *Eur Spine J* 2024;33:1292-9. doi: 10.1007/s00586-024-08129-5.
- Li J, Zhang T. Comparison of clinical outcomes and complications of biportal and uniportal endoscopic decompression for the treatment of cervical spondylotic radiculopathy: A systematic review and meta-analysis. *Jt Dis Relat Surg* 2024;35:583-93. doi: 10.52312/jdrs.2024.1820.
- Sehat KR, Evans R, Newman JH. How much blood is really lost in total knee arthroplasty? Correct blood loss management should take hidden loss into account. *Knee* 2000;7:151-5. doi: 10.1016/s0968-0160(00)00047-8.
- Guo S, Yu Z, Wang C, Zhong M, Wang R, Hu Y, et al. Risk factors of hidden blood loss in unilateral biportal endoscopic surgery for patients with lumbar spinal stenosis. *Orthop Surg* 2024;16:842-50. doi: 10.1111/os.14009.
- Yang Y, Wang F. Hidden blood loss in unilateral open-door cervical laminoplasty for multilevel cervical spondylotic myelopathy. *Jt Dis Relat Surg* 2024;35:293-8. doi: 10.52312/jdrs.2024.1439.
- Raitio A, Heiskanen S, Soini V, Helenius L, Syvänen J, Helenius I. Hidden blood loss and bleeding characteristics in children with congenital scoliosis undergoing spinal osteotomies. *Int Orthop* 2024;48:1569-77. doi: 10.1007/s00264-024-06090-y.
- Yue X, Zhang J, Sun T, Zhang W, Yang M, Li Z. Hidden blood loss and its influencing factors after minimally invasive percutaneous transpedicular screw fixation in thoracolumbar fracture. *BMC Musculoskelet Disord* 2022;23:959. doi: 10.1186/s12891-022-05938-x.
- Quillo-Olvera J, Lin GX, Kim JS. Percutaneous endoscopic cervical discectomy: A technical review. *Ann Transl Med* 2018;6:100. doi: 10.21037/atm.2018.02.09.
- Zheng C, Huang X, Yu J, Ye X. Posterior percutaneous endoscopic cervical discectomy: A single-center experience of 252 cases. *World Neurosurg* 2018;120:e63-7. doi: 10.1016/j.wneu.2018.07.141.
- Sehat KR, Evans RL, Newman JH. Hidden blood loss following hip and knee arthroplasty. Correct management of blood loss should take hidden loss into account. *J Bone Joint Surg [Br]* 2004;86:561-5.
- Beghé C, Wilson A, Ershler WB. Prevalence and outcomes of anemia in geriatrics: A systematic review of the literature. *Am J Med* 2004;116 Suppl 7A:3S-10S. doi: 10.1016/j.amjmed.2003.12.009.
- Nadler SB, Hidalgo JH, Bloch T. Prediction of blood volume in normal human adults. *Surgery* 1962;51:224-32.
- Gross JB. Estimating allowable blood loss: Corrected for dilution. *Anesthesiology* 1983;58:277-80. doi: 10.1097/0000542-198303000-00016.
- Yang JS, Chu L, Chen L, Chen F, Ke ZY, Deng ZL. Anterior or posterior approach of full-endoscopic cervical discectomy for cervical intervertebral disc herniation? A comparative cohort study. *Spine (Phila Pa 1976)* 2014;39:1743-50. doi: 10.1097/BRS.0000000000000508.
- Wu PF, Liu BH, Wang B, Li YW, Dai YL, Qing YL, et al. Complications of full-endoscopic versus microendoscopic foraminotomy for cervical radiculopathy: A systematic review and meta-analysis. *World Neurosurg* 2018;114:217-27. doi: 10.1016/j.wneu.2018.03.099.
- Ahn Y. Percutaneous endoscopic cervical discectomy using working channel endoscopes. *Expert Rev Med Devices* 2016;13:601-10. doi: 10.1080/17434440.2016.1180245.
- Roh SW, Kim DH, Cardoso AC, Fessler RG. Endoscopic foraminotomy using MED system in cadaveric specimens. *Spine (Phila Pa 1976)* 2000;25:260-4. doi: 10.1097/00007632-200001150-00019.
- Erskine JG, Fraser C, Simpson R, Protheroe K, Walker ID. Blood loss with knee joint replacement. *J R Coll Surg Edinb* 1981;26:295-7.
- Faris PM, Ritter MA, Keating EM, Valeri CR. Unwashed filtered shed blood collected after knee and hip arthroplasties. A source of autologous red blood cells. *J Bone Joint Surg [Am]* 1991;73:1169-78.
- Gao F, Guo W, Sun W, Li Z, Wang W, Wang B, et al. Correlation between the coverage percentage of prosthesis and postoperative hidden blood loss in primary total knee arthroplasty. *Chin Med J (Engl)* 2014;127:2265-9.
- Ju H, Hart RA. Hidden blood loss in Anterior Lumbar Interbody Fusion (ALIF) surgery. *Orthop Traumatol Surg Res* 2016;102:67-70. doi: 10.1016/j.otsr.2015.10.003.

28. Wu J, Jin Y, Zhang J, Shao H, Yang D, Chen J. Hemostatic techniques following multilevel posterior lumbar spine surgery: A randomized control trial. *J Spinal Disord Tech* 2014;27:442-6. doi: 10.1097/BSD.0000000000000063.
29. Xu D, Ren Z, Chen X, Zhuang Q, Sheng L, Li S. A randomized controlled trial on effects of different hemostatic sponges in posterior spinal fusion surgeries. *BMC Surg* 2016;16:80. doi: 10.1186/s12893-016-0197-3.
30. Mu X, Wei J, Wang C, Ou Y, Yin D, Liang B, et al. Intravenous administration of tranexamic acid significantly reduces visible and hidden blood loss compared with its topical administration for double-segment posterior lumbar interbody fusion: A single-center, placebo-controlled, randomized trial. *World Neurosurg* 2019;122:e821-7. doi: 10.1016/j.wneu.2018.10.154.