








Efficacy and safety of hollow pedicle screw-anchored bone cement combined with posterior long-segment fixation for Stage III Kümmell's disease

Dongjie Kan , Jinghuai Wang , Guoyong Qiao , Yanan Chen , Dongping Han 

Department of Orthopedic, Affiliated Hospital of Hebei University of Engineering, Handan City, Hebei Province, China

The rising prevalence of Kümmell's disease, a delayed type of osteoporotic vertebral fracture, is becoming a significant challenge in our increasingly aging population. Characterized by vertebral osteonecrosis and subsequent collapse, Kümmell's disease often leads to severe pain, reduced mobility, and neurological complications, severely impacting the quality of life of affected individuals.^[1-4] While early stages of Kümmell's disease may respond to less invasive treatments such as vertebroplasty, Stage III of the disease, marked by vertebral body collapse and spinal instability, necessitates more complex surgical intervention.^[4-7]

Traditional treatments for Stage III Kümmell's disease, which involves either anterior or posterior decompression or a combination of both, are fraught with significant challenges, including

Received: May 28, 2024

Accepted: August 20, 2024

Published online: November 22, 2024

Correspondence: Dongping Han, MD. Department of Orthopedic, Affiliated Hospital of Hebei University of Engineering, Handan City, Hebei Province, 056000, China.

E-mail: handongping2024@126.com

Doi: 10.52312/jdrs.2024.1834.

Citation: Kan D, Wang J, Qiao G, Chen Y, Han D. Efficacy and safety of hollow pedicle screw-anchored bone cement combined with posterior long-segment fixation for Stage III Kümmell's disease. Jt Dis Relat Surg 2025;36(1):15-23. doi: 10.52312/jdrs.2024.1834.

©2024 All right reserved by the Turkish Joint Diseases Foundation

This is an open access article under the terms of the Creative Commons Attribution-NonCommercial License, which permits use, distribution and reproduction in any medium, provided the original work is properly cited and is not used for commercial purposes (<http://creativecommons.org/licenses/by-nc/4.0/>).

ABSTRACT

Objectives: The study aimed to evaluate the efficacy and safety of hollow pedicle screw-anchored bone cement combined with posterior long-segment fixation (LSF) for the treatment of Stage III Kümmell's disease.

Patients and methods: The study retrospectively analyzed 23 patients (18 females, 5 males; mean age: 70.1±6.2 years; range, 58 to 80 years) with Stage III Kümmell's disease who underwent hollow pedicle screw-anchored bone cement combined with posterior LSF between March 2017 and April 2020. The clinical efficacy was evaluated using the Visual Analog scale (VAS), the Oswestry Disability Index (ODI), anterior vertebral height, kyphotic Cobb angle, and neurological function by Frankel classification. Complications, operation time, intraoperative blood loss, and complications were obtained from the hospital records. Data recorded at three time intervals (before the surgery, early postoperative period, and the last follow-up) were compared.

Results: The mean follow-up time was 20.8±6.1 months. The mean operation time was 102±16.5 min, and the mean intraoperative blood loss was 225±41.3 mL. The VAS, ODI, anterior vertebral heights, and local kyphosis angle showed statistically significant differences between preoperative and postoperative values, as well as the preoperative and the final follow-up values ($p<0.05$). However, the differences between postoperative and final follow-up values were not statistically significant ($p>0.05$). Six patients (26%) had mild preoperative neurological deficits and normalized neurological function at the final follow-up evaluation. Asymptomatic leakage of cement occurred in five (22%) cases. There was no fixation failure (rod breakage or screw loosening).

Conclusion: Hollow pedicle screw-anchored bone cement combined with posterior LSF is a safe and effective surgical option for the treatment of Stage III Kümmell's disease.

Keywords: Anchoring bone cement, hollow pedicle screws, Kümmell's disease, long-segment posterior internal fixation.

prolonged recovery, increased blood loss, and a higher risk of complications.^[8,9] This has led to a search for more effective and less invasive surgical

techniques. Among the promising approaches is the use of hollow pedicle screw-anchored bone cement combined with posterior long-segment fixation (LSF). This method aims to provide the dual benefits of stabilizing the vertebral body through the anchoring effect of bone cement and reducing surgical trauma by avoiding extensive decompression and bone grafting.^[10-13]

The current study introduces an innovative approach to treating Stage III Kümmell's disease, leveraging the novel technique of hollow pedicle screw anchorage combined with long-segment posterior fixation. By filling the intravertebral voids with bone cement and securing the construct with anchored pedicle screws, this method aims to provide enhanced stability, reduced risk of cement leakage, and improved patient outcomes. The significance of our research lies in its potential to offer a safer, more effective treatment alternative for patients with advanced Kümmell's disease, where conventional methods fall short. Through detailed clinical and imaging analysis, this study aimed to validate the efficacy and safety of this approach, providing new insights into managing this challenging condition.

PATIENTS AND METHODS

In the retrospective study, 23 patients with single-segment Stage III Kümmell's disease who underwent hollow pedicle screw-anchored bone cement combined with LSF at the Affiliated Hospital of Hebei University of Engineering, Department of Orthopedic between March 2017 and April 2020 were recruited. The inclusion criteria were as follows: (i) a diagnosis of Stage III Kümmell's disease based on symptoms, signs, and imaging; (ii) single-level Kümmell's disease; (iii) primary osteoporotic fracture; (iv) lumbar bone mineral density T-score ≤ -2.5 (measured by dual-energy X-ray absorptiometry). The exclusion criteria were as follows: (i) patients with severe medical diseases or intolerance to surgery; (ii) patients with a history of thoracolumbar surgery; (iii) pathological fractures, such as vertebral metastases and primary tumors; (iv) Stages I and II Kümmell's disease. The surgical criteria were as follows: (i) patients with unremitting pain; (ii) patients with neurologic dysfunction; (iii) patients with progressive kyphosis; (iv) patients with spinal instability; (i) patients with failed percutaneous vertebroplasty or percutaneous kyphoplasty. Twenty-three patients (18 females, 5 males; mean age: 70.1±6.2 years; range, 58 to 80 years) met the criteria and were retrospectively

analyzed. The study protocol was approved by Institutional Review Board of Affiliated Hospital of Hebei University of Engineering (data: 16.06.2022, no: 2022[K]038). Written informed consent was obtained from all participants after an explanation of the surgical options. The study was conducted in accordance with the principles of the Declaration of Helsinki.

Preoperative dynamic mobility in the vertebral body was noted on radiographs. Computed tomography (CT) imaging suggested localized vacuum fissure changes in the injured vertebrae, with varying degrees of rupture at the vertebral body edges. Magnetic resonance imaging showed a low-signal area on the T1-weighted sequence and a restricted high-signal area on the T2-weighted sequence, as well as fat-suppression sequences, forming a demarcation zone with the surrounding relatively low-signal area.

Surgical procedure

The surgical intervention for Stage III Kümmell's disease was carried out under general anesthesia with patients in the prone position. Using fluoroscopic guidance from a C-arm X-ray machine for precision, the procedure commenced with a manual reduction to correct vertebral height loss, a technique adapted from Li et al.^[14] A posterior midline approach exposed the necessary spinal anatomy, and hollow pedicle screws were then inserted into the affected vertebra and extended two levels above and below for robust support. The critical phase involved the precise placement of these screws into the vertebral cavity, confirmed under fluoroscopy, to anchor the bone cement effectively. Bone cement, prepared to optimal viscosity, was injected through the screws into the vertebral body to thoroughly fill the intravertebral voids. If necessary, additional bone cement was applied to ensure the vertebral body's complete filling while monitoring for any overflow. In cases requiring spinal decompression, selective removal of the lamina and articular processes was performed, sparing the posterior vertebral edge. Following cement solidification, a connecting rod was installed to secure the assembly, aiding in kyphosis correction. The surgery was concluded with posterolateral fusion using both homogeneous allograft and autogenous bone grafts from any decompression performed. A drainage tube was inserted to manage postoperative fluids, and the incision was meticulously closed in layers, ensuring a clean and secure finish.

Postoperative management

Antibiotics were routinely used postoperatively for three days to prevent infection. The drainage tube was removed when the amount of drainage was less than 50 mL/day. All patients were mobilized three days after surgery and walked with the protection of a waist brace for three months after the operation. The patients were reviewed regularly at 1, 3, 6, and 12 months after surgery, and once a year thereafter. All patients received pharmacological antiosteoporosis treatment after discharge, including standard daily doses of calcium (800 mg orally once daily), alfacalcidol vitamin D supplementation (0.25 mg orally twice daily), and zoledronic acid (5 mg intravenously once yearly).

Efficacy evaluation method

Data at three different time intervals (before surgery, early postoperative period, and at the final follow-up) were compared. Clinical efficacy evaluation was conducted using the Visual Analog Scale (VAS). The VAS is a unidimensional measure of pain intensity widely used in diverse adult populations, including those with rheumatic diseases. The scale ranges from "no pain" (score of 0) to "worst imaginable pain" (score of 100) on a 100-mm scale. Patients are asked to place a mark on a line that represents their pain intensity. The VAS score is determined by measuring in millimeters from the left end of the line to the point that the patient indicates.

The Oswestry Disability Index (ODI) is one of the most used outcome measures for the assessment of disability and quality of life in individuals with lower back pain. It is a self-administered questionnaire divided into 10 sections that are designed to assess limitations in various aspects of daily living, including pain intensity, personal care, lifting, walking, sitting, standing, sleeping, sex life, social life, and traveling. Each section is scored on a scale from 0 to 5, with higher scores indicating greater disability. The total score is calculated as a percentage, with 0% representing no disability and 100% representing the maximum disability possible.

In this study, the VAS and ODI were used to evaluate the impact of hollow pedicle screw-anchored bone cement combined with posterior LSF on pain and functional outcomes in patients with Stage III Kümmell's disease. The VAS was employed to gauge the immediate and long-term effectiveness of the surgical intervention in alleviating pain at the fracture site, whereas the ODI was used to assess improvements in patients'

functional status and their ability to engage in daily activities after surgery.

During the imaging evaluation, (i) the anterior vertebral height was measured as the distance between the upper and lower endplates of the injured vertebra on a lateral X-ray, and (ii) the local kyphosis angle was determined using Cobb's method on a standard lateral radiograph.^[15] This angle was measured with one line passing over the normal endplate surface above the involved vertebra and the other passing over the normal endplate surface below the involved vertebra.

Statistical analysis

Statistical analyses were performed using IBM SPSS version 22.0 software (IBM Corp., Armonk, NY, USA). Data were expressed as mean \pm standard deviation (SD). The normality of data distribution was assessed using the Shapiro-Wilk test, given its suitability for samples of our size. For variables that followed a normal distribution ($p > 0.05$ in the Shapiro-Wilk test), parametric tests, including the paired t-test, were used to compare preoperative, postoperative, and follow-up measures. A p -value < 0.05 was considered statistically significant.

RESULTS

The disease course ranged from 2 to 7 months, with a mean of 3.9 ± 1.6 months. All patients had a history of minor back trauma, and the levels of diseased vertebrae were as follows: T11 (n=5), T12 (n=9), L1 (n=8), and L2 (n=1). The mean preoperative bone mineral density T-score was -3.4 ± 0.4 (range, -2.7 to -4.2). According to the Frankel classification, neurological function was divided into Grade D (n=6) and Grade E (n=17). Six patients underwent intraoperative decompression of the spinal canal and nerve roots due to neurological symptoms. The mean postoperative follow-up duration was 20.8 ± 6.1 months (range, 12 to 36 months). The mean hospital stay was 10.0 ± 1.6 days, the mean surgery time was 102 ± 16.5 min, and the mean blood loss was 225 ± 41.3 mL. The amount of bone cement injected into the only injured vertebrae ranged from 3.0 to 5.5 mL, with a mean of 4.2 ± 0.7 mL. Leakage of bone cement occurred in five patients, including leakage into the paravertebral area in two, the intervertebral space in two, and the paravertebral vein in one patient. However, no patient experienced related neurological or spinal cord symptoms. The general data are shown in Table I.

TABLE I
General characteristics of the patients

Case	Age/Sex	Medical history (month)	Hospitalization time (d)	Duration of follow-up (month)	Damaged segment	BMD (T score)	Comorbidity
1	70/M	2	10	18	T11	-3.7	Hypertension, diabetes disease
2	66/F	4	9	22	T12	-3.2	No
3	63/F	3	11	15	T12	-2.9	Diabetes disease
4	72/M	6	7	24	L2	-3.6	Hypertension, heart disease
5	66/F	3	10	36	T11	-2.7	Heart disease
6	75/F	5	11	19	L1	-3.5	Hypertension
7	68/F	2	10	25	T12	-2.9	Hypertension
8	70/F	3	8	12	L1	-3.8	Diabetes disease
9	62/F	7	9	15	T12	-3.0	Hypertension, heart disease
10	73/M	3	10	32	T11	-3.7	Heart disease
11	59/F	5	12	28	L1	-3.2	Hypertension, heart disease
12	77/F	2	9	16	T12	-3.8	Diabetes disease
13	80/F	6	14	17	L1	-4.2	No
14	76/M	3	9	25	T12	-3.6	Hypertension
15	78/F	4	12	14	T11	-3.8	No
16	58/F	2	11	24	L1	-2.8	Diabetes disease
17	65/F	7	10	17	T12	-3.3	Hypertension
18	73/F	5	9	25	L1	-3.5	Hypertension, heart disease
19	77/M	2	8	13	T12	-4.0	Hypertension
20	66/F	4	9	20	T11	-3.4	Hypertension
21	60/F	4	10	24	L1	-2.8	No
22	71/F	3	12	18	T12	-3.6	Diabetes disease
23	75/F	4	11	20	L1	-3.4	Hypertension

BMD: Bone mineral density.

One week after surgery, the mean VAS and ODI scores were 3.2 ± 0.7 and 40.6 ± 6.3 , respectively. During the follow-up period, the mean VAS and ODI scores were 1.9 ± 0.7 and 19.9 ± 5.4 , respectively. The VAS and ODI scores were significantly lower ($p<0.05$) at the early postoperative period compared to the

preoperative scores and were further reduced at the final follow-up compared to the postoperative values. Lasting pain relief and functional improvement were achieved in all cases ($p<0.05$; Table II).

One week after surgery, the mean anterior vertebral height and the mean local kyphosis angle

TABLE II
The VAS and ODI scores, kyphotic angle, and anterior vertebral height before the operation, one week after the operation, and at the last follow-up

	VAS	ODI (%)	Kyphotic angle (°)	Anterior vertebral height (mm)
	Mean±SD	Mean±SD	Mean±SD	Mean±SD
Preoperative	7.7 ± 1.0	75.8 ± 6.5	24.8 ± 15.2	11.9 ± 4.7
Early postoperative	$3.2\pm 0.7^*$	$40.6\pm 6.3^*$	$6.3\pm 10.7^*$	$21.1\pm 2.9^*$
Last follow-up	$1.9\pm 0.7^*\ddagger$	$19.9\pm 5.4^*\ddagger$	$6.7\pm 11.1^*\ddagger$	$20.6\pm 3.0^*\ddagger$
P-value	<0.001	<0.001	<0.001	<0.001

VAS: Visual Analog Scale; ODI: Oswestry Disability Index; SD: Standard deviation; * $p<0.05$ vs. preoperation values; † $p>0.05$ vs. 1 week postoperative values; ‡ $p>0.05$ vs. 1 week postoperative values.

TABLE III							
Frankel classification of 23 patients before the operation and at the last follow-up							
	Frankel classification					χ^2	<i>p</i>
	A	B	C	D	E		
Preoperative				6	17	6.9	0.009
Last follow-up				0	23		

were 21.1 ± 2.9 and 6.3 ± 10.7 , respectively. During the follow-up period, the mean anterior vertebral height and the mean Cobb angle were 20.6 ± 3.0 and 6.7 ± 11.1 , respectively. The anterior vertebral height and the Cobb angle were significantly corrected after surgery compared to the preoperative period, and the difference was statistically significant ($p < 0.05$; Table II). There was a mild loss in vertebral height and kyphosis correction at the final follow-up; however, the difference was not statistically significant compared to the early postoperative period ($p > 0.05$; Table II).

No complications, such as rod breakage, screw loosening, or collapse of the injured spine, were observed during the follow-up. According to the American Spinal Injury Association Impairment

Scale, six patients were preoperatively classified as Grade D and 17 as Grade E (Table III). At the final follow-up evaluation, all patients who had been Grade D before surgery were found to have improved to Grade E. Pre- and postoperative images of two typical patients with Stage III Kümmell's disease who underwent hollow pedicle screw-anchored bone cement combined with posterior LSF are shown in Figures 1 and 2.

DISCUSSION

This study's primary outcome demonstrated that the novel surgical approach involving hollow pedicle screw-anchored bone cement combined with posterior LSF significantly improved pain and functionality in patients with Stage III Kümmell's disease. Key

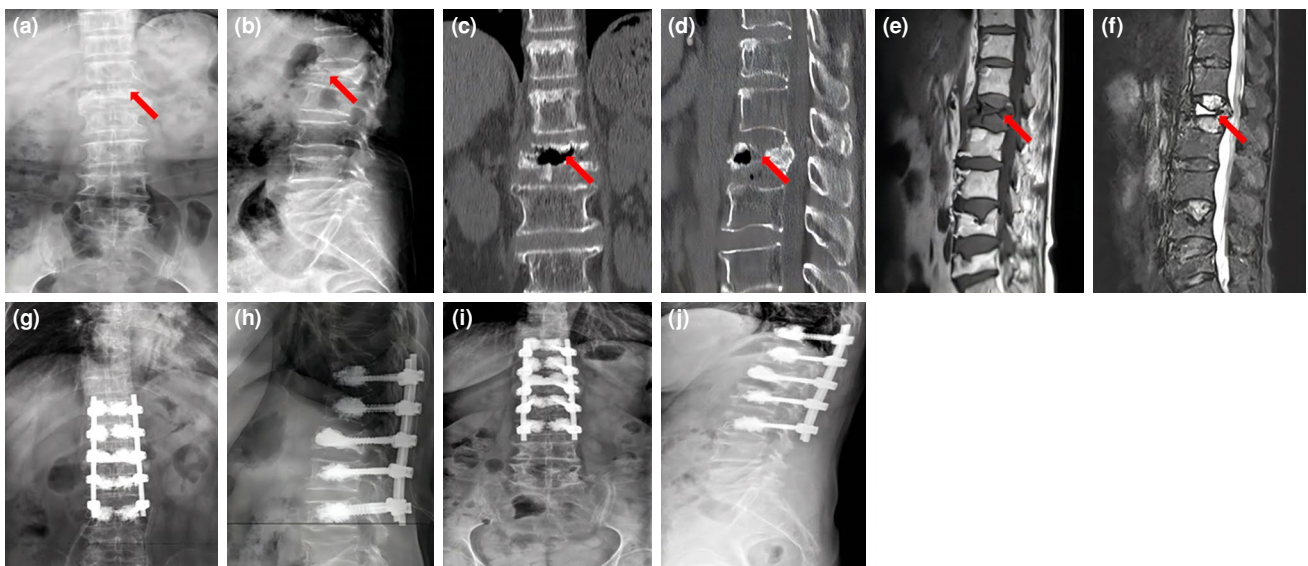


FIGURE 1. A 64-year-old female patient who underwent hollow pedicle screw-anchored bone cement combined with posterior LSF for L1 Kümmell's disease. (a, b) Preoperative sagittal and coronal radiographs showing a severely collapsed vertebra and kyphotic deformity. (c, d) Preoperative sagittal and coronal CT scan demonstrating the intervertebral cleft and breakage of the posterior cortex in the L1 vertebra. (e, f) Preoperative T1-weighted magnetic resonance imaging showing a low signal of fluid and gas in the injured vertebra, spinal cord compression, and T2-weighted fat-suppression images showing a high signal. (g, h) Early postoperative radiographs demonstrating restoration of the vertebral height and the kyphosis. (i, j) Radiographs showing no significant loss of vertebral height, no recurrence of kyphosis, good positioning of the injured vertebral cement, and no loosening or fracture of the internal fixation at the last follow-up visit.

LSF: Long-segment fixation; CT: Computed tomography.

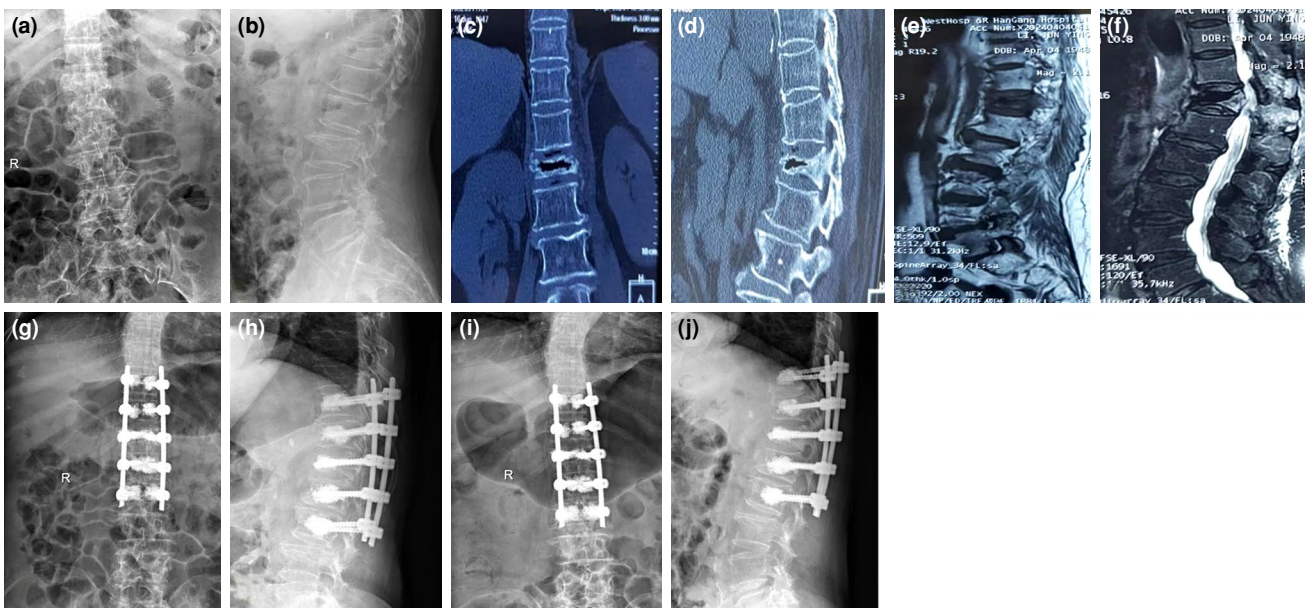


FIGURE 2. A 76-year-old female patient who underwent hollow pedicle screw-anchored bone cement combined with posterior LSF for T12 Kümmell's disease. (a, b) Preoperative radiographs showing a severely collapsed T12 vertebra and kyphotic deformity. (c, d) Preoperative coronal and sagittal CT scans showing a wedge-shaped change in the T12 vertebral body with interruption of the bony structure and a translucent line shadow. (e, f) Preoperative T1-weighted magnetic resonance imaging demonstrating a low signal in the injured vertebra and spinal cord compression, and T2-weighted fat-suppression images showing a high signal. (g, h) Early postoperative radiographs. (i, j) Radiographs showing no significant loss of vertebral height, no recurrence of kyphosis, good positioning of the injured vertebral cement, and no loosening or fracture of the internal fixation at the last follow-up visit. LSF: Long-segment fixation; CT: Computed tomography.

findings were marked reductions in VAS and ODI scores, indicating effective pain management and enhanced daily living activities. Additionally, we observed substantial structural restoration with maintained vertebral integrity and corrected spinal deformity, alongside a favorable safety profile characterized by low complication rates and improved neurological functions in affected patients. These results underscore the technique's potential as a viable and effective treatment option, highlighting its operational efficiency and minimal invasiveness compared to traditional surgical methods.

Following the accelerated speed of the aging population, the number of patients with osteoporotic fractures, particularly osteoporotic spinal fractures, is increasing yearly,^[1,16,17] and the number of patients with Kümmell's disease is also increasing. According to clinical symptoms and imaging, Li et al.^[14] divided Kümmell's disease into three stages as follows: Stage I, vertebral body height loss <20% with or without adjacent disc degeneration; Stage II, vertebral body height loss ≥20% with adjacent disc degeneration; Stage III, posterior cortical rupture resulting in spinal cord compression with or without spinal cord injury.

In general, conservative treatment of Kümmell's disease is typically less effective and carries the risk of delayed vertebral collapse and neurological dysfunction, and most surgeons recommend that Kümmell's disease be treated by surgical intervention.^[18] For Stages I and II, the role of percutaneous vertebroplasty and percutaneous kyphoplasty in achieving pain relief, restoring vertebral body height, and correcting deformity has been widely accepted.^[6,18] However, the treatment of Stage III Kümmell's disease has been controversial.^[18] Although many procedures have been developed to treat this condition, including anterior-only, posterior-only, and combined anterior and posterior procedures,^[8,9] they are technically demanding and potentially dangerous in elderly patients. For patients with Stage III Kümmell's disease with mild spinal stenosis and no neurological symptoms, the goals are to relieve back pain, prevent further collapse of the affected vertebrae, and delay neurological dysfunction. In this study, we used a relatively less invasive surgical approach, applying a hollow screw-anchored cement technique to stabilize the anterior column and long-segment posterior instrumentation to stabilize the spine. The results showed that hollow pedicle screw-anchored

bone cement combined with posterior LSF could significantly relieve back pain, recover the height of the affected vertebra, correct kyphosis deformity, and promote the recovery of neurological function.

Intravertebral vacuum cleft (IVC) is a characteristic imaging feature of Kümmell's disease. On coronal plane CT, it is generally located in the middle of the vertebral body or adjacent to the compression endplate, and on sagittal plane CT, it is mostly located on the anterior edge of the vertebral body.^[19] In Kümmell's disease, vertebral bone defects are commonly detected in clinical practice. Pathology has confirmed the IVC as a dead space composed of necrotic bone tissue. After being filled with bone cement, it is difficult for the bone cement to penetrate the normal trabecular structure, that is, the bone cement does not combine with the surrounding bone tissue, which is an important cause of bone cement dislodgement.^[20,21] Tsai et al.^[22] suggested that polymethylmethacrylate cement in vertebroplasty is merely a space-occupying material without mechanical interlocking ability or biocompatibility and, accordingly, has the potential for dislodgement. Hollow pedicle screws are used to interlock the bone cement and the surrounding bone tissue in an attempt to avoid bone cement displacement during or after surgery. The key technology in this is that after the hollow pedicle screw of the fractured vertebra is inserted into the IVC, the bone cement is slowly released through the lateral hole at the front of the screw, and the IVC is filled during the injection, creating better integration between the cement and the screw. Thus, the hollow pedicle screw acts as a bridge, allowing the bone cement to interlock with the surrounding bone tissue, even to the pedicle, which is the hardest part of the vertebral body.

We believe that stabilization of the spine by posterior long-segment bone cement pedicle screws is another important factor for the satisfactory results of our surgeries. Due to the characteristics of Kümmell's disease (which mostly occurs in the thoracolumbar spine), in cases where significant weight-bearing and easy instability may be present, it is important to reasonably select the spinal segment to be fixed to obtain stronger internal fixation. At present, there are no studies on the comparative treatment of Stage III Kümmell's disease using vertebroplasty combined with posterior LSF *vs.* short-segment fixation. Although short-segment posterior devices have been widely used and allow the preservation of more motor segments, implant failure and the progression of kyphosis have been noted in long-term follow-ups.^[23-25]

Verlaan^[26] concluded that the complication rate of posterior short-segment fixation is as high as 21% (e.g., vertebral body collapse and loosening of internal fixation). Conversely, there was no internal fixation failure in the LSF group in the present study. The reason for this difference may be related to the poor local stability and poor axial load-bearing capacity of short-segment fixation. A meta-analysis concluded that LSF could better maintain the long-term stability of kyphosis.^[27] In addition, the lower bone density of the spine in patients with Kümmell's disease also requires a higher intensity of instrumentation fixation.^[28,29] Taking these factors into account, we used LSF to stabilize the spine after cement injection into the vertebrae.^[30] We used bone cement-augmented screws in all patients with insufficient bone mass because this method promotes a strong bond between the screw and the vertebral body, thus preventing screw loosening and implant failure.^[31,32] Consistent with our approach, Mo et al.^[5] also demonstrated that bone cement-augmented pedicle screw fixation was a safe and effective treatment for Stage III Kümmell's disease and could effectively correct kyphosis, restore and maintain sagittal balance, and maintain spinal stability.

This study had some limitations. First, this was a retrospective, single-center study with a limited sample size and a short follow-up period, which may have influenced the results. Second, since we did not include a control group in this study, possibly introducing selection bias. A prospective, randomized controlled study is needed to further validate the effectiveness of the procedure.

In conclusion, hollow pedicle screw-anchored bone cement combined with posterior LSF represents a safe and effective surgery for patients with Stage III Kümmell's disease. Satisfactory kyphosis and vertebral height correction can be achieved using this technique, providing pain relief and improved neurological function with few complications. However, further evaluation is needed for long-term clinical outcomes and the radiological results of this minimally invasive method.

Data Sharing Statement: The data that support the findings of this study are available from the corresponding author upon reasonable request.

Author Contributions: Conception and design of the work, supervision, drafting the manuscript: D.K.; Data collection, analysis and interpretation of the data: J.W., G.Q., Y.C., D.H.; Statistical analysis: D.K., D.H. Critical revision of the manuscript: all authors. Approval of the final manuscript: all authors.

Conflict of Interest: The authors declared no conflicts of interest with respect to the authorship and/or publication of this article.

Funding: The authors received no financial support for the research and/or authorship of this article.

REFERENCES

- Guo J, Bai Y, Li L, Wang J, Wang Y, Hao D, et al. A comparative study of 2 techniques to avoid bone cement loosening and displacement after percutaneous vertebroplasty treating unstable Kummell disease. *Neurospine* 2024;21:575-87. doi: 10.14245/ns.2347274.637.
- Kan DJ, Han DP, Wang JH, Wang LF, Shen Y. Efficacy and safety of high-viscosity bone cement in percutaneous vertebroplasty for Kummell's disease. *Indian J Orthop* 2024;58:575-86. doi: 10.1007/s43465-024-01133-3.
- Chen J, Luo A, Wang C. The use of spiral cement injector for percutaneous vertebroplasty to treat Kummell disease: A retrospective study. *World Neurosurg* 2024;186:e235-42. doi: 10.1016/j.wneu.2024.03.116.
- Ning Y, Li Z, Huang J, Xu S, Wang Q, Yan J, et al. Comparison of the clinical efficacy and bone cement distribution difference between Kummell's disease and osteoporotic vertebral compression fracture after percutaneous kyphoplasty. *Pain Physician* 2024;27:E327-36.
- Mo GY, Zhou TP, Guo HZ, Li YX, Tang YC, Guo DQ, et al. Long-term efficacy and safety of bone cement-augmented pedicle screw fixation for stage III Kummell disease. *Sci Rep* 2021;11:13647. doi: 10.1038/s41598-021-93013-1.
- Lu W, Wang L, Xie C, Teng Z, Han G, Shi R, et al. Analysis of percutaneous kyphoplasty or short-segmental fixation combined with vertebroplasty in the treatment of Kummell disease. *J Orthop Surg Res* 2019;14:311. doi: 10.1186/s13018-019-1358-8.
- Wang R, Hao Y, Chen M, Jia P, Zhou F. Comparison of the clinical outcomes of vesselplasty vs. percutaneous vertebroplasty for the treatment of neurologically intact osteoporotic Kummell's disease: A retrospective study. *Calcif Tissue Int* 2024;114:360-7. doi: 10.1007/s00223-024-01186-4.
- Kang H, Wei T, Zeng W, Lan S. Treatment of kyphotic deformity in Kummell's disease through vertebral body screw fixation and intertransverse process grafting: A case report. *Medicine (Baltimore)* 2024;103:e37058. doi: 10.1097/MD.00000000000037058.
- Song KS, Yoon BI, Ham DW. Transpedicular intravertebral cage augmentation using expandable cage in Kummell disease: Technical note and case series. *World Neurosurg* 2024;184:119-24. doi: 10.1016/j.wneu.2024.01.079.
- Guo X, Qiu Y, Liu X, Teng H, Hu H. Percutaneous short segmental fixation combined with bone cement augmentation for stage III Kummell's disease without nerve deformity. *Medicine (Baltimore)* 2024;103:e37087. doi: 10.1097/MD.00000000000037087.
- Xu H, Feng Q, Ma X, Lan J, Ji J, Zhang Z, et al. Biomechanical behaviour of a novel bone cement screw in the minimally invasive treatment of Kummell's disease: A finite element study. *BMC Musculoskelet Disord* 2023;24:967. doi: 10.1186/s12891-023-07090-6.
- Zhong S, Bao F, Fan Q, Zhao Y, Li W. Prevention of bone cement displacement in Kummell disease without neurological deficits through treatment with a novel hollow pedicle screw combined with kyphoplasty. *Orthop Surg* 2023;15:2515-22. doi: 10.1111/os.13815.
- Deng H, Li Y, Zhou J, Wang X, Du J, Gao W, et al. Therapeutic efficacy of transpedicular intracorporeal cement augmentation with short segmental posterior instrumentation in treating osteonecrosis of the vertebral body: A retrospective case series with a minimum 5-year follow-up. *BMC Musculoskelet Disord* 2019;20:305. doi: 10.1186/s12891-019-2671-4.
- Li KC, Li AF, Hsieh CH, Liao TH, Chen CH. Another option to treat Kummell's disease with cord compression. *Eur Spine J* 2007;16:1479-87. doi: 10.1007/s00586-006-0094-z.
- Gao A, Li JY, Shao R, Wu TX, Wang YQ, Liu XG, et al. Schroth exercises improve health-related quality of life and radiographic parameters in adolescent idiopathic scoliosis patients. *Chin Med J (Engl)* 2021;134:2589-96. doi: 10.1097/CM9.0000000000001799.
- Zhang T, Peng Y, Li J. Comparison of clinical and radiological outcomes of vertebral body stenting versus percutaneous kyphoplasty for the treatment of osteoporotic vertebral compression fracture: A systematic review and meta-analysis. *Jt Dis Relat Surg* 2024;35:218-30. doi: 10.52312/jdrs.2023.1356.
- Sun Y, Li X, Ma S, Chong H, Cai TC, Li KM, et al. Comparison of the efficacy and safety of unilateral and bilateral approach kyphoplasty in the treatment of osteoporotic vertebral compression fractures: A meta-analysis. *Jt Dis Relat Surg* 2024;35:491-503. doi: 10.52312/jdrs.2024.1701.
- Zhu Y, Zhang Z, Jiang W, Su K, Wang Z, Wang C, et al. Therapeutic efficacy of transpedicular impaction bone grafting with long segmental posterior instrumentation in stage III Kummell disease. *Spine (Phila Pa 1976)* 2021;46:907-14. doi: 10.1097/BRS.0000000000003995.
- Yu CW, Hsu CY, Shih TT, Chen BB, Fu CJ. Vertebral osteonecrosis: MR imaging findings and related changes on adjacent levels. *AJNR Am J Neuroradiol* 2007;28:42-7.
- Nagad P, Rawall S, Kundnani V, Mohan K, Patil SS, Nene A. Postvertebroplasty instability. *J Neurosurg Spine* 2012;16:387-93. doi: 10.3171/2011.12.SPINE11671.
- Jeong YH, Lee CJ, Yeon JT, Bae J, Choi E, Lee PB, et al. Insufficient penetration of bone cement into the trabecular bone: A potential risk for delayed bone cement displacement after kyphoplasty? *Reg Anesth Pain Med* 2016;41:616-8. doi: 10.1097/AAP.0000000000000445.
- Tsai TT, Chen WJ, Lai PL, Chen LH, Niu CC, Fu TS, et al. Polymethylmethacrylate cement dislodgment following percutaneous vertebroplasty: A case report. *Spine (Phila Pa 1976)* 2003;28:E457-60. doi: 10.1097/01.BRS.0000096668.54378.25.
- Alanay A, Acaroglu E, Yazici M, Oznur A, Surat A. Short-segment pedicle instrumentation of thoracolumbar burst fractures: Does transpedicular intracorporeal grafting prevent early failure? *Spine (Phila Pa 1976)* 2001;26:213-7. doi: 10.1097/00007632-200101150-00017.
- Ma Y, Li X, Dong J. Is it useful to apply transpedicular intracorporeal bone grafting to unstable thoracolumbar fractures? A systematic review. *Acta Neurochir (Wien)* 2012;154:2205-13. doi: 10.1007/s00701-012-1518-7.
- Sheng X, Ren S. Surgical techniques for osteoporotic vertebral collapse with delayed neurological deficits: A systematic review. *Int J Surg* 2016;33 Pt A:42-8. doi: 10.1016/j.ijsu.2016.07.050.

26. Verlaan JJ. Stabilizing osteoporotic thoracolumbar fractures through an anterior or posterior approach: What works best? *Spine J* 2013;13:1733-5. doi: 10.1016/j.spinee.2013.07.029.
27. Yu Y, Zeng H, Guo E, Tang B, Fang Y, Wu L, et al. Efficacy and safety of posterior long-segment fixation versus posterior short-segment fixation for Kummell disease: A meta-analysis. *Geriatr Orthop Surg Rehabil* 2022;13:21514593221107509. doi: 10.1177/21514593221107509.
28. Sudo H, Ito M, Kaneda K, Abumi K, Kotani Y, Nagahama K, et al. Anterior decompression and strut graft versus posterior decompression and pedicle screw fixation with vertebroplasty for osteoporotic thoracolumbar vertebral collapse with neurologic deficits. *Spine J* 2013;13:1726-32. doi: 10.1016/j.spinee.2013.05.041.
29. Kim KT, Suk KS, Kim JM, Lee SH. Delayed vertebral collapse with neurological deficits secondary to osteoporosis. *Int Orthop* 2003;27:65-9. doi: 10.1007/s00264-002-0418-5.
30. Atik OŞ. Writing for Joint Diseases and Related Surgery (JDRS): There is something new and interesting in this article! *Jt Dis Relat Surg* 2023;34:533. doi: 10.52312/jdrs.2023.57916.
31. Girardo M, Rava A, Fusini F, Gargiulo G, Coniglio A, Cinnella P. Different pedicle osteosynthesis for thoracolumbar vertebral fractures in elderly patients. *Eur Spine J* 2018;27(Suppl 2):198-205. doi: 10.1007/s00586-018-5624-y.
32. Weiser L, Sellenschloh K, Püschel K, Morlock MM, Viezens L, Lehmann W, et al. Reduced cement volume does not affect screw stability in augmented pedicle screws. *Eur Spine J* 2020;29:1297-303. doi: 10.1007/s00586-020-06376-w.