



# Correlations of spinopelvic parameters with quality of life of patients with adult degenerative scoliosis after posterior correction

Fangfang Shi, MD<sup>1</sup>, Chen Xia, MD<sup>2</sup>, Jun Zhang, MD<sup>2</sup>, Chuyong Chen, MD<sup>2</sup>, Qi Chen, MD<sup>2</sup>

<sup>1</sup>Department of Hematology, Zhejiang Provincial People's Hospital, People's Hospital of Hangzhou Medical College, Hangzhou, China

<sup>2</sup>Department of Orthopedics, Zhejiang Provincial People's Hospital, People's Hospital of Hangzhou Medical College, Hangzhou, China

Adult degenerative scoliosis (ADS) refers to the scoliosis deformity of more than 10° after maturity of bones in the coronal sequence in children and adolescents without scoliosis.<sup>[1]</sup> Adult degenerative scoliosis can cause severe low back pain, root pain, intermittent claudication, and obvious trunk tilt.<sup>[2]</sup> It is common in patients aged >40 years, and its incidence rate (about 6 to 68%) increases with age.<sup>[3]</sup> Adult degenerative scoliosis is commonly treated by simple decompression, fixation and fusion after decompression, and posterior osteotomy for correction.

Among these methods, posterior osteotomy for correction can greatly reduce the damage to the facet joint, reconstruct the stability of the spine in a short time, and prevent the progression of scoliosis.<sup>[4]</sup> For instance, Kasten et al.<sup>[5]</sup>

Received: October 19, 2022

Accepted: June 25, 2024

Published online: August 14, 2024

**Correspondence:** Qi Chen, MD. Department of Orthopedics, Zhejiang Provincial People's Hospital, People's Hospital of Hangzhou Medical College, Hangzhou 310014, China.

E-mail: chenqizpph@zcxecl.com

Doi: 10.52312/jdrs.2024.891

**Citation:** Shi F, Xia C, Zhang J, Chen C, Chen Q. Correlations of spinopelvic parameters with quality of life of patients with adult degenerative scoliosis after posterior correction. *Jt Dis Relat Surg* 2024;35(3):554-561. doi: 10.52312/jdrs.2024.891.

©2024 All right reserved by the Turkish Joint Diseases Foundation

This is an open access article under the terms of the Creative Commons Attribution-NonCommercial License, which permits use, distribution and reproduction in any medium, provided the original work is properly cited and is not used for commercial purposes (<http://creativecommons.org/licenses/by-nc/4.0/>).

## ABSTRACT

**Objectives:** This study aimed to investigate the correlations of spinopelvic parameters with the quality of life of patients with adult degenerative scoliosis (ADS) after posterior correction, and their relationships with efficacy.

**Patients and methods:** Ninety patients (40 females, 50 males; mean age: 62.4±3.3 years; range, 47 to 73 years) with adult spinal deformity treated from March 2016 to May 2020 were retrospectively enrolled. The Scoliosis Research Society (SRS)-22 questionnaire was filled in by the patients, and the Oswestry disability index (ODI) and Visual Analog Scale (VAS) for back and lower limb pain were assessed. All the patients underwent posterior correction. Spearman's analysis was conducted for the correlations of the spinopelvic sagittal parameters with quality of life. The risk factors for efficacy were identified using the multivariate logistic regression model to construct a nomogram model for efficacy and risk prediction.

**Results:** After the operation, significant reductions were detected in the sagittal vertical axis (SVA), pelvic tilt (PT), T1 pelvic angle (TPA), pelvic incidence minus lumbar lordosis (PI-LL), and the ODI score ( $p<0.05$ ). The SVA and LL were significantly negatively correlated with all subitems on the SRS-22 questionnaire but positively correlated with VAS scores for back pain ( $p<0.05$ ). Thoracic kyphosis was significantly positively correlated with self-image and mental status on the SRS-22 questionnaire ( $p<0.05$ ), while TPA was negatively correlated with pain and self-image ( $p<0.05$ ). The PI-LL was significantly negatively correlated with pain ( $p<0.05$ ).

**Conclusion:** The SVA, LL, PT, and PI-LL were independent predictors of improvement in ODI after operation for ADS. The postoperative changes in spinopelvic parameters affected the clinical outcomes in patients with ADS.

**Keywords:** Degenerative scoliosis, posterior correction, quality of life, spinopelvic parameter, therapeutic effect.

followed up 78 cases for at least two years and found that scoliosis was corrected by posterior osteotomy from an median of 61° (range: 41 to 105) preoperatively to an median of 30° (range: 3 to 47) postoperatively,

thereby reducing the incidence rate of postoperative pseudarthrosis. In another study, after posterior correction, the Visual Analog Scale (VAS) score for lower limb pain reduced from 6.5 to 2.0 points, the VAS score for back pain decreased from 7.83 to 2.67 points, and the Oswestry disability index (ODI) dropped from 22.2 to 10.5%.<sup>[6]</sup>

Unlike previous studies, which have often focused on the general outcomes of spinal surgeries, our study delved into the specific correlations between these parameters and surgical efficacy. By identifying these correlations, we aimed to develop a more reasonable and individualized correction program.

## PATIENTS AND METHODS

In this retrospective study, the data of 90 patients (40 females, 50 males; mean age:  $62.4 \pm 3.3$  years; range, 47 to 73 years) with adult spinal deformity treated in the Zhejiang Provincial People's Hospital, People's Hospital of Hangzhou Medical College from March 2016 to May 2020 were analyzed. The following patients were eligible: (i) those aged  $>60$  years old; (ii) those with either scoliosis  $>20^\circ$  and sagittal vertical axis (SVA)  $>5$  cm or pelvic tilt (PT)  $>25^\circ$  and scoliotic Cobb angle  $>30^\circ$ ; (iii) those with three or more segments to experience fusion and fixation; (iv) those with anteroposterior and lateral radiographs of the whole spine in the standing position; (v) those who completely filled in the Scoliosis Research Society (SRS)-22 questionnaire, the ODI, and VAS for back and lower limb pain for the evaluation of the quality of life of patients with spinal deformity. The following patients were excluded: (i) those with a history of spinal surgery; (ii) those with neurodegenerative diseases or pain; (iii) those with other severe systemic diseases; (iv) those with scoliosis  $<20^\circ$  before operation; (v) those with three segments of fixation and fusion during operation.

After general anesthesia, the patient was placed in the prone position. A posterior midline incision was made, and the spinous process, lamina of the vertebra, facet joint, and transverse process of the segment to be fused were exposed layer by layer according to the preoperatively developed fusion range. After the fusion segments were pinpointed by C-arm fluoroscopy, drilling and plumbing were carried out, and a pedicle screw of appropriate length and diameter was inserted into the S1 and above vertebrae using the free-hand method. Additionally, S2 alar-iliac screws were implanted for patients who needed to undergo fusion at the S2

vertebrae under O-arm navigation. Transforaminal interbody fusion was performed on the convex side of the distal lumbosacral curve (at the L4/5 or L5/S1 intervertebral space). The lumbosacral compensatory curve was fully released from the convex side to the concave side, and then, the cage was placed on the concave side as a fulcrum, and the convex side was pressed and held tightly to reduce the tilt of the L4 and L5 vertebrae, achieve the horizontalization of lumbosacral fusion vertebra, and promote the postoperative lumbosacral fusion. Total laminectomy and decompression were performed simultaneously for those with lumbar spinal stenosis. Multisegmental Smith-Petersen osteotomy or transpedicular vertebral osteotomy in the apical region was conducted for patients according to the severity of kyphosis. Upon osteotomy, an orthopedic rod was placed on both sides, and the osteotomy area was compression-closed gradually. Afterward, bone graft fusion was performed with autologous bone or allogeneic bone. Following intubation and drainage, the incision was closed layer by layer. All operations were carried out under the close monitoring of a nerve monitor.

Picture archiving communication system was employed to measure the imaging parameters before operation and at 3 months after operation, including (i) SVA; (ii) thoracic kyphosis (TK): T4-12 Cobb angles; (iii) Cobb angles of the proximal superior endplate and distal inferior endplate of the spinal segment with scoliosis on the anteroposterior lumbar X-ray film; (iv) lumbar lordosis (LL): the Cobb angle between L1/S1 superior endplates on the lateral lumbar X-ray film; (v) sacral slope (SS): the angle between the S1 superior endplate and horizontal line on the lateral lumbar X-ray film; (vi) PT: the angle between the mid-perpendicular and the line connecting the midpoint of the connection line between the centers of bilateral femoral heads with the center of the S1 superior endplate; (vii) pelvic incidence (PI); (viii) T1 pelvic angle (TPA): the angle between the connection line of the midpoints of T1 pelvis and the line connecting the centers of both femoral heads and the connection line between the midpoint of S1 superior endplate and that of the line connecting the centers of both femoral heads. All imaging parameters were measured independently by two doctors and averaged for analysis.

All the patients filled in the simplified Chinese version of the SRS-22 questionnaire before the operation and three months after the operation in a quiet environment. The questionnaire consisted of 22 questions in five dimensions, including functional status, pain, self-image, mental status, and satisfaction

with treatment. Each question was given 1 to 5 points: 1 point for the worst, and 5 points for the best. The scores for each dimension were obtained by totaling those for the corresponding questions, and the total score of the SRS-22 questionnaire was the sum of all the scores for all questions. Furthermore, the ODI and VAS were used to evaluate pain in the back and lower limbs in patients with spinal deformity.

### Statistical analysis

Data were analyzed using IBM SPSS version 19.0 software (IBM Corp., Armonk, NY, USA). Normal distribution was confirmed using the Shapiro-Wilk test. Normally distributed measurement data were displayed as mean  $\pm$  standard deviation (SD) and compared using the paired t-test. Spearman's correlation analysis was conducted, and a multivariate logistic regression model was used to analyze the risk factors affecting efficacy, aiming to construct a nomogram model for efficacy and risk prediction. The accuracy of the model was assessed through the Hosmer-Lemeshow goodness-of-fit test and calibration curve, and decision curve analysis

was used to evaluate its clinical practicability. A two-tailed  $p$ -value  $<0.05$  was considered statistically significant.

## RESULTS

The mean body mass index was  $24.57\pm 0.82$  kg/m<sup>2</sup>, and there were  $62\pm 19$  segments of fixation and fusion and  $2.21\pm 0.67$  segments of decompression. The mean operation time was  $225.25\pm 36.81$  min, the mean amount of intraoperative bleeding was  $12,365.35\pm 461.27$  mL, and the mean length of hospital stay was  $14.26\pm 3.42$  days.

The comparison results of spinopelvic sagittal parameters before and after the operation are shown in Table I. Except for PI, the other parameters were significantly different before and after the operation ( $p<0.05$ ). Among them, SVA, PT, TPA, and PI minus LL (PI-LL) declined significantly, while TK, LL, and SS rose significantly, illustrating that the operation improved the spinopelvic sagittal parameters.

The results of the clinical efficacy assessment indicators before and after the operation are described in Table II. Significant differences were

TABLE I

Spinopelvic sagittal parameters before and after the operation

Observation time	n	SVA (mm)	TK (°)	LL (°)	PI (°)	PT (°)	SS (°)	TPA (°)	PI-LL (°)
		Mean $\pm$ SD	Mean $\pm$ SD	Mean $\pm$ SD	Mean $\pm$ SD	Mean $\pm$ SD	Mean $\pm$ SD	Mean $\pm$ SD	Mean $\pm$ SD
Before operation	90	7.45 $\pm$ 1.28	11.96 $\pm$ 3.15	17.67 $\pm$ 4.59	46.75 $\pm$ 10.14	31.12 $\pm$ 5.64	33.77 $\pm$ 9.42	28.90 $\pm$ 6.42	37.12 $\pm$ 8.01
After operation	90	3.02 $\pm$ 0.52	14.68 $\pm$ 3.86	25.07 $\pm$ 2.92	45.61 $\pm$ 10.11	20.36 $\pm$ 4.28	39.16 $\pm$ 10.68	19.38 $\pm$ 4.98	19.82 $\pm$ 4.25
t		30.419	5.179	3.602	0.755	14.418	3.591	11.116	18.100
p		<0.001	<0.001	<0.001	0.451	<0.001	<0.001	<0.001	<0.001

SVA: Sagittal vertical axis; TK: Thoracic kyphosis; LL: Lumbar lordosis; PI: Pelvic incidence; PT: Pelvic tilt; SS: Sacral slope; TPA: T<sub>1</sub> pelvic angle; PI-LL: Pelvic incidence minus lumbar lordosis; SD: Standard deviation.

TABLE II

Quality of life assessment parameters before and after the operation

Time	SRS-22 score						
	Functional status	Pain	Self-image	Mental status	ODI score	VAS score for pain in the back	VAS score for pain in the lower limbs
	Mean $\pm$ SD	Mean $\pm$ SD	Mean $\pm$ SD	Mean $\pm$ SD	Mean $\pm$ SD	Mean $\pm$ SD	Mean $\pm$ SD
Before operation	14.00 $\pm$ 2.35	15.90 $\pm$ 4.14	15.34 $\pm$ 4.03	18.26 $\pm$ 3.92	65.85 $\pm$ 10.02	7.37 $\pm$ 1.87	6.42 $\pm$ 1.52
After operation	24.19 $\pm$ 4.03	21.73 $\pm$ 4.59	24.75 $\pm$ 6.27	24.19 $\pm$ 5.15	28.02 $\pm$ 6.26	3.28 $\pm$ 1.27	3.95 $\pm$ 1.34
t	20.722	8.948	11.977	8.692	30.376	17.165	11.564
p	<0.001	<0.001	<0.001	<0.001	<0.001	<0.001	<0.001

SRS: Scoliosis Research Society-22; ODI: Oswestry disability index; VAS: Visual Analog Scale; SD: Standard deviation.

found in the changes in the clinical efficacy assessment indicators ( $p < 0.05$ ). The functional status, pain, self-image, and mental status on the SRS-22 questionnaire were significantly increased, while the ODI score and VAS scores for pain in the back and lower limbs were significantly decreased, indicating that the clinical symptoms of patients significantly improved after the operation.

The correlations of postoperative spinopelvic parameters with the SRS-22 score and VAS scores for pain in the back and the lower limbs are shown in Table III. The SVA and LL were significantly negatively correlated with all the subitems on the SRS-22 questionnaire but significantly positively correlated with VAS scores for pain in the back ( $p < 0.05$ ). Thoracic kyphosis was significantly positively

correlated with self-image and mental status on the SRS-22 questionnaire ( $p < 0.05$ ), TPA was significantly negatively correlated with pain and self-image on the SRS-22 questionnaire ( $p < 0.05$ ), and PI-LL was also significantly negatively correlated with pain on the SRS-22 questionnaire ( $p < 0.05$ ). Moreover, PT, TPA, and PI-LL were significantly positively correlated with VAS scores for back pain ( $p < 0.05$ ), whereas PI and SS had no significant correlations with all scores ( $p > 0.05$ ). All spinopelvic parameters were not significantly correlated with the VAS score for pain in the lower limbs ( $p > 0.05$ ).

Logistic regression analysis was performed with the postoperative ODI score as the dependent variable and the SVA, TK, LL, PI, PT, SS, TPA, and PI-LL, univariate variables with differences,

**TABLE III**  
Correlations of postoperative spinopelvic parameters with quality of life

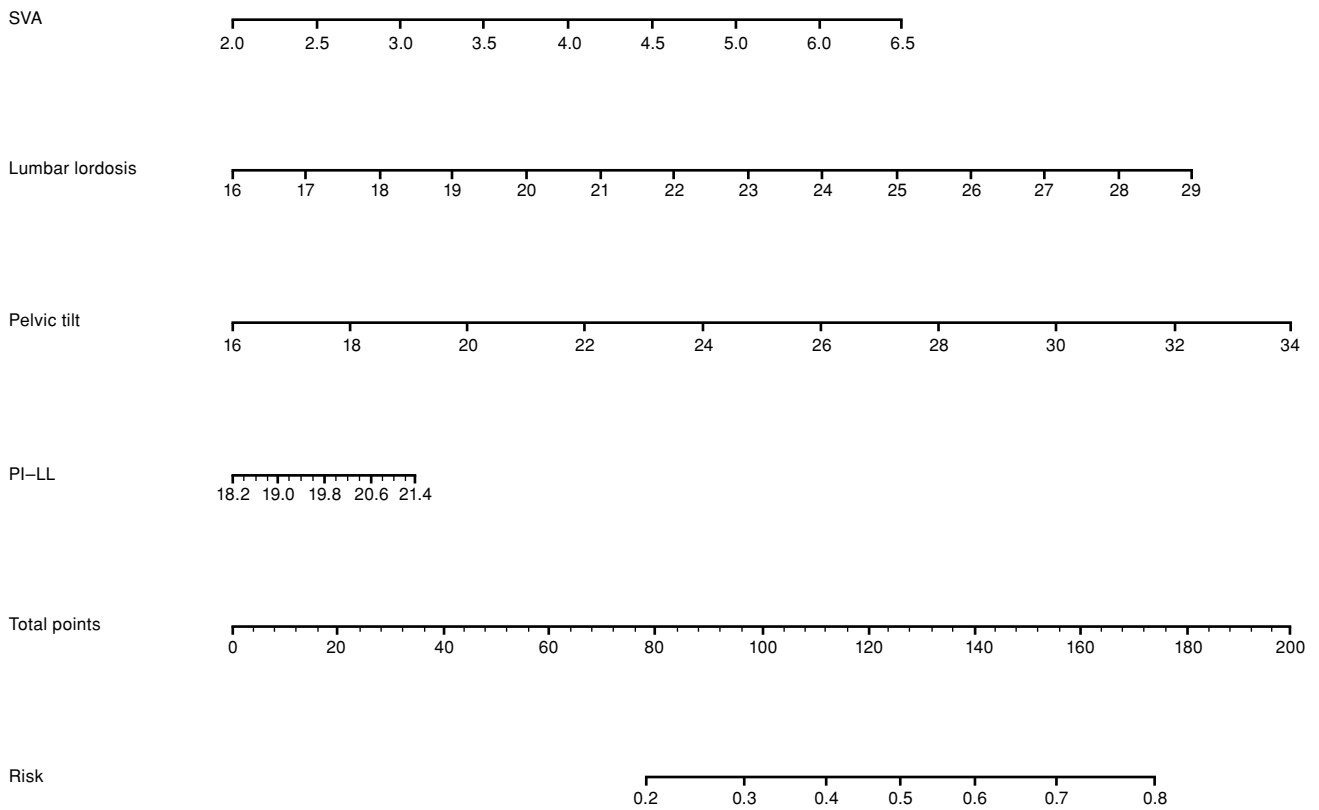
Time	SRS-22 score											
	Functional status		Pain		Self-image		Mental status		VAS score for pain in the back		VAS score for pain in the lower limbs	
	r	p	r	p	r	p	r	p	r	p	r	p
SVA	-0.680	0.003	-0.535	0.021	-0.558	0.011	-0.401	0.028	0.629	0.006	0.411	0.067
TK	0.021	0.203	0.106	0.191	0.662	0.004	0.382	0.030	-0.327	0.080	-0.046	0.200
LL	-0.578	0.009	-0.629	0.007	-0.458	0.024	-0.359	0.031	0.442	0.024	0.236	0.115
PI	-0.223	0.128	-0.155	0.159	-0.114	0.183	-0.215	0.148	0.104	0.194	0.123	0.177
PT	-0.293	0.094	-0.221	0.130	-0.072	0.199	-0.231	0.117	0.482	0.023	0.458	0.062
SS	0.363	0.071	0.191	0.156	0.250	0.109	0.239	0.114	-0.284	0.097	-0.319	0.084
TPA	-0.378	0.068	-0.572	0.011	-0.574	0.010	-0.089	0.196	0.437	0.026	0.228	0.124
PI-LL	-0.117	0.182	-0.568	0.012	-0.214	0.151	-0.252	0.106	0.428	0.027	0.167	0.157

SRS: Scoliosis Research Society-22.

**TABLE IV**  
Multivariate logistic regression analysis results of improvement in ODI after operation for ADS

	Regression coefficient beta	Regression coefficient SE	Wald value	p	OR	95% CI
SVA	1.678	0.598	8.827	0.006	3.125	2.635-7.158
TK	-0.362	0.340	3.766	0.182	0.851	0.274-1.873
LL	-1.331	0.320	3.936	0.012	2.425	1.287-2.863
PI	1.147	0.620	9.536	0.102	0.828	0.521-3.549
PT	1.299	0.429	3.270	0.035	2.225	1.325-2.965
SS	-0.169	0.235	5.386	0.241	1.118	0.138-1.782
TPA	3.726	0.746	11.218	0.086	3.519	0.405-6.327
PI-LL	1.568	0.263	5.486	0.021	4.185	2.560-5.452

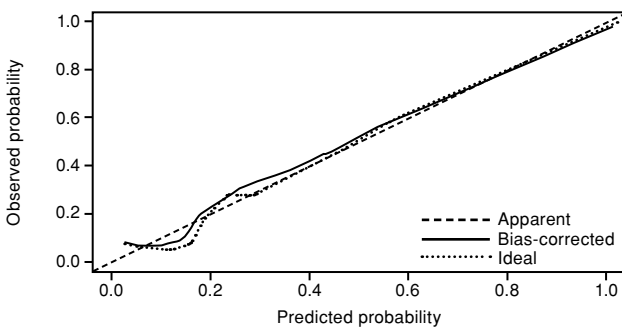
ODI: Oswestry disability index; SE: Standard error; ADS: Adult degenerative scoliosis; SE: Standard error; SVA: Sagittal vertical axis; TK: Thoracic kyphosis; LL: Lumbar lordosis; PI: Pelvic incidence; PT: Pelvic tilt; SS: Sacral slope; TPA: T<sub>1</sub> pelvic angle; PI-LL: Pelvic incidence minus lumbar lordosis.



**FIGURE 1.** Nomogram model for predicting improvement in ODI after operation for ADS. SVA: Sagittal vertical axis; PI-LL: Pelvic incidence minus lumbar lordosis; ODI: Oswestry disability index; ADS: Adult degenerative scoliosis.

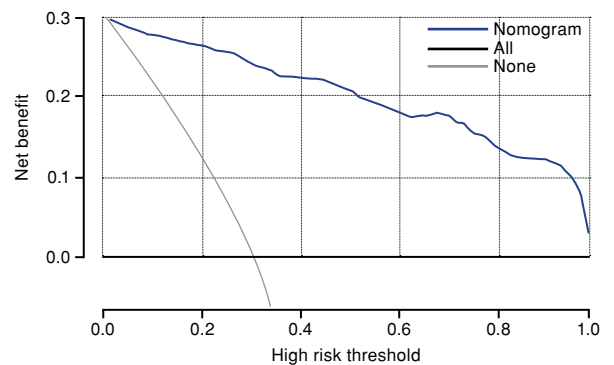
as the independent variables. After adjusting the confounding factors, the results showed that SVA, LL, PT, and PI-LL were the independent risk factors for the improvement in ODI after operation for ADS ( $p < 0.05$ ; Table IV).

The independent risk factors from the multivariate analysis were used to construct the prediction model of the improvement in ODI after operation for ADS (Figure 1). The higher the SVA, LL, PT, and PI-LL were, the more the ODI improved after operation for ADS.



**FIGURE 2.** Calibration curve of prediction model.

Figure 2 demonstrates the calibration curve of the nomogram model for predicting the improvement in ODI after operation for ADS. According to the results, the average deviation was 0.027, and the prediction probability had goodness of fit to the actual probability. The Hosmer-Lemeshow goodness-of-fit test showed no significant difference, with a high degree of calibration. The decision curve of the prediction model showed that the model was far away from the



**FIGURE 3.** Decision curve analysis chart of prediction model.



extreme curve (Figure 3). Moreover, it had a high net profit rate and was safe and reliable, as well as highly practicable.

## DISCUSSION

Adult degenerative scoliosis has surgical indications such as intractable low back pain or leg pain, aggravated scoliosis or nerve damage, and exacerbated coronal or sagittal imbalance. This study addressed a significant gap in the literature by linking spinopelvic parameters with surgical efficacy, thus paving the way for more effective and personalized treatment strategies in spinal correction surgery.<sup>[7]</sup> Scoliosis is at a greatly increased risk of progression in the presence of the coronal Cobb angle  $>30^\circ$ <sup>[8]</sup> and it often needs to be treated by surgery. Zhang et al.<sup>[9]</sup> proposed that posterior osteotomy was needed to achieve better treatment effect in patients with Cobb angles  $>30^\circ$  and coronal and sagittal imbalance. Spinopelvic parameters are vital for maintaining normal spinal biomechanical stability. Spinal deformity leads to the imbalance of spinopelvic parameters; thus, more energy is required for the human body to maintain stability, leading to degeneration and pain.<sup>[10]</sup>

In this study, a nomogram model was established to identify the influencing factors for the prediction of postoperative efficacy in patients with ADS. We found that SVA, LL, PT, and PI-LL were significantly correlated with the postoperative quality of life and served as the independent influencing factors for efficacy. Furthermore, SVA was closely correlated with the postoperative ODI score. The SVA directly affected the patients' self-image and self-satisfaction in the SRS-22 questionnaire. As an important parameter of sagittal balance in patients with ADS, SVA indicates sagittal imbalance when it exceeds  $>5$  cm.<sup>[11]</sup> Similarly, Takemoto et al.<sup>[12]</sup> found that SVA had a close relationship with the postoperative quality of life and efficacy, and the group with an SVA  $>50$  mm had significantly lower scores for quality of life and efficacy compared to the group with an SVA  $<50$  mm.

Reduction in LL causes lumbar paravertebral muscle stretch, and the function of the muscle system needs to be enhanced to maintain the stability of the spine. However, this is more likely to induce excessive muscle strain, and the decline in muscle support function aggravates spinal degeneration and produces adverse symptoms, affecting the quality of life.<sup>[13]</sup> In the present study, LL was closely correlated with the functional status,

pain, self-image, and mental status in the SRS-22 questionnaire, indicating that the improvement in LL can also help improve the lumbar activity and relieve lumbar pain. An ideal LL can be calculated by PI since it is an anatomically constant parameter, which is of guiding significance for the correction of LL.<sup>[14]</sup> Consistently, Yang et al.<sup>[15]</sup> concluded that the recovery of LL was most significant for improving the postoperative quality of life of patients with ASD. Additionally, Simon et al.<sup>[16]</sup> followed up 47 elderly patients for more than six years and found that posterior fixation exerted long-term effects on the correction of sagittal balance.

Pelvic parameters play an important role in maintaining the overall balance of the spine.<sup>[17]</sup> In this study, PT was closely correlated with both the efficacy and VAS scores, similar to the results of Protopsaltis et al.<sup>[18]</sup> Pelvic tilt changes along with intraoperative correction and fixation, and appropriately reducing PT can reduce the ODI score for the lower back and the VAS score for back pain.<sup>[19]</sup> Likewise, Eguchi et al.<sup>[20]</sup> reported that the decrease in PT led to the progression of scoliosis and increased the score for back pain. Therefore, in the process of correction, the pelvic parameters need to be reconstructed besides restoration of the sagittal balance.<sup>[7]</sup>

The PI-LL is a new index proposed by Schwab et al.<sup>[21]</sup> for evaluating spinal sagittal balance. A PI-LL  $>9^\circ$  implies that the sequences of the spine and pelvis are inconsistent, which is the basis of spinal imbalance and diseases. However, a smaller LL agrees more with the living habits of patients with degenerative scoliosis.<sup>[22]</sup> Moreover, patients with scoliosis can have more satisfactory clinical outcomes in the presence of a PI-LL of  $20^\circ$ . The results of this study indicated that patients with PI-LL  $>10^\circ$  had a better therapeutic response, probably because the limitation of low back movement after surgery resulted in dyskinesia when patients bent down. Similarly, Zhang et al.<sup>[23]</sup> found that the group with a PI-LL between  $10^\circ$  and  $20^\circ$  had the best postoperative quality of life. In addition, Ha et al.<sup>[24]</sup> reported that among all the parameters, PI-LL had the closest correlation with clinical efficacy.

In this study, we found that all the spinopelvic parameters were not correlated with lower limb pain, suggesting that the relief of lower limb pain required decompression according to the degree and segment of spinal stenosis. Moreover, spinopelvic parameters were more related to back pain and the resulting decline in quality of life. Patients with degenerative scoliosis have intervertebral disc and

facet degeneration at different segments.<sup>[25]</sup> At the level of biological anatomy, osteophytes are formed at the facet joints and vertebral endplates, and together with the hypertrophy and calcification of the ligamentum flavum, they further aggravate spinal stenosis.<sup>[26]</sup> Therefore, the combination of restoration of the sagittal balance with precise decompression can exert a good therapeutic effect on degenerative scoliosis.

This study was limited by the small sample size and the lack of in-depth discussion on the location of the fixed segment and fixed distal and proximal vertebrae, as well as the location and method of osteotomy. Therefore, the influences of various factors on the postoperative efficacy in patients with ADS should be further explored.

In conclusion, the spinopelvic parameters SVA, LL, PT, and PI-LL are closely correlated with the postoperative efficacy in patients with ADS.

**Ethics Committee Approval:** The study protocol was approved by the Zhejiang Provincial People's Hospital Ethics Committee (date: 04.03.2016, no: ZRYLS2022102). The study was conducted in accordance with the principles of the Declaration of Helsinki.

**Patient Consent for Publication:** A written informed consent was obtained from each patient.

**Data Sharing Statement:** The data that support the findings of this study are available from the corresponding author upon reasonable request.

**Author Contributions:** Designed this study and prepared this manuscript: F.S., C.X.; Collected and analyzed clinical data: J.Z., C.C.; Writing: Q.C. All authors approved the final version of this manuscript.

**Conflict of Interest:** The authors declared no conflicts of interest with respect to the authorship and/or publication of this article.

**Funding:** This study was financially supported by the Health Science and Technology Plan Project of Zhejiang Province (No. 2022KY017).

## REFERENCES

- Kelly A, Younus A, Lekgwara P. Adult degenerative scoliosis – A literature review. *Interdisciplinary Neurosurgery: Advanced Techniques and Case Management*. 2020 Jun;20:100661. doi: 10.1016/j.inat.2019.100661
- Cristante AF, Silva RTE, Costa GHRD, Marcon RM. Adult degenerative scoliosis. *Rev Bras Ortop (Sao Paulo)* 2021;56:1-8. doi: 10.1055/s-0040-1709736.
- McAviney J, Roberts C, Sullivan B, Alevras AJ, Graham PL, Brown BT. The prevalence of adult de novo scoliosis: A systematic review and meta-analysis. *Eur Spine J* 2020;29:2960-9. doi: 10.1007/s00586-020-06453-0.
- Zhang Y, Liu C, Ge X. Clinical and radiographic outcomes of stand-alone oblique lateral interbody fusion in the treatment of adult degenerative scoliosis: A retrospective observational study. *BMC Musculoskelet Disord* 2022;23:1133. doi: 10.1186/s12891-022-06035-9.
- Kasten MD, Rao LA, Priest B. Long-term results of iliac wing fixation below extensive fusions in ambulatory adult patients with spinal disorders. *J Spinal Disord Tech* 2010;23:e37-42. doi: 10.1097/BSD.0b013e3181cc8e7f.
- Hayden AM, Hayes AM, Brechbuhler JL, Israel H, Place HM. The effect of pelvic motion on spinopelvic parameters. *Spine J* 2018;18:173-8. doi: 10.1016/j.spinee.2017.08.234.
- Atik OŞ. Writing for Joint Diseases and Related Surgery (JDRS): There is something new and interesting in this article! *Jt Dis Relat Surg* 2023;34:533. doi: 10.52312/jdrs.2023.57916.
- Kim W, Porrino JA, Hood KA, Chadaz TS, Klauser AS, Taljanovic MS. Clinical evaluation, imaging, and management of adolescent idiopathic and adult degenerative scoliosis. *Curr Probl Diagn Radiol* 2019;48:402-14. doi: 10.1067/j.cpradiol.2018.08.006.
- Zhang HC, Yu HL, Yang HF, Sun PF, Wu HT, Zhan Y, et al. Short-segment decompression/fusion versus long-segment decompression/fusion and osteotomy for Lenke-Silva type VI adult degenerative scoliosis. *Chin Med J (Engl)* 2019;132:2543-9. doi: 10.1097/CM9.0000000000000474.
- Lak AM, Lamba N, Pompilus F, Yunusa I, King A, Sultan I, et al. Minimally invasive versus open surgery for the correction of adult degenerative scoliosis: A systematic review. *Neurosurg Rev* 2021;44:659-68. doi: 10.1007/s10143-020-01280-9.
- Li W, Zhou S, Zou D, Han G, Sun Z, Li W. Which global sagittal parameter could most effectively predict the surgical outcome for patients with adult degenerative scoliosis? *Global Spine J* 2023;13:1612-21. doi: 10.1177/21925682211043465.
- Takemoto M, Boissière L, Vital JM, Pellisé F, Perez-Gruoso FJS, Kleinstück F, et al. Are sagittal spinopelvic radiographic parameters significantly associated with quality of life of adult spinal deformity patients? Multivariate linear regression analyses for pre-operative and short-term post-operative health-related quality of life. *Eur Spine J* 2017;26:2176-86. doi: 10.1007/s00586-016-4872-y.
- Xu F, Sun Z, Li W, Hou X, Jiang S, Zhou S, et al. Correlation between lordosis distribution index, lordosis tilt, and occurrence of proximal junctional kyphosis following surgery for adult degenerative scoliosis. *Eur Spine J* 2022;31:267-74. doi: 10.1007/s00586-021-07090-x.
- Zhou S, Li W, Su T, Du C, Wang W, Xu F, et al. Does lumbar lordosis minus thoracic kyphosis predict the clinical outcome of patients with adult degenerative scoliosis? *J Orthop Surg Res* 2019;14:290. doi: 10.1186/s13018-019-1339-y.
- Yang Y, Zheng J, Lou S. Medium to long-term curative effects of long-segmental fixation and fusion on degenerative scoliosis. *Int J Clin Exp Med* 2015;8:8129-34.
- Simon J, Longis PM, Passuti N. Correlation between radiographic parameters and functional scores in degenerative lumbar and thoracolumbar scoliosis. *Orthop Traumatol Surg Res* 2017;103:285-90. doi: 10.1016/j.otsr.2016.10.021.
- Ogura Y, Shinozaki Y, Kobayashi Y, Kitagawa T, Yonezawa Y, Takahashi Y, et al. Impact of sagittal spinopelvic alignment on clinical outcomes and health-related quality of life after decompression surgery without fusion for lumbar spinal stenosis. *J Neurosurg Spine* 2019;30:470-5. doi: 10.3171/2018.10.SPINE181094.

18. Protopsaltis T, Schwab F, Bronsard N, Smith JS, Klineberg E, Mundis G, et al. The T1 pelvic angle, a novel radiographic measure of global sagittal deformity, accounts for both spinal inclination and pelvic tilt and correlates with health-related quality of life. *J Bone Joint Surg [Am]* 2014;96:1631-40. doi: 10.2106/JBJS.M.01459.
19. Zhang J, Hai Y, Yang J, Pan A, Zhang Y. Increased PT/SS may play an important role in the pathogenesis of lumbar spondylolisthesis with degenerative lumbar scoliosis. *Clin Neurol Neurosurg* 2018;166:23-30. doi: 10.1016/j.clineuro.2018.01.018.
20. Eguchi Y, Norimoto M, Suzuki M, Haga R, Yamanaka H, Tamai H, et al. Diffusion tensor tractography of the lumbar nerves before a direct lateral transpsoas approach to treat degenerative lumbar scoliosis. *J Neurosurg Spine* 2019;30:461-9. doi: 10.3171/2018.9.SPINE18834.
21. Schwab F, Ungar B, Blondel B, Buchowski J, Coe J, Deinlein D, et al. Scoliosis Research Society-Schwab adult spinal deformity classification: A validation study. *Spine (Phila Pa 1976)* 2012;37:1077-82. doi: 10.1097/BRS.0b013e31823e15e2.
22. Liang Y, Tang X, Zhao Y, Song K, Mao K, Liu H, et al. Limited correction of lumbar lordosis in the treatment of degenerative scoliosis. *Medicine (Baltimore)* 2020;99:e19624. doi: 10.1097/MD.00000000000019624.
23. Zhang HC, Zhang ZF, Wang ZH, Cheng JY, Wu YC, Fan YM, et al. Optimal pelvic incidence minus lumbar lordosis mismatch after long posterior instrumentation and fusion for adult degenerative scoliosis. *Orthop Surg* 2017;9:304-10. doi: 10.1111/os.12343.
24. Ha KY, Jang WH, Kim YH, Park DC. Clinical relevance of the SRS-Schwab classification for degenerative lumbar scoliosis. *Spine (Phila Pa 1976)* 2016;41:E282-8. doi: 10.1097/BRS.0000000000001229.
25. Zhou H, Liang Z, Li P, Shi H, Liang A, Gao W, et al. Correlation analysis of surgical outcomes and spino-pelvic parameters in patients with degenerative lumbar scoliosis. *Front Surg* 2024;10:1319884. doi: 10.3389/fsurg.2023.1319884.
26. Petrosyan E, Fares J, Lesniak MS, Koski TR, El Tecl NE. Biological principles of adult degenerative scoliosis. *Trends Mol Med* 2023;29:740-52. doi: 10.1016/j.molmed.2023.05.012.