












# A comparison between 3D printed models and standard 2D planning in the use of metal block augments in revision knee arthroplasty

Giovanni Balato, MD<sup>1</sup>, Vincenzo De Matteo, MD<sup>1</sup>, Amedeo Guarino, MD<sup>1</sup>, Domenico De Mauro, MD<sup>2</sup>, Dario Baldi, RT<sup>3</sup>, Carlo Cavaliere, MD, PhD<sup>3</sup>, Marco Salvatore, MD<sup>3</sup>, Mustafa Citak, MD<sup>4</sup>, Massimo Mariconda, MD<sup>1</sup>

<sup>1</sup>Department of Public Health, Unit of Orthopaedic Surgery, School of Medicine, Federico II University, Naples, Italy

<sup>2</sup>Department of Orthopedics and Geriatric Sciences, Catholic University of The Sacred Heart, Roma, Italy

<sup>3</sup>IRCCS SYNLAB SDN, Naples, Italy

<sup>4</sup>Department of Orthopaedic Surgery, ENDO-Klinik Hamburg, Hamburg, Germany

Periprosthetic joint infection (PJI) affects up to 1 to 2% of primary implants and 7.9% of revision total knee arthroplasty (TKA) cases.<sup>[1]</sup> Undertaking revision TKA following PJI poses significant challenges due to damaged soft tissues and bone defects. Consequently, these procedures often necessitate a TKA implant with higher constraints and the need for augments to achieve stability and correct knee malalignment.<sup>[2]</sup> Increasing constraints requires adequate fixation in three distinct areas of the distal femur and proximal tibia.<sup>[3]</sup> Addressing the bone defect in revision TKA is mandatory. A commonly utilized classification

Received: December 27, 2023

Accepted: May 14, 2024

Published online: August 14, 2024

**Correspondence:** Vincenzo De Matteo, MD. Unit of Orthopaedic Surgery, Department of Public Health, School of Medicine, Federico II University, Naples, Italy.

E-mail: vincenzo.dematteo@unina.it

Doi: 10.52312/jdrs.2024.1591.

**Citation:** Balato G, de Matteo V, Guarino A, de Mauro A, Baldi D, Cavaliere C, et al. A comparison between 3D printed models and standard 2D planning in the use of metal block augments in revision knee arthroplasty. *Jt Dis Relat Surg* 2024;35(3):473-482. doi: 10.52312/jdrs.2024.1591.

©2024 All right reserved by the Turkish Joint Diseases Foundation

This is an open access article under the terms of the Creative Commons Attribution-NonCommercial License, which permits use, distribution and reproduction in any medium, provided the original work is properly cited and is not used for commercial purposes (<http://creativecommons.org/licenses/by-nc/4.0/>).

## ABSTRACT

**Objectives:** The study focused on the ability to predict the need and size of femoral and tibial augmentation using standard two-dimensional (2D) templates and models created with three-dimensional (3D) printing in surgical planning.

**Patients and methods:** This observational cohort study included 28 consecutive patients (22 females, 6 males; mean age: 71±7.3 years; range, 54 to 82 years) with periprosthetic joint infection recruited between March 2021 and September 2023 undergoing revision total knee arthroplasty revision (TKA). Standard planning was made using calibrated X-ray images. The 3D planning started with computed tomography scans to generate a 3D template of the distal femur and proximal tibia. The model was exported to a 3D printer to produce a patient-specific phantom. The surgery was then simulated on the 3D phantom using revision knee arthroplasty instrumentation to evaluate the appropriate augmentation to use until a correct alignment was obtained.

**Results:** Three-dimensional planning predicted the need for femoral and tibial augments in 22 (78.6%) cases at both the tibial and femoral components, while 2D planning correctly predicted the need for augmentation in 17 (60.7%) for the tibial side and 18 (64.3%) for the femoral side. The Cohen's kappa demonstrated a significant agreement between the 3D planning for the femoral metal block and the intraoperative requirement (kappa=0.553), whereas 2D planning showed only nonsignificant poor agreement (kappa=0.083). In contrast, the agreement between 2D or 3D preoperative planning for tibial augment and the intraoperative requirement was nonsignificant (kappa=0.130 and kappa=0.158, respectively). On the femoral side, 2D planning showed only a fair nonsignificant correlation (r=0.35, p=0.069), whereas 3D planning exhibited substantial agreement with the actual thickness of the implanted augment (r=0.65, p<0.001). On the tibial side, 3D and 2D planning showed substantial agreement with the actual size of implanted augments (3D planning, r=0.73, p<0.001; 2D planning, r=0.69, p<0.001).

**Conclusion:** Prediction based on 3D computed tomography segmentation showed significant agreement with the intraoperative need for augmentations in revision TKA. The results suggest that planning with 3D printed models represents a stronger aid in this kind of surgery rather than standard 2D planning, providing greater accuracy in the prediction of the required augmentation in revision TKA.

**Keywords:** Augmentation, preoperative planning, revision arthroplasty, templating, 2D Planning, 3D Planning, 3D printing.

for bone loss is the Anderson Orthopedic Research Institute (AORI) system, which categorizes bone loss into three levels.<sup>[4]</sup> In most septic revisions, the epiphyseal areas are compromised, typically resulting in a type 2 AORI defect; in such cases, augmentation is often necessary.<sup>[5]</sup> It is well-established that preoperative planning can diminish the incidence of complications,<sup>[6]</sup> as well as reduce surgery duration and costs.<sup>[7]</sup> However, standard two-dimensional (2D) revision TKA planning can be misleading, potentially underestimating or overestimating the residual bone stock; its accuracy and reliability for implant size prediction have been questioned.<sup>[8]</sup> In contrast, three dimensional (3D) templating has proven to offer high precision in implant size prediction,<sup>[9]</sup> likely due to the superior spatial resolution of computed tomography (CT), which can identify segmental defects.<sup>[10,11]</sup> Wu et al.<sup>[12]</sup> demonstrated that personalized 3D planning for revision hip arthroplasty using cages results in greater accuracy than conventional 2D templating. Data from the CT scan can be “segmented” to create a digital model of the reconstruction, which can then be 3D printed to produce an accurate replica of the patient's joint. A physical 3D model of the patient's knee could enable the surgeon to plan and simulate the procedure before the actual surgery. Accordingly, this study hypothesized that having a tangible model of the patient's knee morphology could prepare the surgeon to anticipate and better handle the challenges of the case more effectively. Thus, this study aimed to compare the efficacy of standard 2D preoperative planning versus 3D preoperative planning in predicting the need and size of tibial and femoral augmentation in revision TKA following a PJI.

## PATIENTS AND METHODS

This observational cohort study included 28 consecutive patients (22 females, 6 males; mean age: 71±7.3 years; range, 54 to 82 years) diagnosed with PJI, recruited between March 2021 and September 2023, undergoing TKA reimplantation following a staged procedure at the orthopedic department of the Federico II University Hospital (Naples Italy). The inclusion criteria were as follows: (i) a diagnosis of PJI according to the 2018 International Consensus Meeting (ICM) criteria<sup>[13]</sup> for PJI on a primary or revision TKA; (ii) a two-stage procedure planned and performed at our institution; (iii) availability of CT scans of the lower limb. The exclusion criteria included the following: (i) incomplete preoperative or postoperative imaging; (ii) intraoperative signs of infection that contraindicated the final revision; (iii) an incomplete two-stage procedure. Bone defects

in patients were evaluated preoperatively and intraoperatively according to the AORI classification;<sup>[14]</sup> the diagnosis of chronic infection was made following the 2018 ICM criteria.<sup>[13]</sup>

All cases of revision TKA were assessed using traditional calibrated X-rays in anteroposterior, lateral, full-leg weight-bearing, and Merchant views, in line with clinical standard protocols. Additionally, all patients eligible for second-stage knee revision surgery underwent a CT scan of the lower limb to investigate potential rotational defects.

Computed tomography scans were performed using a third-generation Dual Source Computed Tomography Somatom Force (Siemens Healthineers, Erlangen, Germany). Patients were positioned supine with their arms along the trunk and the joint to be revised centered in the field of view to minimize geometrical artifacts.<sup>[15]</sup> Each patient underwent two CT acquisitions: an ultralow dose CT (ULDCT) scan from the acetabular cavity to the foot for an overall assessment of the joint and skeletal axes, and a dedicated dual-energy CT (DECT) scan covering the entire implant for tissue characterization, segmentation procedures, and 3D modeling.

Patients were diagnosed and treated by two senior surgeons highly experienced in managing PJI, supported by an interdisciplinary team. To mitigate confirmation biases, standard 2D planning and 3D printed templating for each patient were performed by two different experienced surgeons before the second-stage surgery. Following prior consent, all implant-related information was stored according to protocol and later retrieved by one investigator for the study.

### Imaging parameters

The ULDCT scan parameters were as follows: (i) gantry rotation time was set at 0.5 sec; (ii) collimation was 192×0.6 mm, utilizing a z-flying focal spot and automated tube current modulation via Siemens Care Dose 4D (Siemens Healthineers, Erlangen, Germany); (iii) voltage was maintained at 100 kV, enhanced with additional spectrum hardening from a mounted thin filter; (iv) the reference tube current-time product was established at 80 mAs; (v) acquisition was performed using a single tube; (vi) the pitch was approximately 5.<sup>[16]</sup>

For the DECT acquisition, the parameters included: (i) a gantry rotation time of 0.5 seconds; (ii) collimation of 192×0.6 mm, also employing a z-flying focal spot and automated tube current modulation (Siemens Care Dose 4D); (iii) voltage settings were Sn150 kV for

the first tube and either 80 or 100 kV for the second; (iv) the pitch was approximately 0.7.<sup>[16]</sup>

Within our institution, the majority of patients diagnosed with PJI are treated using a Hoffman-type spacer. This device consists of a metal implant for the femoral component alongside metallic wires or screws encased in antibiotic-loaded cement under the polyethylene for the tibial side.

Given the metallic components involved, it was imperative to process the CT raw data with an iterative algorithm for metal artifact reduction (iMAR) to significantly mitigate artifacts caused by the implants and prostheses.<sup>[17]</sup>

The X-ray and CT scan data were gathered and anonymized by one of the investigators, who was not involved in the planning phase. Two codes were assigned to each patient, one for X-ray images and one for CT data. Two expert investigators independently planned the cases, one using X-ray images and the other carrying out the 3D planning with surgical simulation.

### Two-dimensional planning

Standard 2D planning was executed using calibrated plain X-ray images in conjunction with TraumaCad software (Brainlab AG, Munich, Germany). On the anteroposterior (AP) view, lines were drawn to

delineate both the femoral and tibial mechanical and anatomical axes. Digital templating was subsequently applied to these images to evaluate the bone stock and determine the optimal positioning of the implants. This assessment included consideration of the potential need for augments to restore articular congruency and the load axis (Figure 1).

### Surgical templating with a 3D printed model

The CT data, stored in DICOM (Digital Imaging and Communications in Medicine) format, were imported into the Materialise Interactive Medical Image Control System (Materialise, Leuven, Belgium) to create 3D digital models of the distal femur and proximal tibia. These models were then exported in Standard Triangulation Language (.stl) format and imported into a 3D printer to fabricate a patient-specific bone model at a one-to-one scale.

Segmentation of the DECT images was conducted using Mimics InPrint software (Materialise, Leuven, Belgium), allowing for the differentiation of various joint components (e.g., cement, bone, and metal). This process generated three distinct meshes, which were then aligned with the ULDCCT segmentation.

The model file was further refined by removing the components of the spacer and incorporating lines to represent the tibial and femoral mechanical

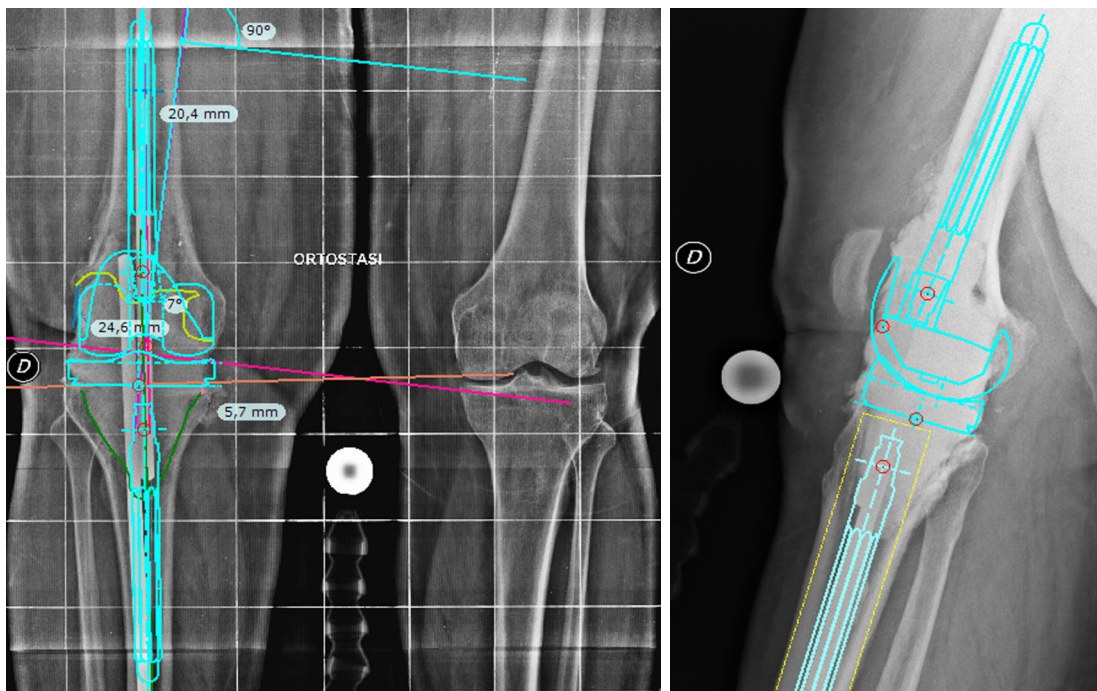
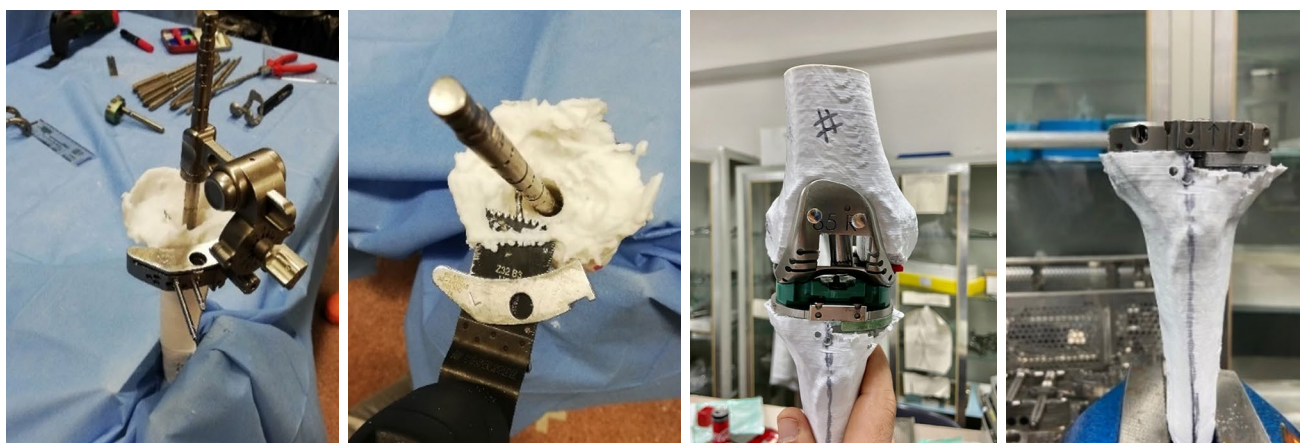

FIGURE 1. Standard 2D planning on a plain radiograph.





**FIGURE 2.** Three-dimensional planning on poly-lactic acid phantoms using revision surgery instruments.

axes.<sup>[18]</sup> The file was then sliced using Ultimaker Cura version 4.5 software (Ultimaker B.V., Geldermalsen, the Netherlands) and printed with polylactic acid on an Ultimaker S5 printer. The resulting model included both the distal femur and the proximal tibia and fibula (each 25 cm in length) of each patient, identified by an anonymization code. Models were then mounted on supports and meticulously examined to determine the optimal strategy for achieving mechanical alignment.

During the simulation of revision TKA using specialized instrumentation, all necessary cuts were made on the phantom, and the appropriate augmentation was selected (Figure 2) until correct alignment was achieved (Figure 3). Comprehensive data regarding the need for augmentation on the tibial

or femoral side, as well as the sizing of the augument, were systematically collected.

#### Surgical technique


Operations were conducted under either spinal or spinal-epidural anesthesia. A tourniquet was applied to the proximal thigh, and an incision was made over the existing surgical scar. Access to the joint was achieved via a medial parapatellar approach. A complete synovectomy and the removal of the spacer's components were carried out, followed by thorough debridement and irrigation with a diluted solution of betadine and hydrogen peroxide.<sup>[19]</sup> Revision TKA instrumentation was employed to assess joint alignment, stability, and range of motion. The selection of definitive implants was based on achieving the most appropriate correction, with all implants being fixed in place using polymethylmethacrylate cement.

#### Postoperative follow-up

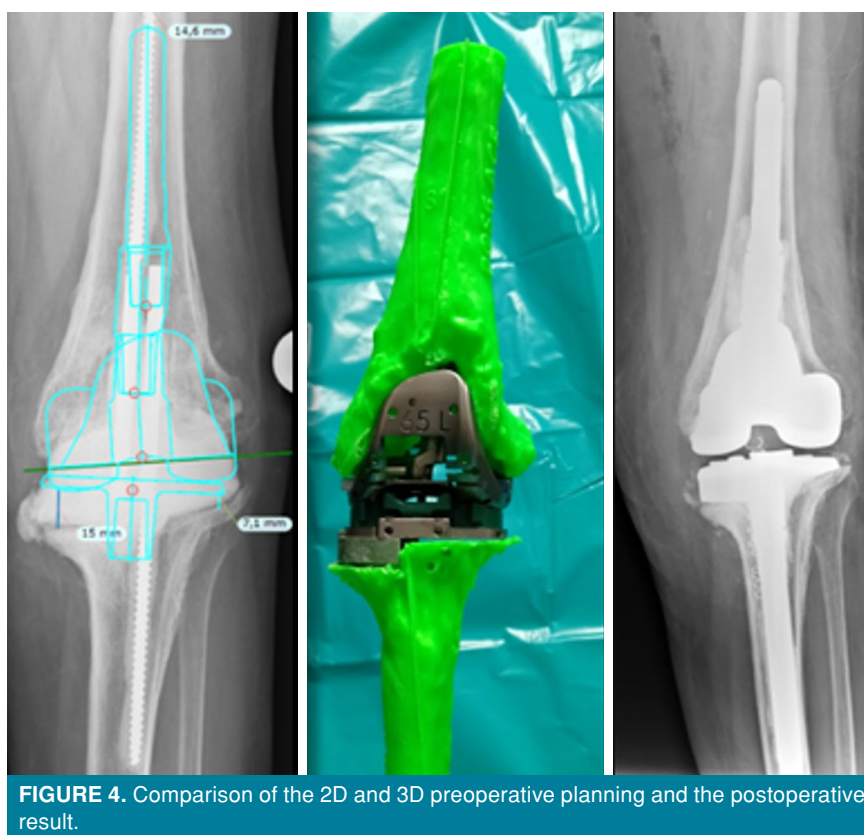
Postoperative radiographic evaluations included anteroposterior, lateral, and full-leg weight-bearing X-rays conducted immediately after surgery and one month postoperatively. These assessments focused on mechanical alignment, angular deformity, and leg length discrepancy (Figure 4).

#### Statistical analysis

Data collection adhered to an anonymization protocol. Statistical analyses were conducted using IBM SPSS version 28.0 software (IBM Corp., Armonk, NY, USA). Differences between 2D and 3D templating methods and the sizes of implants used intraoperatively were examined using



**FIGURE 3.** Mechanical alignment is restored using a proper augmentation (orange arrow).



**FIGURE 4.** Comparison of the 2D and 3D preoperative planning and the postoperative result.

contingency tables and analyzed with the chi-square test. The correlation between the predicted need for augmentation in 2D and 3D planning and the postoperative outcomes was evaluated using Cohen's kappa. A  $p$ -value  $<0.05$  was deemed statistically significant.

The accuracy of both planning methods was further assessed through Pearson's correlation analysis, testing the agreement between the final augment size used in the definitive implant and

those predicted by both the 2D and 3D planning approaches. The criteria outlined by Landis and Koch<sup>[20]</sup> were applied to evaluate the results, categorized as follows: 0.01-0.20, slight agreement; 0.21-0.40, fair; 0.41-0.60, moderate; 0.61-0.80, substantial; and 0.81-1.00, almost perfect agreement.

## RESULTS

Demographic characteristics are presented in Table I. According to the AORI classification, on the

TABLE I				
Demographic characteristics				
Variable	n	%	Mean±SD	Range
Age (year)			71±7.3	54-82
Sex				
Female	22	78.6		
Implant removed-primary TKA	26	92.9		
Spacer type-articulated	24	85.7		
Type of definitive implant				
Zimmer Biomet NexGen® Legacy® Constrained Condylar Knee (LCCK)	24	85.7		
Zimmer-Biomet Vanguard® 360 Revision Knee System	4	14.3		

SD: Standard deviation; TKA: Total knee arthroplasty.

femoral side, 20 patients exhibited a type 1 defect, four had a type 2A defect, and the remaining patients had type 2B defects. No defects were classified as type 3. On the tibial side, defects were classified as follows: four patients with a type 1 defect, 16 with a type 2A defect, four with a type 2B defect, and the remaining patients had a type 3 defect, as shown in Table II. Total realignment was achieved in 25 (89%) patients; outliers ranged between 2° valgus and 3° varus in three (11%) patients. The most frequent defect was AORI 2A on the medial side of the tibia. The performance of 2D and 3D planning in predicting the need for augmentation, with the definitive implant serving as a reference, was analyzed.

**Need for augmentation**

Standard preoperative 3D planning accurately predicted the need for both femoral and tibial augmentations in 22 (78.6%) out of 28 cases, while preoperative 2D planning correctly anticipated

the need for femoral and tibial augmentation in 17 (60.7%) out of 28 and 18 (64.3%) out of 28 cases, respectively (Table III). The preoperative 3D planning requirement for femoral augmentation, analyzed using Cohen’s kappa, demonstrated a moderate but significant agreement with the actual intraoperative requirement (kappa=0.553, p>0.005), whereas 2D planning showed only nonsignificant poor agreement with postoperative results (kappa=0.083, p>0.649). For the tibial side, both planning techniques exhibited slight but no statistically significant agreement with the actual intraoperative requirements and the preoperative 3D planned requirement for femoral augmentation (3D planning, kappa=0.158, p<0.393; 2D planning, kappa=0.130, p<0.483; Table III).

**Size of augmentation**

For the femoral side, when an augmentation was required, 3D planning-estimated thickness showed substantial agreement with the actual thickness of the applied augment (r=0.65, p<0.001); whereas 2D

**TABLE II**  
Patients stratification according to the AORI classification

	AORI classification							
	1		2A		2B		3	
	n	%	n	%	n	%	n	%
AORI femur	20	71.4	4	14.3	4	14.3	0	0
AORI tibia	4	14.3	16	57.1	4	14.3	4	14.3

AORI: Anderson Orthopedic Research Institute.

**TABLE III**  
Preoperative prediction of the need for augmentation

	Postoperative femur		Postoperative tibia		k	p
	Yes	No	Yes	No		
	n	n	n	n		
Femur 3D planning					0.553	0.005
Yes	7	3				
No	3	15				
Femur 2D planning					0.083	0.674
Yes	3	4				
No	7	14				
Tibia 3D planning					0.158	0.393
Yes			19	4		
No			2	3		
Tibia 2D planning					0.130	0.483
Yes			15	4		
No			6	3		

TABLE IV				
Agreement between preoperative 2D and 3D planning for augment thickness and the applied augment thickness on the femoral side				
Applied augment thickness	0 mm	5 mm	10 mm	Total
3D Planning estimated thickness				
5 mm	3	6	0	9
10 mm	0	0	1	1
Total	3	6	1	10
2D Planning estimated thickness				
5 mm	7	2	0	9
10 mm	0	0	1	1
Total	7	2	1	10

TABLE V					
Agreement between preoperative 2D and 3D planning for augment thickness and the applied augment thickness on the tibial side					
Applied augment thickness	0 mm	5 mm	10 mm	15 mm	Total
3D Planning estimated thickness					
5 mm	1	11	2	0	14
10 mm	0	3	1	1	5
15 mm	0	0	0	2	2
Total	1	14	3	3	21
2D Planning estimated thickness					
5 mm	6	8	0	0	14
10 mm	0	1	3	1	5
15 mm	0	0	0	2	2
Total	6	9	3	3	21

planning showed only fair nonsignificant correlation ( $r=0.35$ ,  $p=0.069$ ; Table IV). For the tibial side, 3D and 2D planning-estimated thickness showed substantial agreement with the actual size of implanted augments (3D planning,  $r=0.733$ ,  $p<0.001$ ; 2D planning,  $r=0.69$ ,  $p<0.001$ ; Table V).

## DISCUSSION

Three-dimensional printing is emerging as a popular tool in orthopedic surgery showing promises in the field of trauma<sup>[21]</sup> and reconstructive surgery.<sup>[22]</sup> Numerous studies have highlighted the role of this technology in improving surgeon performance and reducing blood loss and fluoroscopy time.<sup>[23-25]</sup> A 3D physical reconstruction of the patient's anatomy represents a valid help for surgeons who have to face severe bone loss in revision TKA, reaching a successful

prediction that helped obtain a total realignment in almost 90% of cases, according to our data. A proper understanding of patients' bony defects is mandatory for those who want to address this kind of surgery; thus, accurate planning is necessary.<sup>[24]</sup> This study confirmed the importance of preoperative planning in this case. Both 3D and 2D planning could grant a significant prediction of bone loss and the needed intraoperative corrections, reaching a good prediction capability even with 2D. It helps to prepare numerous strategies and select the best one at the moment of the surgery.

The advantages of 3D printing have been recognized in other medical areas, including traumatology, where 3D models enable precise identification of landmarks for safer, more accurate cuts.<sup>[25]</sup> Additionally, considering a general growing interest in the educational field, 3D models have been



acknowledged as a teaching or demonstrative tool for both the patient and the resident, as suggested by Rodriguez Colon et al.,<sup>[26]</sup> who reported that 3D printing has a valid and positive impact on both patients and surgeons' education. Revision TKA following a PJI is often hard to understand for patients, and 3D allows them to observe and realize the entity of the surgery they are going to receive, providing real informed consent. On the other side, surgical simulation helps less experienced surgeons and residents to understand the challenges of complex revisions.<sup>[27]</sup>

According to the literature, our findings confirm the first impressions about the aid provided by 3D planning, as already experienced by Shen et al.,<sup>[21]</sup> facing complex tibial plateau fractures. This also involves the actual medicine frontier, represented by personalized medicine. Planning based on a specific 3D model of individual patients allows to tailor the proper surgery for each patient.<sup>[28]</sup> Three-dimensional planning requires time, expertise, and resources to be properly implemented, and although the technology is getting more affordable, it might be suitable only for selected cases. However, stronger evidence is available in the literature, highlighting how 3D printing is a cost-saving procedure when higher efficiency and shorter operating times are taken into account.<sup>[28]</sup>

Our results demonstrate that preoperative 3D planning was overall more accurate than 2D planning in predicting the requirement and the thickness for augmentation. This appears to be particularly effective on the femoral side. We may speculate that this ability is related to its superior triplanar reproduction of bone defects in an anatomically complex area.

It is undoubtedly difficult to assess the femoral damage on a standard X-ray in anteroposterior view in Hofmann-type spacers since the femoral component shades the bone below, while CT allows the 3D assessment of bone loss. However, the CT scan required for the reconstruction needs appropriate artifact reduction techniques and exposes the patient to more radiation if compared to standard X-rays.

Another advantage of 3D planning is to allow the surgeon to study the final rotational alignment of the implant. However, 3D planning was not superior in predicting the exact size of the augment. One explanation could lie in the availability of the other bony segments as a reference in the standard 2D planning with the lower limb under load projection. Visualizing the mechanical and anatomical axes could guide the choice of the correct size of

bony augmentation. Another reason could be the surgeons' familiarity with traditional X-ray planning. Furthermore, in our study, it was evident that the main advantage of 2D planning is a more accurate definition of the preoperative alignment of the knee under load bearing. In addition, 3D planning could have a precious and important didactic role in training knee surgeons, helping them to overcome the learning curve in revision TKA.

This analysis extends our previous report on 3D preoperative planning in knee prosthetic surgery<sup>[29]</sup> and confirms its accuracy. To the best of our knowledge, no other studies are available in the literature comparing the accuracy of 3D versus 2D planning in predicting the actual intraoperative need and size of augmentations in revision TKA.<sup>[30]</sup>

There are some limitations to our study. Three-dimensional planning is not able to predict soft tissue conditions and balance between flexion and extension gaps. Gap balancing can in turn require a soft tissue release or a modified implant configuration. In addition, to prevent confirmation bias, each surgeon used a single technique of templating instead of performing an interobserver reliability analysis. Moreover, the sample size was relatively small and cannot lead to a more solid statement about this topic. Lastly, bidimensional planning does not allow an effective prediction of rotational defects, particularly on the femoral side. By contrast, 3D planning theoretically allows the surgeon to predict femoral asymmetrical augmentation. Unfortunately, a direct comparison between these two planning techniques for rotational issues is not possible, considering the intrinsic drawbacks of 2D planning, although it represents another possible added value for 3D planning that needs to be confirmed in further investigations.

In conclusion, surgical preoperative planning is crucial in revision TKA, particularly PJI. Three-dimensional planning offers superior support in revision TKA compared to conventional 2D planning, enabling more precise assessments of preoperative conditions and bone loss in revision TKA. However, further prospective studies with adequate power are necessary to definitively determine the role of 3D planning in revision TKA.

**Ethics Committee Approval:** The study protocol was approved by the Federico II University of Naples Ethics Committee (date: 06.10.2020, no: 0029062). The study was conducted in accordance with the principles of the Declaration of Helsinki.



**Patient Consent for Publication:** A written informed consent was obtained from each patient.

**Data Sharing Statement:** The data that support the findings of this study are available from the corresponding author upon reasonable request.

**Author Contributions:** Dea/concept, design: G.B, V.D.M.; Control/supervision: M.M., M.C., G.B.; Data collection and/or processing: V.D.M., M.M., G.B.; Analysis and/or interpretation: M.M., M.C., V.D.M.; Literature review: M.M., D.B., D.D.M., C.C.; Writing the article: V.D.M., A.G., D.B., C.C.; Critical review: C.C., M.S., M.M., C.C.; References and fundings: G.B., V.D.M., M.S., D.B., C.C.; Materials: G.B., A.G., C.C., D.B., M.S.; Other: D.D.M., A.G.

**Conflict of Interest:** The authors declared no conflicts of interest with respect to the authorship and/or publication of this article.

**Funding:** This work was supported by a "Ricerca Corrente" Grant from the Italian Ministry of Health (IRCCS SYNLAB SDN).

## REFERENCES

- Mortazavi SM, Molligan J, Austin MS, Purtill JJ, Hozack WJ, Parvizi J. Failure following revision total knee arthroplasty: Infection is the major cause. *Int Orthop* 2011;35:1157-64. doi: 10.1007/s00264-010-1134-1.
- Vasso M, Beaufils P, Schiavone Panni A. Constraint choice in revision knee arthroplasty. *Int Orthop* 2013;37:1279-84. doi: 10.1007/s00264-013-1929-y.
- Morgan-Jones R, Oussedik SI, Graichen H, Haddad FS. Zonal fixation in revision total knee arthroplasty. *Bone Joint J* 2015;97-B:147-9. doi: 10.1302/0301-620X.97B2.34144.
- Engh GA, Ammeen DJ. Classification and preoperative radiographic evaluation: Knee. *Orthop Clin North Am* 1998;29:205-17. doi: 10.1016/s0030-5898(05)70319-9.
- Bieganowski T, Buchalter DB, Singh V, Mercuri JJ, Aggarwal VK, Rozell JC, et al. Bone loss in aseptic revision total knee arthroplasty: Management and outcomes. *Knee Surg Relat Res* 2022;34:30. doi: 10.1186/s43019-022-00158-y.
- Bonanzinga T, Tanzi G, Iacono F, Ferrari MC, Marcacci M. Periprosthetic knee infection: Two stage revision surgery. *Acta Biomed* 2017;88:114-9. doi: 10.23750/abm.v88i4-S.6802.
- Koh CK, Zeng I, Ravi S, Zhu M, Vince KG, Young SW. Periprosthetic joint infection is the main cause of failure for modern knee arthroplasty: An analysis of 11,134 knees. *Clin Orthop Relat Res* 2017;475:2194-201. doi: 10.1007/s11999-017-5396-4.
- Jain NP, Guyver PM, McCarthy MJ, Press J, Keenan J. The accuracy and reliability of pre-operative templating in revision total knee arthroplasty. A comparison of analogue and digital methods. *J Orthop* 2014;11:121-5. doi: 10.1016/j.jor.2014.06.017.
- Bahadır B, Atik OŞ, Kanatlı U, Sarıkaya B. A brief introduction to medical image processing, designing and 3D printing for orthopedic surgeons. *Jt Dis Relat Surg* 2023;34:451-4. doi: 10.52312/jdrs.2023.57912.
- Solomon LB, Stamenkov RB, MacDonald AJ, Yaikwawong N, Neale SD, Moss MJ, et al. Imaging periprosthetic osteolysis around total knee arthroplasties using a human cadaver model. *J Arthroplasty* 2012;27:1069-74. doi: 10.1016/j.arth.2011.09.012.
- Brenneis M, Flevas DA, Bornes TD, Braun S, Meurer A, Sculco PK, et al. Tibial bone defect prediction based on preoperative artefact-reduced CT imaging is superior to standard radiograph assessment. *Knee Surg Sports Traumatol Arthrosc* 2023;31:4842-50. doi: 10.1007/s00167-023-07527-4.
- Wu L, Zhao X, Lu ZD, Yang Y, Ma L, Li P. Accuracy analysis of artificial intelligence-assisted three-dimensional preoperative planning in total hip replacement. *Jt Dis Relat Surg* 2023;34:537-47. doi: 10.52312/jdrs.2023.1059.
- Parvizi J, Tan TL, Goswami K, Higuera C, Della Valle C, Chen AF, et al. The 2018 definition of periprosthetic hip and knee infection: An evidence-based and validated criteria. *J Arthroplasty* 2018;33:1309-14.e2. doi: 10.1016/j.arth.2018.02.078.
- Mancuso F, Beltrame A, Colombo E, Miani E, Bassini F. Management of metaphyseal bone loss in revision knee arthroplasty. *Acta Biomed* 2017;88:98-111. doi: 10.23750/abm.v88i2-S.6520.
- Akin-Akintayo OO, Alexander LF, Neill R, Krupinski EA, Tang X, Mittal PK, et al. Prevalence and severity of off-centering during diagnostic CT: Observations from 57,621 CT scans of the chest, abdomen, and/or pelvis. *Curr Probl Diagn Radiol* 2019;48:229-34. doi: 10.1067/j.cpradiol.2018.02.007.
- Lewis M, Reid K, Toms AP. Reducing the effects of metal artefact using high keV monoenergetic reconstruction of dual energy CT (DECT) in hip replacements. *Skeletal Radiol* 2013;42:275-82. doi: 10.1007/s00256-012-1458-6.
- Long Z, Bruesewitz MR, DeLone DR, Morris JM, Amrami KK, Adkins MC, et al. Evaluation of projection- and dual-energy-based methods for metal artifact reduction in CT using a phantom study. *J Appl Clin Med Phys* 2018;19:252-60. doi: 10.1002/acm2.12347.
- Miura M, Hagiwara S, Nakamura J, Wako Y, Kawarai Y, Ohtori S. Interobserver and intraobserver reliability of computed tomography-based three-dimensional preoperative planning for primary total knee arthroplasty. *J Arthroplasty* 2018;33:1572-8. doi: 10.1016/j.arth.2017.12.035.
- Balato G, De Matteo V, De Franco C, Lenzi M, Verrazzo R, de Giovanni R, et al. Prevention and treatment of periprosthetic joint infection using surgical wound irrigation. *J Biol Regul Homeost Agents* 2020;34(5 Suppl. 1):17-23. IORS Special Issue on Orthopedics.
- Landis JR, Koch GG. The measurement of observer agreement for categorical data. *Biometrics* 1977;33:159-74.
- Shen S, Wang P, Li X, Han X, Tan H. Pre-operative simulation using a three-dimensional printing model for surgical treatment of old and complex tibial plateau fractures. *Sci Rep* 2020;10:6044. doi: 10.1038/s41598-020-63219-w.
- Hughes AJ, DeBuitler C, Soden P, O'Donnchadha B, Tansey A, Abdulkarim A, et al. 3D printing aids acetabular reconstruction in complex revision hip arthroplasty. *Adv Orthop* 2017;2017:8925050. doi: 10.1155/2017/8925050.
- Wong RMY, Wong PY, Liu C, Chung YL, Wong KC, Tso CY, et al. 3D printing in orthopaedic surgery: A scoping review of randomized controlled trials. *Bone Joint Res* 2021;10:807-19. doi: 10.1302/2046-3758.1012.BJR-2021-0288.R2.
- Lei PF, Hu RY, Hu YH. Bone defects in revision total knee arthroplasty and management. *Orthop Surg* 2019;11:15-24. doi: 10.1111/os.12425.

25. Aprato A, Olivero M, Iannizzi G, Bistolfi A, Sabatini L, Masse A. Pelvic discontinuity in acetabular revisions: Does CT scan overestimate it? A comparative study of diagnostic accuracy of 3D-modeling and traditional 3D CT scan. *Musculoskelet Surg* 2020;104:171-7. doi: 10.1007/s12306-019-00608-z.
26. Rodriguez Colon R, Nayak VV, Parente PEL, Leucht P, Tovar N, Lin CC, et al. The presence of 3D printing in orthopedics: A clinical and material review. *J Orthop Res* 2023;41:601-13. doi: 10.1002/jor.25388.
27. Wu AM, Wang K, Wang JS, Chen CH, Yang XD, Ni WF, et al. The addition of 3D printed models to enhance the teaching and learning of bone spatial anatomy and fractures for undergraduate students: A randomized controlled study. *Ann Transl Med* 2018;6:403. doi: 10.21037/atm.2018.09.59.
28. Mattei L, Pellegrino P, Calò M, Bistolfi A, Castoldi F. Patient specific instrumentation in total knee arthroplasty: A state of the art. *Ann Transl Med* 2016;4:126. doi: 10.21037/atm.2016.03.33.
29. Balato G, Lenzi M, de Matteo V, Verrazzo R, de Giovanni R, Baldi D, et al. 3D planning in revision total knee arthroplasty following periprosthetic joint infection. A pilot study. *Lo Scalpello Journal* 2022;36:131-4. doi: 10.36149/0390-5276-265.
30. Atik OŞ. Writing for Joint Diseases and Related Surgery (JDRS): There is something new and interesting in this article! *Jt Dis Relat Surg* 2023;34:533. doi: 10.52312/jdrs.2023.57916.