













Anterolateral approach may be superior to posterolateral approach in controlling postoperative lower limb discrepancy in primary total hip arthroplasty: A single-center, retrospective cohort study

Ao Xiong, MD^{1,2*} , Guoqing Li, MD^{1,2*} , Su Liu, MD^{1,2} , Yixiao Chen, MD^{1,2} , Chang Xu, MD³ , Jian Weng, MD^{1,2} , Fei Yu, MD^{1,2} , Liang Gao, MD⁴ , Deli Wang, MD^{1,2} , Hui Zeng, MD^{1,2} 

¹Department of Bone and Joint Surgery, Peking University Shenzhen Hospital, Shenzhen, People's Republic of China

²National and Local Joint Engineering Research Center of Orthopaedic Biomaterials, Peking University Shenzhen Hospital, Shenzhen, People's Republic of China

³Intelligent Hospital Research Academy, Peking University Shenzhen Hospital, Shenzhen, People's Republic of China

⁴Sino Euro Orthopaedics Network, Berlin, Germany

Total hip arthroplasty (THA) is a valid method for various hip joint diseases and quantitative THAs are necessary for the aging population.^[1-3] Successful THA could provide adequate pain relief, restore

Received: June 25, 2022

Accepted: September 25, 2022

Published online: November 18, 2022

Correspondence: Deli Wang, MD. Department of Bone & Joint Surgery, Peking University Shenzhen Hospital, 518036 Shenzhen, PR China,

2. National & Local Joint Engineering Research Center of Orthopaedic Biomaterials, Peking University Shenzhen Hospital, 518036 Shenzhen, PR China.

E-mail: wangdelinavy@163.com

Correspondence: Hui Zeng, MD. Department of Bone & Joint Surgery, Peking University Shenzhen Hospital, 518036 Shenzhen, PR China,

2. National & Local Joint Engineering Research Center of Orthopaedic Biomaterials, Peking University Shenzhen Hospital, 518036 Shenzhen, PR China.

E-mail: zenghui_36@163.com

Doi: 10.52312/jdrs.2022.763

Citation: Xiong A, Li G, Liu S, Chen Y, Xu C, Weng J, et al. Anterolateral approach may be superior to posterolateral approach in controlling postoperative lower limb discrepancy in primary total hip arthroplasty: A single-center, retrospective cohort study. Jt Dis Relat Surg 2023;34(1):i-x.

©2023 All right reserved by the Turkish Joint Diseases Foundation

This is an open access article under the terms of the Creative Commons Attribution-NonCommercial License, which permits use, distribution and reproduction in any medium, provided the original work is properly cited and is not used for commercial purposes (<http://creativecommons.org/licenses/by-nc/4.0/>).

ABSTRACT

Objectives: This study aims to investigate the possible association and comparison between anterolateral approach (ALA) and posterolateral approach (PLA) and postoperative lower limb discrepancy (LLD) in selective total hip arthroplasty (THA).

Patients and methods: April 2021 and July 2021, a total of 266 consecutive patients (126 males, 140 females; mean age: 46.7±13.6 years; range, 22 to 60 years) who underwent unilateral primary THA via the ALA or the PLA were retrospectively analyzed. The operations were performed by a single surgical team. All patients were divided into two groups according to the approach: ALA group (n=66) and PLA group (n=200). Relevant data were recorded. Diagnosis including hip osteoarthritis, developmental dysplasia of the hip (DDH), aseptic avascular necrosis (AVN), and inflammatory arthritis were noted. Perioperative follow-up radiographs were evaluated and measured to compare the postoperative LLD and offset. The association between two approaches and postoperative LLD and offset was analyzed using the univariate and multivariate linear regression analysis.

Results: The mean follow-up was 20±3.7 (range, 16 to 25) months. Univariate analysis revealed that the postoperative LLD, the postoperative acetabular offset, and hospital costs were lower in the ALA group than the PLA group (p<0.01). However, the offset and length of stay were comparable between the two groups (p>0.05). Multivariate analysis revealed that the PLA ($\beta=4.71$; 95% confidence interval [CI]: 1.78 to 7.64), preoperative LLD ($\beta=0.29$; 95% CI: 0.21 to 0.37), DDH ($\beta=5.01$; 95% CI: 1.47 to 8.55), and AVN ($\beta=3.81$; 95% CI: 0.50 to 7.12) were the main contributors to the postoperative LLD.

Conclusion: Our study results suggest that the ALA may be superior to the PLA in controlling the postoperative LLD among some of the selective unilateral primary THA patients. Both the ALA and the PLA were comparable in terms of the restoration of offset.

Keywords: Anterolateral approach, lower limb discrepancy, posterolateral approach, radiological assessment, total hip arthroplasty.

hip function, improve quality of life, and obtain satisfied long-term outcomes.^[4] Surgical approaches for THA have not changed much during recent decades. However, the efficacy of THA has been significantly improved with the good bone quality and good bone mineral density, eventually good bone strength which is crucial for the better survival of implants.^[5] However, postoperative lower limb discrepancy (LLD) and improper offset occur occasionally, which may result in the adverse events including instability, impingement, or even dislocation.^[6] The postoperative LLD remained the most common cause of dissatisfaction and gait disorders.^[7] The improper offset would unbalance the arm of the abduction muscle, to weaken the strength, increase the pressure of the hip joint, and accelerate the wear of prosthesis.^[8] Moreover, the investigations of association between the approaches and the postoperative LLD and offset are limited.

A variety of approaches were applied in THA with reported,^[9] while anterolateral approach (ALA) and posterolateral approach (PLA) are the two common approaches.^[10] The ALA was performed through the gluteus medius, which was associated with increased hip load, decreased the dislocation rates,^[11] and reduced length of stay (LOS).^[12,13] Currently, the PLA remains the most commonly used in the United States, with an excellent exposure view by damaging joint capsule with shorter duration, lower intraoperative fracture, and higher risk of dislocation.^[14] Overall, the efficacy and comparison between the approaches and the postoperative LLD and offset has not been sufficiently investigated with controversial findings. In the present study, we, therefore, aimed to investigate the possible association and comparison between the approaches (ALA and PLA) and postoperative LLD and offset in selective THAs.

PATIENTS AND METHODS

This single-center, retrospective cohort study was conducted at Peking University Shenzhen Hospital, Department of Bone and Joint Surgery between April 2021 and July 2021. A total of 266 patients (126 males, 140 females; mean age: 46.7±13.6 years; range, 22 to 60 years) who underwent unilateral primary THA via the ALA or the PLA were consecutively included and divided into two groups as the ALA group (n=66) and the PLA group (n=200). Since radiographic evaluation is probably unreliable for femoral neck fracture (FNF) patients, only patients who were diagnosed as hip osteoarthritis (HOA), inflammatory arthritis, developmental dysplasia of the hip (DDH), and aseptic avascular necrosis (AVN) were recruited.

Patients who underwent bilateral THA, failed to understand or signed the consent, lost to follow-up or missed information, or obtained unqualified hip radiographs were excluded. Moreover, a total of 21 patients with insufficient medical records were also excluded. The study flowchart is shown in Figure 1.

Substantially, all the THA cases included in the study were performed by the same experienced team in our joint reconstruction center, which performed both the ALA and PLA routinely for over 15 years. As accumulative evidence revealed no significant difference between PLA and ALA in terms of midterm sports participation and functional scores after THA,^[15] the choosing of surgical approaches for primary THA depends mostly on the patients' individual characteristics and surgeons' personal preference.^[16] Retrospectively, the PLA was more popular (for 3/4 of all cases) in our center, while the ALA was specially considered for one-fourth of all cases. The ALA would more likely be chosen for specific cases predisposed to a higher risk of posterior hip dislocation postoperatively, cases with sarcopenia due to aging and immobility, and cases with obvious hip flexion deformity (allowing for more eases of intraoperative anterior tissue releasing with ALA). Risks of dislocation were mitigated, and corresponding measures (e.g., patient education and rehabilitation) were taken timely.^[17] All cases were scheduled for clinical and radiological follow-up routinely.

Variables

To ensure the highest level of accuracy, all data were gathered manually from the medical records, operation notes, and radiology reports retrospectively.^[18] Baseline demographic information including sex, age, height, weight, body mass index (BMI), marital status, hospital costs, LOS, and American Society of Anesthesiologists (ASA) score.^[3] The diagnosis was categorized as HOA, rheumatoid arthritis (RA), AVN, and DDH. Radiographic outcomes including the postoperative LLD, femoral offset (FO), acetabular offset (AO), and global offset (GO).^[19] The LOS was defined as the time between the admission date and the discharge date.^[20]

Surgical procedure

All patients underwent THA through a standard institutional protocol, who were admitted and scheduled for selective THA. The patients were not allowed to be discharged until they met mobilization targets. Laminar air flow, sterile helmets, disposable theatre caps, and body exhaust suits were applied

in standard operating theaters. Upon the evolution of less invasive procedures, faster and less painful recovery with fewer postoperative precautions could be applied.

The design of the implants, the use of screws in the acetabular component, the shape of the femoral stem, and the lipped or face-changing liners were primary variables affecting the choice of approach and components in our center. Head sizes were evaluated after the plain radiology examination was completed. The ALA was performed in the supine position by detaching the gluteus medius and one-third of the minimus to reach the hip joint in a specialized traction table. A cementless acetabular component and a cementless proximally porous-coated femoral component were placed. Then, the muscle detached after insertion of the prosthesis was repaired properly. The vertical iliofemoral ligament, conjoint tendon, and anterior capsule were preserved. The PLA was performed in the decubitus position.

Then, the short external rotators were dissected and the femoral heads were removed. Finally, a cementless acetabular component and a cementless proximally porous-coated femoral component were placed. The short external rotators were repaired by suturing with the greater trochanter while the posterior capsule was sutured, as well. Weight-bearing was allowed on the first day after the THA for all patients either in the ALA or the PLA.

Radiological assessment

Plain radiographs were performed perioperatively in the anteroposterior and lateral positions for both hip joints routinely for THA patients and archived in the Picture Archiving and Communication System (PACS) (Tomorrow Medical Network Science and Technology, Ningbo, Zhejiang, China). These historical radiographs retrieved from the PACS were evaluated by senior surgeons to confirm the qualification otherwise a new one would be filmed. The LLD was measured

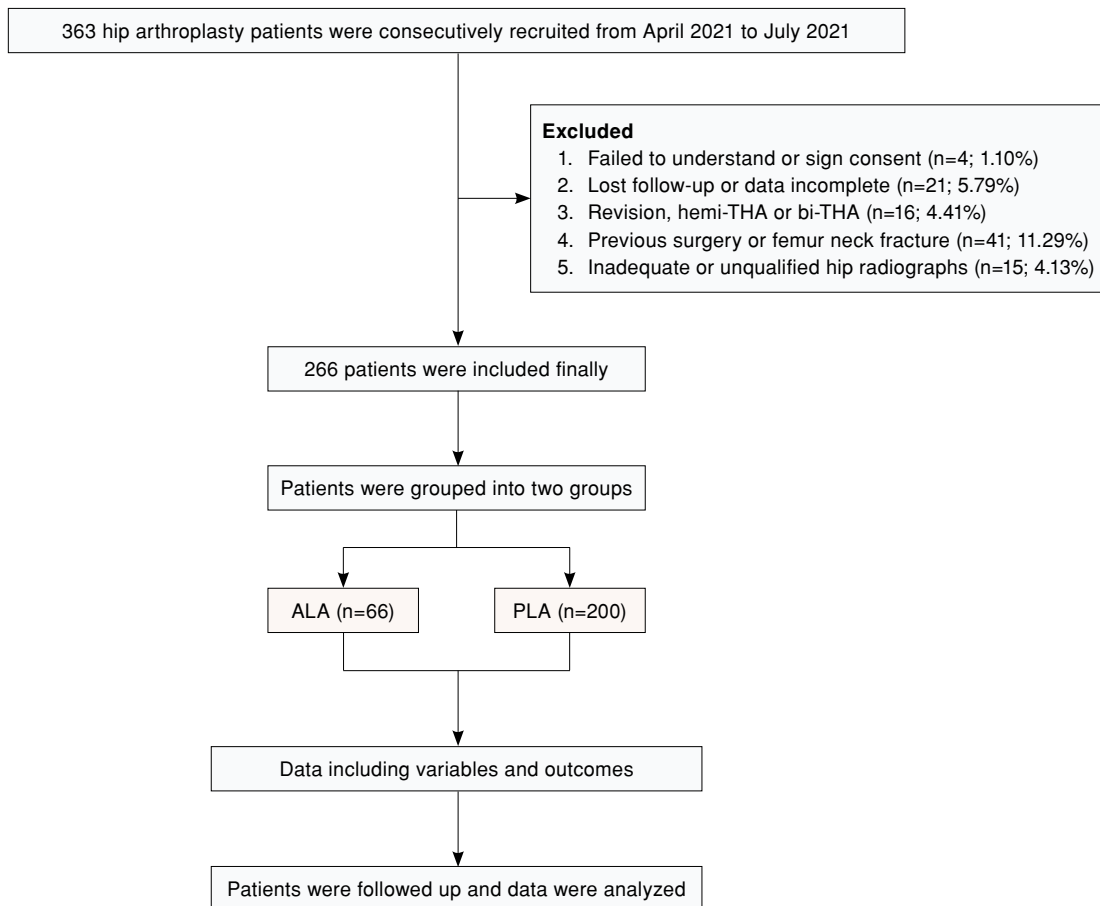


FIGURE 1. Study flowchart.
THA: Total hip arthroplasty.

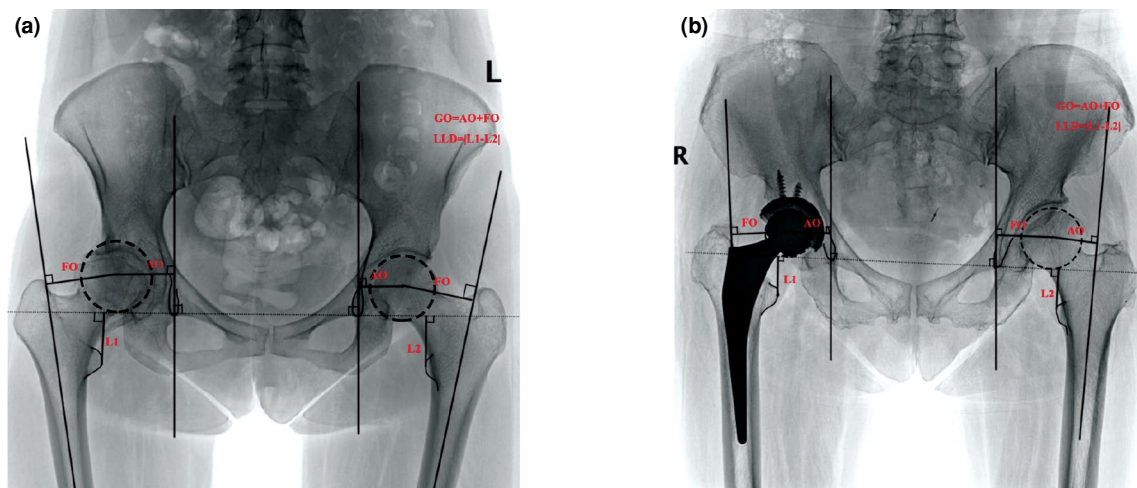


FIGURE 2. Illustrative (a) preoperative and (b) postoperative anteroposterior pelvic radiograph.

between both the teardrop lines to the lesser trochanter base, the absolute value represented the distance of the THA side compared to the untreated side as described previously.^[21] The FO was defined as the distance between the center of rotation (COR) to the femoral axis. The AO was defined as the distance between the COR to the tear drop axis (Figure 2). The GO was measured as the distance between the FO (the femur longitudinal axis to the COR) plus AO (the distance from the COR to a vertical line of the medial edge of the ipsilateral teardrop point of the pelvis).^[2] To reduce the bias of measurements, all radiographic variables were measured and recorded as continuous variables by two independent observers with a standardized process. Inter- and intra-observer reliabilities of the aforementioned radiological measurements were evaluated. The extraction differences, if existing, were resolved by discussing with a third party and the data were independently extracted.

Statistical analysis

Statistical analysis was performed using the R software version 4.0.2 (R Foundation for Statistical Computing, Vienna, Austria).^[22] The Student t-test was applied for normally distributed continuous variables, while the Mann-Whitney U test was performed for non-normally distributed continuous variables. Continuous variables were expressed in mean \pm standard deviation (SD), while categorical variables were expressed in number and frequency. The chi-square test or Fisher exact test was applied to analyze categorical variables. Univariate analysis was used to examine the relationship of postoperative clinical outcomes, while multivariate

linear regression analysis was performed to examine the significant factors on postoperative LLD. The variables including age, sex, BMI, diagnosis, and preoperative LLD were adjusted during the analysis. A two-sided *p* value of 0.05 was considered statistically significant.

RESULTS

This study included a total of 266 patients with a mean follow-up of 20 ± 3.7 (range, 16 to 25) months. Three cases had dislocation in the PLA group, but they were cured with the conservative treatment. No dislocation case occurred in the ALA group. No other postoperative complications (periprosthetic fracture or infection) or readmission during the follow-up period were reported in either group. All patients obtained satisfactory hip function and normal muscle strength at the final follow-up.

The demographic characteristics were comparable between both groups including baseline variables and preoperative LLD ($p > 0.05$), except for sex and age ($p < 0.01$) (Table I). The mean preoperative LLD was measured as 13.4 ± 17.5 mm and 12.2 ± 14.9 mm in the ALA group and the PLA group, respectively ($p > 0.05$). The number of DDH patients was 59 and 22 in the PLA and the ALA group, respectively.

Compared to the PLA group, significant decreases of postoperative LLD (95% confidence interval [CI]: -6.73 to -2.49 mm), postoperative acetabular offset (95% CI: -4.78 mm to -1.43 mm), and hospital costs (95% CI: -2,987.80 USD to -906.84 USD) in the ALA group were identified in the univariate

TABLE I
Demographic of patients between the ALA and the PLA group (n=266)

Variables	ALA group (n=66)			PLA group (n=200)			p
	n	%	Mean±SD	n	%	Mean±SD	
Age (year)			53.9±14.0			44.3±12.7	<0.01**
Sex							0.03*†
Female	43	65.15		97	48.50		
Male	23	34.85		103	51.50		
Height (m)			1.6±0.1			1.6±0.1	0.089
Weight (kg)			59.6±10.5			61.1±11.5	0.337
Body mass index (kg/m ²)			22.7±2.7			22.7±3.5	0.986
Marriage							0.712‡
Single	18	27.27		48	24.00		
Couple	48	72.73		152	76.00		
Diagnosis							0.727‡
Hip osteoarthritis	10	15.15		39	19.50		
Developmental dysplasia of the hip	22	33.33		59	29.50		
Inflammatory	3	4.55		6	3.00		
Aseptic vascular necrosis	31	46.97		96	48.00		
ASA score							0.329‡
1	29	43.94		108	54.00		
2	35	53.03		87	43.50		
3	2	3.03		5	2.50		
Preoperative LLD (mm)			13.4±17.5			12.2±14.9	0.609

ALA: Anterolateral approach; PLA: Posterior lateral approach; SD: Standard deviation; ASA: American Society of Anesthesiologists; LLD: Leg length discrepancy; * p<0.05; ** p<0.01; † Pearson chi-square test; ‡ Fisher exact test.

analysis. However, the LOS, postoperative FO, and postoperative GO were comparable between both groups (p>0.05) (Table II).

The multivariate analysis revealed that the PLA ($\beta=4.71$; 95% CI: 1.78 to 7.64), preoperative LLD ($\beta=0.29$; 95% CI: 0.21 to 0.37), DDH ($\beta=5.01$; 95% CI: 1.47 to 8.55) and AVN ($\beta=3.81$; 95% CI: 0.50 to 7.12) were substantial contributors to the postoperative LLD.

However, no significant differences were observed among age ($\beta=-0.02$; 95% CI: -0.11 mm to 0.08 mm), male ($\beta=-1.38$, 95% CI: -3.84 mm to 1.08 mm), and BMI ($\beta=0.30$, 95% CI: -0.08 mm to 0.67 mm) (Table III).

Regression curve of postoperative discrepancy between the two groups is displayed in Figure 3a. Obviously, there was lower postoperative LLD in the ALA group than that in the PLA group (p<0.01).

TABLE II
Analysis of postoperative parameters between the ALA and the PLA group (n=266)

Parameters	ALA (n=66)	PLA (n=200)	t value	95% CI	p
	Mean±SE	Mean±SE			
Costs (USD)	14091.9±3046.4	16039.2±5247.8	-3.69	-2987.80, -906.84	<0.01**
LOS (day)	15.6±8.3	17.6±6.2	-1.77	-4.17, 0.24	0.080
Postoperative LLD (mm)	6.4±8.19	11.0±11.7	-4.29	-6.73, -2.49	<0.01**
Postoperative FO (mm)	8.1±6.9	10.0±9.6	-1.73	-4.03, 0.26	0.084
Postoperative AO (mm)	6.0±5.2	9.1±7.9	-3.66	-4.78, -1.43	<0.01**
Postoperative GO (mm)	11.2±8.2	13.8±14.0	-1.84	-5.41, 0.18	0.067

ALA: Anterolateral approach; PLA: Posterior lateral approach; SE: Standard error; CI: Confidence interval; USD: US dollar; LOS: Length of stay; LLD: Leg length discrepancy; FO: Femoral offset; AO: Acetabular offset; GO: Global offset; * p<0.05; ** p<0.01.

TABLE III
Multivariate linear regression analysis of postoperative LLD (n=266)

Variables	β	S.E	t Value	95% CI	p
Age	-0.02	0.05	-0.39	-0.11, 0.08	0.694
Sex					
Female				(Reference)	
Male	-1.38	1.25	-1.10	-3.84, 1.08	0.271
Body mass index	0.30	0.19	1.54	-0.08, 0.67	0.126
Diagnosis					
Hip osteoarthritis				(Reference)	
Developmental dysplasia of the hip	5.01	1.79	2.79	1.47, 8.55	<0.01**
Inflammatory	3.37	3.63	0.93	-3.78, 10.53	0.354
Avascular necrosis;	3.81	1.68	2.27	0.50, 7.12	0.024*
Approach					
Anterolateral approach				(Reference)	
Posterior lateral approach	4.71	1.48	3.17	1.78, 7.64	<0.01**
Preoperative LLD	0.29	0.04	7.34	0.21, 0.37	<0.01**

LLD: Leg length discrepancy; S.E: Standard error. CI: Confidence interval; * $p < 0.05$; ** $p < 0.01$.

The regression curves diagnosis and BMI between the two groups are shown in Figure 3b and Figure 3c. Regression curves of preoperative offset and postoperative offset [(a) AO, (b) FO, and (c) GO] (Figure 4) revealed that they were comparable between the ALA group and the PLA group.

DISCUSSION

The present study primarily compared the association between the ALA and PLA with the postoperative LLD and offset. Our study results suggested that the ALA might be superior to the PLA in controlling the postoperative LLD among selective unilateral primary THA. However, the restoration of offset and LOS were comparable and both approaches achieved satisfactory function during follow-up.

Our main finding is that the ALA might be superior to the PLA in controlling postoperative LLD. Both the ALA and the PLA were performed with excellent visualization for component positioning with great anatomic success, but were easily extensible if complications occur,^[23] which might result in different complications such as improper offset or LLD; however, neither has been proven to be superior yet. In principle, the ALA using a neutral nervous and muscular plane, leads to less muscle and tendon trauma, less pain, and improved functional outcomes. In the current study, the univariate analysis revealed that postoperative LLD was significantly lower and

more stable in the ALA group than the PLA group over 20 months postoperatively ($p < 0.05$). Notable relationships between discrepancy and approaches were reflected with a higher discrepancy in the PLA group ($\beta = 4.71$; 95% CI: 1.78 to 7.64), which is highly consistent with earlier studies.^[24] A previous study demonstrated that the accurate reconstruction of biomechanical parameters related to the postoperative discrepancy was critical to ensure a long-term success.^[25] Nevertheless, postoperative discrepancies may necessitate subsequent interventions and current methods inaccurate or expensive. Intelligent HIP smart tool provides an accurate and real-time intraoperative leg length measurements.^[26] Both robot-assisted posterior approach, fluoroscopy-guided anterior approach, and conventional posterior approach can obtain minimal LLD, indicating that they can achieve accuracy in LLD well.^[27] Special-designed prostheses,^[28] surgeon-controlled table, and advanced fluoroscopic imaging techniques^[29] can improve the biomechanical and physiological hip reconstruction, which subsequently enhance the radiographic and clinical outcomes.

Interestingly, both the ALA and the PLA were comparable in restoring the postoperative offset. The offset parameters have significant impacts on the postoperative function rehabilitation. Preoperative templating and the proper intraoperative verification were helpful to achieve

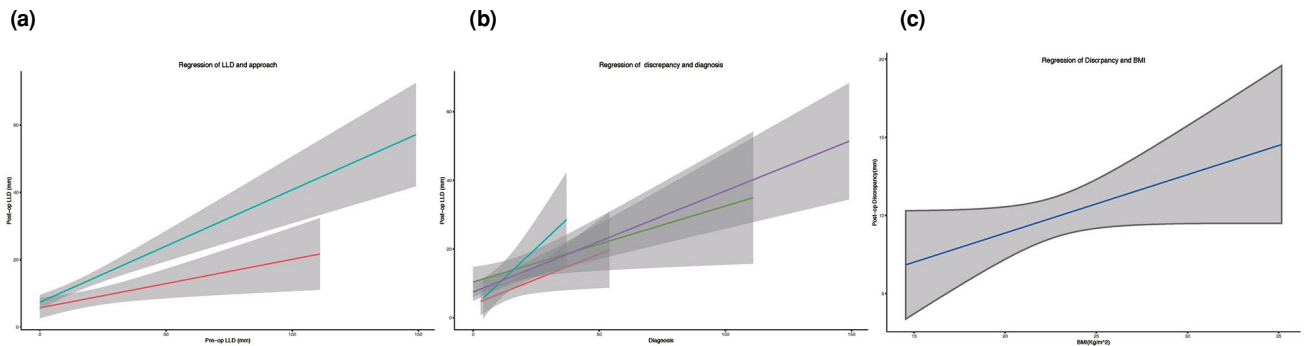


FIGURE 3. Regression curves of postoperative discrepancy and (a) preoperative LLD, (b) diagnosis and (c) BMI.

an accurate offset restoration, yielding a better abductor strength, as well as a long-term successful prognosis, which is consistent with the general investigations.^[30,31] Tendon and capsular releases that comprise a standard part of in the PLA may be responsible for the higher dislocation rate and exposure, which may be more challenging in leading to component malposition. Our results showed that the mean age of the participations was higher in the ALA group, but the postoperative offset was lower in the PLA group, suggesting that the ALA could be a better and safer choice in terms of the restoration of offset.

Developmental dysplasia of the hip represents abnormalities of both acetabulum and femur, requiring special techniques to reconstruct its physiological biomechanical.^[32] Our data indicated that DDH was a significant contributor and tended to yield higher postoperative LLD. A similar study showed that postoperative LLD was one of potential complications for DDH.^[33] The PLA would split the abductor muscles, which may cause limping, with a higher historical dislocation rate. However,

the ALA is performed with the patient supine and exploits a natural plane between muscles to theoretically reduce these complications. Anatomical abnormalities, massive soft tissue release, and poor bone stock increase the risk of postoperative LLD. Moreover, the preoperative discrepancy and offset may result from an improper position of the femoral stem and acetabular cup. Special thinner and shorter stems with more non-sprouted sleeves may be more suitable.^[34,35] Previous studies have demonstrated that external obturator footprint, robotic-assisted intervention, gait training, and three-dimensional-printed individual templates provide personal plan to improve the prognosis for DDH patients.^[36,37] Arthroplasty surgeons are, therefore, advised to pay more attention to the perioperative plan in consideration of high risk of postoperative LLD.

The ALA seems to cause less soft tissue damage than the PLA group with comparable outcomes. One of the main advantages of the ALA is that the functional integrity of the gluteus medius can be maintained with shorter rehabilitation period and fast recovery of function. The ALA was a modified Watson-

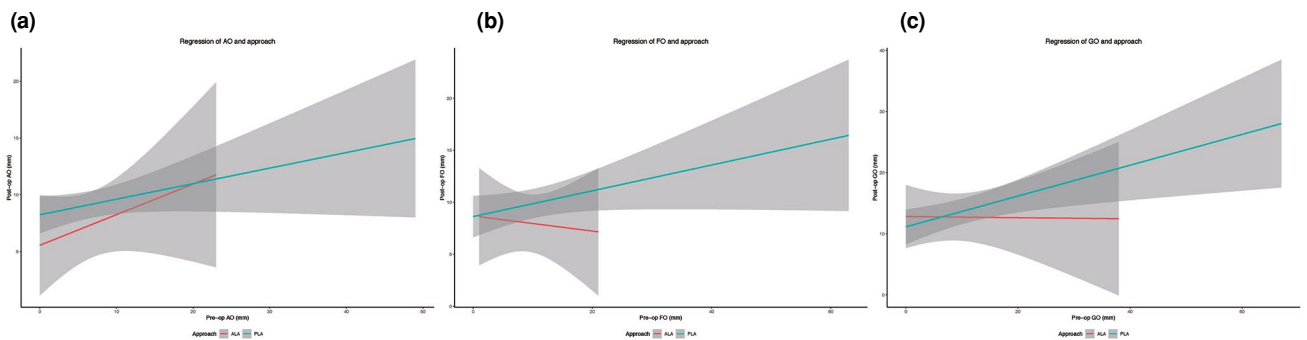


FIGURE 4. Regression curves of preoperative offset and postoperative offset (a) AO, (b) FO and (c) GO. AO: Acetabular offset; FO: Femoral offset; GO: Global offset.

Jones approach that utilized the interval between the tensor fascia and the gluteus medius muscles, without incising or detaching muscles or tendons.^[38] As for comparison clinically and radiologically via the direct anterior approach (DAA) and PLA, Godoy-Monzon et al.^[39] showed better functional recovery and pain control and shorter LOS in the DAA group, but with a greater complication rate in the DAA group. A previous study showed that joint degeneration was associated with the weight of patients.^[40] Moreover, our results revealed that the BMI was not a significant contributor to the LLD ($\beta=0.30$, 95% CI: -0.08 mm to 0.67 mm), while an increased discrepancy was noticed in patients with higher BMI values. Therefore, weight control may still be helpful for patients before elective THAs. Nonetheless, further studies are necessary to identify such possible beneficial effects of weight controlling strategy. Of note, all approaches to the hip have been shown to be safe and efficacious, and each has merits and demerits. The ideal approach should be reliable, allow functional recovery, and generate few complications, particularly.

There are several limitations to this study. First, the retrospective design of the study might not allow us to draw conclusive statements. However, we ensured the accuracy of the data collection by reviewing all the available electronic records manually, despite without a prospective database. Furthermore, we maintained a degree of standardization, as the study was performed in a single center with uniform protocols for rehabilitation and discharge planning. Second, patient variation of intergroup was observed, which seems as an unbalanced group (PLA=200 *vs.* ALA=66) with what appears to be predominantly DDH (81/266, ALA=22, PLA=59). The difference of the outcomes between the ALA and the PLA could be detected with small sample, and we may speculate that the approach plays their roles as well. Third, the sample is small and the follow-up is relatively short; however, the sample may be increased with the increase in the number of participants. More studies with high-level evidence are needed to confirm these findings. Finally, we did not include all possible comparable parameters such as patient-reported outcome measures or long-term survivorship after THA. Nonetheless, to the best of our knowledge, this is one of the studies to compare postoperative LLD and offset between the ALA and the PLA without the use of a registry database excluding any data inaccurate or unreliably. Taken together, the detailed comparison and analysis of radiographic data were reliable,

which were performed in a standard manner by a single, highly experienced surgeon team.

In conclusion, our study is one of the non-registry comparisons of surgical approach for THA investigating postoperative LLD and restoration of the offset. Our study results show that the ALA may be superior to the PLA in controlling postoperative LLD among selective THAs. Both ALA and the PLA are comparable regarding the restoration of the offset and LOS. Moreover, the current study provides a realistic evaluation and comparison for the surgeons to select the approach based on their expertise and experience. Future investigations are required to provide convincing favorable evidence to compare the ALA and PLA in primary THA.

Ethics Committee Approval: The study protocol was approved by the Peking University Shenzhen Hospital Ethics Committee (date: 03.04.2020, no: 2020013). The study was conducted in accordance with the principles of the Declaration of Helsinki.

Patient Consent for Publication: A written informed consent was obtained from each patient.

Data Sharing Statement: The data that support the findings of this study are available from the corresponding author upon reasonable request.

Author Contributions: Investigation, writing, editing: A.X.; Investigation, methodology, data curation, writing, editing: G.L.; Data curation: Y.C.; Methodology, review, editing: C.X.; Investigation, methodology, data curation: S.L., J.W., F.Y.; Investigation, conceptualization, review, editing: L.G.; Investigation, methodology, supervision: D.W.; Supervision, funding acquisition, resources, review: H.Z.

Conflict of Interest: The authors declared no conflicts of interest with respect to the authorship and/or publication of this article.

Funding: This study was supported by grants from National Natural Science Foundation of China (No.82172432, No.82102568, and No.82001319), Guangdong Basic and Applied Basic Research Foundation (No.2019A1515011290 and No.2021A1515012586), Shenzhen Key Medical Subject (No.SZ XK023), Shenzhen "San-Ming" Project of Medicine (No.SZSM201612092), Scientific Research Foundation of Peking University Shenzhen Hospital research (No. KYQD2021099).

REFERENCES

1. Gao L, Han Z, Xiong A. Total hip arthroplasty or hemiarthroplasty for hip fracture. *N Engl J Med* 2020;382:1072-3.
2. Viamont-Guerra MR, Saffarini M, Laude F. Surgical technique and case series of total hip arthroplasty with the Hueter anterior approach for Crowe type-IV dysplasia. *J Bone Joint Surg [Am]* 2020;102(Suppl 2):99-106.
3. Petersen WP Jr, Teo GM, Friedlander S, Schwarzkopf R, Long WJ. The implications of aging population demographics on the delivery of primary total joint arthroplasty in a bundled payment system. *J Bone Joint Surg [Am]* 2020;102:1679-86.

4. Alp NB, Akdağ G, Erdoğan F. Long-term results of total hip arthroplasty in developmental dysplasia of hip patients. *Jt Dis Relat Surg* 2020;31:298-305.
5. Atik OŞ. Is bone quality crucial in arthroplasty of the joints? *Jt Dis Relat Surg* 2021;32:824.
6. Warschawski Y, Garceau SP, Joly DA, Kuzyk P, Gross A, Safir O. The effect of femoral head size, neck length, and offset on dislocation rates of constrained acetabular liners. *J Arthroplasty* 2021;36:345-8.
7. Thorne TJ, Nishioka ST, Andrews SN, Mathews KA, Nakasone CK. Comparison of component placement accuracy using two intraoperative fluoroscopic grid technologies during direct anterior total hip arthroplasty. *J Arthroplasty* 2020;35:3601-6.
8. Krueger DR, Guenther KP, Deml MC, Perka C. Mechanical failure of 113 uncemented modular revision femoral components. *Bone Joint J* 2020;102-B:573-9.
9. Meermans G, Konan S, Das R, Volpin A, Haddad FS. The direct anterior approach in total hip arthroplasty: A systematic review of the literature. *Bone Joint J* 2017;99-B:732-40.
10. Brun OL, Sund HN, Nordsletten L, Röhrli SM, Mjaaland KE. Component placement in direct lateral vs minimally invasive anterior approach in total hip arthroplasty: Radiographic outcomes from a prospective randomized controlled trial. *J Arthroplasty* 2019;34:1718-22.
11. Wirries N, Ezechieli M, Floerkemeier T, Windhagen H, Skutek M. Proceeding from direct lateral to anterolateral approach in total hip arthroplasty: A closer look on radiological and clinical aspects. *J Orthop* 2020;21:10-3.
12. Shigemura T, Murata Y, Yamamoto Y, Shiratani Y, Hamano H, Wada Y. Minimally invasive anterolateral approach versus lateral transmuscular approach for total hip arthroplasty: A systematic review and meta-analysis. *Surgeon* 2022;20:e254-e261.
13. Ukai T, Ebihara G, Watanabe M. Comparison of short-term outcomes of anterolateral supine approach and posterolateral approach for primary total hip arthroplasty: A retrospective study. *J Orthop Traumatol* 2021;22:6.
14. Stangl-Correa P, Stangl-Herrera W, Correa-Valderrama A, Ron-Translateur T, Cantor EJ, Palacio-Villegas JC. Postoperative failure frequency of short external rotator and posterior capsule with successful reinsertion after primary total hip arthroplasty: An ultrasound assessment. *J Arthroplasty* 2020;35:3607-12.
15. Bonnin MP, Fessy MH, Van Rooij F, Nover L; Artro Institute, Ait-Si-Selmi T. No differences in midterm sports participation or functional scores after total hip arthroplasty by posterolateral vs anterolateral approach. *J Arthroplasty* 2020;35:3656-60.
16. Higgins BT, Barlow DR, Heagerty NE, Lin TJ. Anterior vs. posterior approach for total hip arthroplasty, a systematic review and meta-analysis. *J Arthroplasty* 2015;30:419-34.
17. Rowan FE, Benjamin B, Pietrak JR, Haddad FS. Prevention of dislocation after total hip arthroplasty. *J Arthroplasty* 2018;33:1316-24.
18. Martinkovich SC, Trott GL, Garay M, Sewecke JJ, Sauber TJ, Sotereanos NG. Patient characteristics and surgical start time affect length of stay following anterior total hip arthroplasty. *J Arthroplasty* 2020;35:2114-8.
19. Taunton MJ, Trousdale RT, Sierra RJ, Kaufman K, Pagnano MW. John Charnley award: Randomized clinical trial of direct anterior and minimiposterior approach THA: Which provides better functional recovery? *Clin Orthop Relat Res* 2018;476:216-29.
20. Frisch NB, Courtney PM, Darrith B, Copeland LA, Gerlinger TL. Veterans undergoing total hip and knee arthroplasty: 30-day outcomes as compared to the general population. *J Am Acad Orthop Surg* 2020;28:923-9.
21. Park CW, Lim SJ, Cha YT, Park YS. Total hip arthroplasty with subtrochanteric shortening osteotomy in patients with high hip dislocation secondary to childhood septic arthritis: A matched comparative study with Crowe IV developmental dysplasia. *J Arthroplasty* 2020;35:204-11.
22. Ihaka R, Gentleman R. R: A language for data analysis and graphics. *Journal of Computational and Graphical Statistics* 1996;5:299-314.
23. Pincus D, Jenkinson R, Paterson M, Leroux T, Ravi B. Association between surgical approach and major surgical complications in patients undergoing total hip arthroplasty. *JAMA* 2020;323:1070-6.
24. Mavčič B, Dolinar D, Pompe B, Antolič V. Patient-dependent risk factors for self-perceived leg length discrepancy after total hip arthroplasty. *Eur J Orthop Surg Traumatol* 2019;29:793-9.
25. Kishimoto Y, Suda H, Kishi T, Takahashi T. A low-volume surgeon is an independent risk factor for leg length discrepancy after primary total hip arthroplasty: A case-control study. *Int Orthop* 2020;44:445-51.
26. Grosso P, Snider M, Muir JM. A smart tool for intraoperative leg length targeting in total hip arthroplasty: A retrospective cohort study. *Open Orthop J* 2016;10:490-9.
27. Atik OŞ. Does the use of robotic technology in hip arthroplasty provide superior clinical outcomes? *Jt Dis Relat Surg* 2022;33:253-4.
28. Gabor JA, Singh V, Padilla JA, Schwarzkopf R, Davidovitch RI. Outcomes with two tapered wedge femoral stems in total hip arthroplasty using an anterior approach. *J Orthop* 2020;22:341-5.
29. Delagrammaticas DE, Ochenjele G, Rosenthal BD, Assenmacher B, Manning DW, Stover MD. Intraoperative evaluation of acetabular cup position during anterior approach total hip arthroplasty: Are we accurately interpreting? *Hip Int* 2020;30:40-7.
30. Kiernan S, Geijer M, Sundberg M, Flivik G. Effect of symmetrical restoration for the migration of uncemented total hip arthroplasty: A randomized RSA study with 75 patients and 5-year follow-up. *J Orthop Surg Res* 2020;15:225.
31. Enke O, Levy YD, Bruce WJ. Accuracy of leg length and femoral offset restoration after total hip arthroplasty with the utilisation of an intraoperative calibration gauge. *Hip Int* 2020;30:296-302.
32. Ohsawa S, Koide S, Shibuya T. Mid-term results of total hip arthroplasty for relapsed osteoarthritis after joint-preserving operations for coxarthrosis compared to primary total hip arthroplasty. *Eur J Orthop Surg Traumatol* 2021;31:299-308.
33. Shi XT, Li CF, Han Y, Song Y, Li SX, Liu JG. Total hip arthroplasty for Crowe type IV hip dysplasia: Surgical techniques and postoperative complications. *Orthop Surg* 2019;11:966-73.
34. Al-Amiry B, Mahmood S, Krupic F, Sayed-Noor A. Leg lengthening and femoral-offset reduction after total hip arthroplasty: Where is the problem - stem or cup positioning? *Acta Radiol* 2017;58:1125-31.

35. Ueoka K, Kabata T, Kajino Y, Inoue D, Ohmori T, Ueno T, et al. Patient-reported outcomes following primary total hip arthroplasty in Crowe type III or IV developmental dysplasia are comparable to those in Crowe type I: A case-control study of 96 hips with intermediate-term follow-up. *BMC Musculoskelet Disord* 2020;21:344.
36. Perets I, Walsh JP, Mu BH, Mansor Y, Rosinsky PJ, Maldonado DR, et al. Short-term clinical outcomes of robotic-arm assisted total hip arthroplasty: A pair-matched controlled study. *Orthopedics* 2021;44:e236-e242.
37. Yoo JI, Cha YH, Kim KJ, Kim HY, Choy WS, Hwang SC. Gait analysis after total hip arthroplasty using direct anterior approach versus anterolateral approach: A systematic review and meta-analysis. *BMC Musculoskelet Disord* 2019;20:63.
38. Takada R, Jinno T, Miyatake K, Hirao M, Yoshii T, Okawa A. Incidence of tensor fascia lata muscle atrophy after using the modified Watson-Jones anterolateral approach in total hip arthroplasty. *Eur J Orthop Surg Traumatol* 2021;31:533-40.
39. Godoy-Monzon D, Buttaro M, Comba F, Piccaluga F, Cid-Casteulani A, Ordas A. Comparative study of radiological and functional outcomes following a direct anterior approach versus to a posterolateral approach to the hip. *Rev Esp Cir Ortop Traumatol (Engl Ed)* 2019;63:370-5.
40. Okuzu Y, Goto K, Shimizu Y, Kawai T, Kuroda Y, Matsuda S. Sacroiliac joint degeneration is common in patients with end-stage hip osteoarthritis secondary to unilateral developmental dysplasia of the hip: Factors associated with its severity and laterality. *J Orthop Sci* 2021;26:135-40.