










# Spontaneous bilateral quadriceps tendon rupture treated with polyethylene terephthalate tape augmentation: Report of two consecutive cases

Antonio Bove, MD<sup>1</sup> , Nicola Orabona, MD<sup>1</sup> , Vincenzo De Matteo, MD<sup>1,2</sup> , Nunzia Salati, MD<sup>1</sup> ,  
Gennaro Di Matteo, MD<sup>2</sup> , Mustafa Citak, MD<sup>3</sup> , Adriano Braile, MD<sup>2,4</sup> 

<sup>1</sup>Department of Orthopaedic and Trauma Surgery, Ospedale Del Mare Hospital, Naples, Italy

<sup>2</sup>Department of Public Health, Orthopaedics and Traumatology, Federico II University of Naples, Naples, Italy

<sup>3</sup>Department of Orthopaedic Surgery, Helios ENDO-Klinik, Hamburg, Germany

<sup>4</sup>Department of Medical and Surgical Specialties and Dentistry, University of Campania Vanvitelli, Naples, Italy

The quadriceps femoris muscles (QMFs) form the largest human muscle and it transmits a high amount of forces. Quadriceps tendon (QT), therefore, is the terminal for transmitting high intensity forces and its structure is severely tested during daily, work and sport activities. Spontaneous rupture of QT is rare and it is commonly associated with systemic comorbidities, leading to tendon degeneration such as connective tissue disorders, chronic renal failure, rheumatoid arthritis, diabetes, hyperparathyroidism, gout and pharmacological treatments with fluoroquinolones and steroids.<sup>[1]</sup> While unilateral rupture is a

## ABSTRACT

Spontaneous rupture of quadriceps tendon (QT) is a rare condition and it is commonly associated with systemic comorbidities and medical products assumption, which may lead to tendon degeneration. While unilateral rupture is a quite common injury, spontaneous bilateral ruptures are very rare. Herein, we report two consecutive cases of spontaneous bilateral QT rupture in two patients with a positive history of chronic statin use, successfully treated with bilateral single-stage reconstruction with polyethylene-terephthalate tape augmentation. At 12 months of follow-up, both patients recovered the full extension, a 120° pain-free flexion and knee scores improvement. Magnetic resonance imaging at one year showed a complete, bilateral, bio-integration of the augmentation for each knee. In conclusion, polyethylene terephthalate tape augmentation provides a good structural support with a good grade of bio-integration, allowing a fast recovery.

**Keywords:** Augmentation, bilateral, quadriceps tendon rupture, reconstruction.

Received: June 30, 2022

Accepted: August 13, 2022

Published online: October 21, 2022

**Correspondence:** Vincenzo De Matteo, MD. Department of Orthopaedic and Trauma Surgery Ospedale del Mare, 80147 Naples, Italy.

E-mail: dematteovincenzo@gmail.com

Doi: 10.52312/jdrs.2022.764

**Citation:** Bove A, Orabona N, De Matteo V, Salati N, Di Matteo G, Citak M, et al. Spontaneous bilateral quadriceps tendon rupture treated with polyethylene terephthalate tape augmentation: Report of two consecutive cases. *Jt Dis Relat Surg* 2022;33(3):666-672.

©2022 All right reserved by the Turkish Joint Diseases Foundation

This is an open access article under the terms of the Creative Commons Attribution-NonCommercial License, which permits use, distribution and reproduction in any medium, provided the original work is properly cited and is not used for commercial purposes (<http://creativecommons.org/licenses/by-nc/4.0/>).

relatively common injury and it has been well reported,<sup>[2]</sup> spontaneous bilateral ruptures are very rare, and literature provides only few reports, in almost all cases treated with direct repair or autograft augmentation.<sup>[3]</sup>

In this article, we report two consecutive cases of spontaneous bilateral QT rupture successfully treated with bilateral single-stage reconstruction with polyethylene terephthalate tape augmentation (QuadsTape System™, Neoligaments™, Xiros Ltd, Leeds, UK).

## CASE REPORT

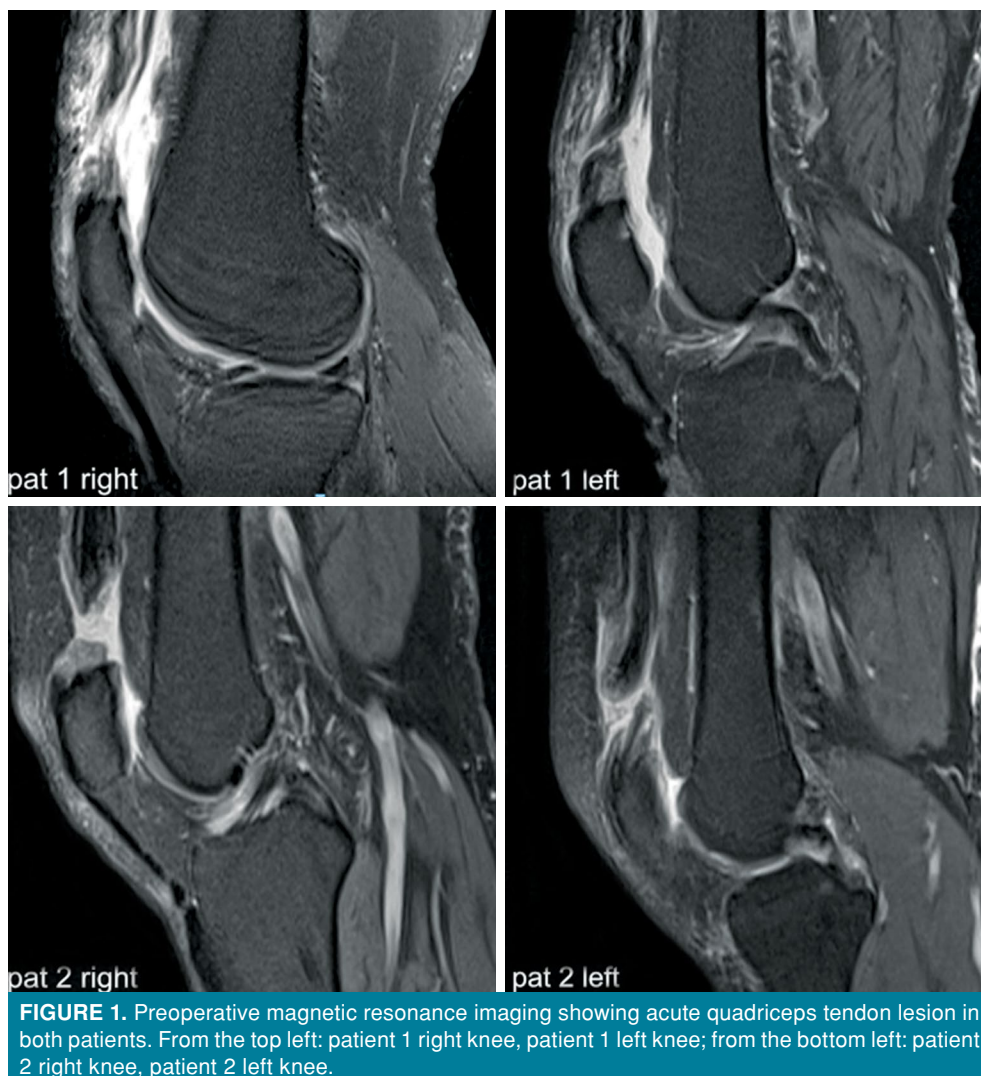Two consecutive cases of spontaneous bilateral QT rupture have come to our observation in January and April 2020. Both patients were males, aged 65 and 57 years old, with a clinical history of hypercholesterolemia treated with simvastatin for 15 and 10 years, respectively. No other comorbidities were found. The patients were clinically evaluated, as both referred pain and loss of function occurred suddenly, while climbing up the stairs in the first case and while walking uphill, without any other significative trauma.

During clinical observation, patients presented non-significant swelling in the area proximal to the patella, active flexion of the knee with inability to reach full active extension, inability to maintain the passively extended knee against gravity and

lameness. There was no significant pain on palpation, while the presence of an area of depression in the QT region was detected. The initial ultrasound examination was performed which documented the presence of an area of tendon lesion with the presence of hematoma confirmed by a magnetic resonance imaging (MRI) subsequently requested (Figure 1). The patients underwent surgical treatment after five and seven days from the trauma.

### Surgical technique

Surgical technique was the same for the two patients. The patient was positioned in supine position and the leg was appropriately supported by a side support and a silicone bag. The leg was prepared and draped for aseptic technique. Tourniquet was not used to avoid compression of the QMF and consequent shortening of the extensor



apparatus. We used a midline approach, as wide to provide sufficient exposure of the surgical area. After skin incision, a wide layer of scar tissue was debrided from the lesion and adhesions were removed. When debridement was completed, the lesion area appeared clearly and a loss of tendon tissue was observed (Figure 2a). The lack of viable tissue made primary repair not advisable, making necessary to perform an augmentation procedure. In both cases, a bilateral single-stage reconstruction with polyethylene terephthalate tape augmentation (QuadsTape System™, Neoligaments™, Xiros Ltd, Leeds, UK) was performed.

The first step was the placement of the polytape under the distal end of the patella at the junction with the patellar tendon. The polytape was, then, passed through an eyelet of a needle, used to place the tape through the proximal patellar tendon body. At this site, the tape was anchored at the patellar tendon by sutures. The two flaps of the tape were, then, crossed over the anterior aspect of the patella, trying to keep the tape as flat as possible to avoid formation of bumps (Figure 2b). At this step, the ends of the ruptured tendon were approximated, and the needle was used to pass through the distal and the proximal ends of the QT with a double “figure of X” configuration. Tension was, then, adjusted to remove any slackness and bump from the polytape. The configuration ends with the passage of the tape through the proximal

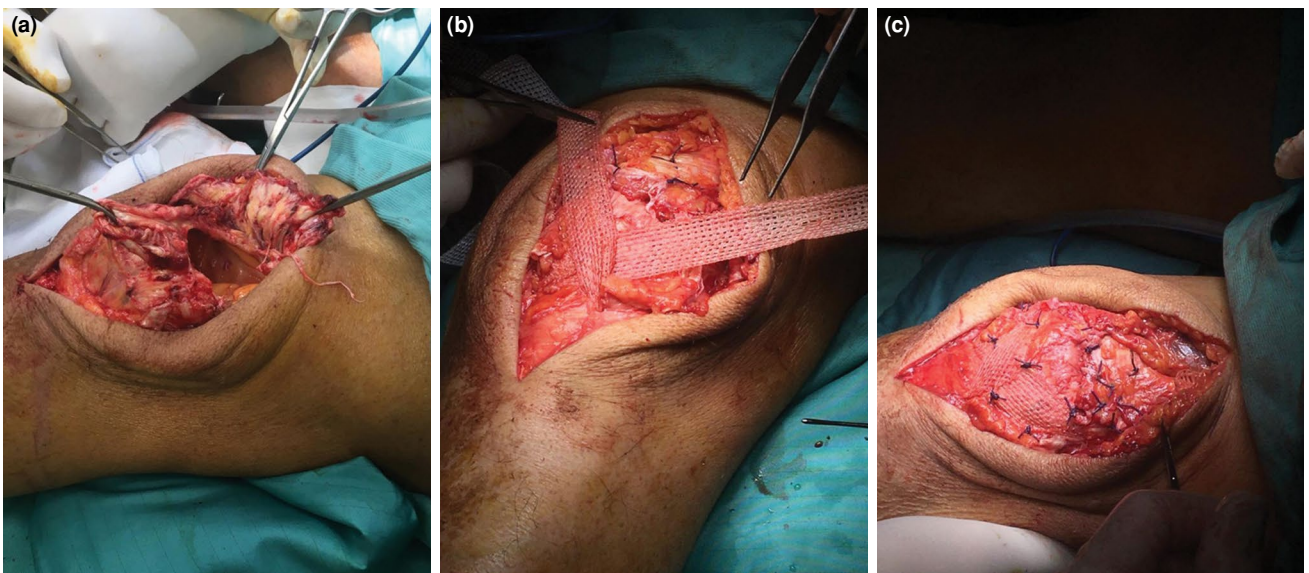
end of the QT. The repair construct was tensioned by cycling the knee five times from 0° to 90°. Sutures to fix the tape to the anterior aspect of the patella, the entrance and exit points at the tendon body were performed to complete the reconstruction (Figure 2c).

### Rehabilitation protocol

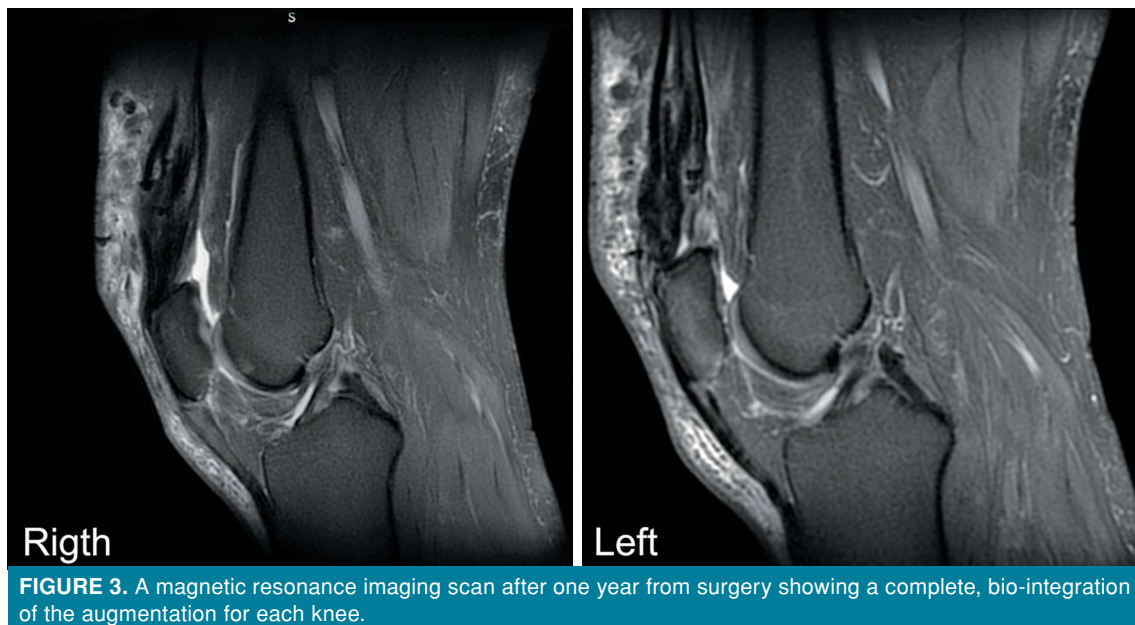
The patient was discharged with the brace fixed in full extension for two weeks, allowed to protected weight bearing with two crutches. During the first period, isometric exercises for QMF were prescribed. After two weeks, the range of motion (ROM) was gradually increased following this plan: 0-30° from Week 2 to Week 4, 0-60° from Week 4 to Week 6, and 0-90° from Week 6 to Week 8. After Week 8, the patient was allowed to full weight bearing with one crutch and to dismiss the brace. Active flexion of the knee was allowed six weeks after surgery and active extension after eight weeks. Rehabilitation in this phase targets on strengthening of the quadriceps muscle together with reinforcement of the proximal core musculature: gluteal muscles, paraspinal muscles and abdominal muscles and gait training. Training of the vastus medialis oblique (VMO) muscles plays a central role in all steps of the protocol to provide proper patellofemoral tracking.<sup>[4]</sup>

### Follow-up

At 12 months of follow-up, both patients recovered the full extension and a 120° pain-free



**FIGURE 2.** Intraoperative images of the surgical technique. See full text for further details. (a) Debridement and delimitation of the lesion. It is possible to observe a massive lack of viable tissue. (b) Placement of the poly tape at the junction with the patellar tendon. The two flaps of the tape are then crossed over the anterior aspect of the patella. (c) Approximation of the ends of the ruptured tendon, the poly-tape is passed through the distal and the proximal ends of the quadriceps tendon with a double “figure of X” configuration. Sutures to fix the tape to the anterior aspect of the patella.



flexion of the knees. The Lysholm Knee Scoring scale was applied to the patients, which showed 84% and 82%, respectively. Also, the International Knee Documentation Committee (IKDC) score was administered with a score of 67.8% and 50.6%, respectively. The Visual Analog Scale (VAS) scores were 2 and 4, respectively. The MRI scan performed after one year from surgery demonstrated a complete, bilateral, bio-integration of the augmentation for each knee (Figure 3). The results are summarized in Table I.

## DISCUSSION

### Epidemiology and risk factors

Spontaneous complete bilateral QT rupture is a rare and severely debilitating clinical condition, with only few cases reported in the literature.<sup>[4]</sup> Clayton and Court-Brown<sup>[5]</sup> reported an incidence of QT ruptures of 1.37/100.000/year with a mean age of

50.5 in men and 51.7 in women, associated with chronic conditions. In a recent systematic review conducted by Camarda et al.,<sup>[6]</sup> the main risk factors reported with bilateral spontaneous QT rupture were chronic renal failure followed by diabetes and obesity. Other acclaimed risks factors include autoimmune disease (i.e., systemic lupus), anabolic steroid use, hyperparathyroidism, gout and men over the age of 40 years.<sup>[7]</sup> The use of fluoroquinolone in healthy individuals who develop spontaneous bilateral QT is also another case of risk factor reported in the literature during recent years.<sup>[8]</sup>

### Statins-use related risk

Statins (3-hydroxy-3-methylglutaryl-coenzyme A reductase inhibitors) are commonly used as anti-hyperlipidemic agents in medical daily practice for the most effective therapeutic modalities for reducing cholesterol and low-density lipoprotein serum levels. Different musculoskeletal

**TABLE I**  
Results

Patient	VAS	Lysholm score (%)	IKDC score (%)	ROM			
				Right knee		Left knee	
				Flexion (°)	Extension (°)	Flexion (°)	Extension (°)
1	2	84	67.8	120	0	125	0
2	4	82	50.6	120	0	120	0

VAS: Visual Analog Scale; IKDC: International Knee Documentation Committee; ROM: Range of motion.

complications such as pain, rhabdomyolysis, myopathies and tendonitis are well known, but tendon rupture associated with statin therapy is rare.<sup>[9]</sup> We found only three reports of single spontaneous bilateral QT associated with use of statin.<sup>[10-12]</sup> Marie et al.<sup>[13]</sup> conducted the first large study of tendon ruptures associated with statin use and observed that the ruptures begun with statin use and improved with discontinuation of the therapy; moreover, the effect of statins on tendon ruptures did not appear to be dose-dependent. The average time to onset of tendinous complication after starting therapy was eight months and 95% experienced symptoms within the first year; after the therapy was suspended, patients reported an improvement in symptoms after a median time of 23 days, receiving analgesics, immobilization and/or daily life activity modification. Moreover, 38% of the cohort were diagnosed with severe symptoms and 18% of them required hospitalization. It is important to highlight that the restoration of therapy resulted in a recurrence of symptoms in all patients. Also, Beri et al.,<sup>[14]</sup> in a case-control study over six years, showed that statin exposure was a significant risk factor for tendon rupture in women and no association with other causes, including dose or duration of the therapy, was reported. Atorvastatin was the most commonly used statin by patients who suffered from a tendon rupture. In our experience, there were no such risk factors except for long-term statin use.

Currently, the exact mechanism of tendon injury associated with statins is unknown, although several theories have been proposed.<sup>[9]</sup> The most important theory is the impact on remodeling by the matrix metalloproteinases: the inhibition of this latter may interfere with tendon remodeling after microtrauma with resulting tendinopathy and, in some cases, rupture.<sup>[15]</sup>

Bilateral QT rupture is commonly associated, in the current literature, with falling down stairs or spontaneous rupture during walking activity.<sup>[16]</sup> In a revision performed by Shah,<sup>[17]</sup> 66 cases reported in the literature were analyzed and 41 cases (65%), were attributed to falls and missteps, and 22 cases (35%) occurred spontaneously while walking. Entity of the trauma in the cases caused by falling downstairs or falls and missteps; however, it did not justify the occurrence of bilateral rupture, furthermore etiology and pathophysiology of spontaneous ruptures still remain unclear. In this article, we report two consecutive cases of bilateral atraumatic spontaneous and simultaneous QT rupture without

any identifiable risk factors, except for the long-term statin use. In our experience, the prolonged use of statin may be a predisposing factor for bilateral spontaneous QT ruptures and, considering the prevalence of the use of this medication in the general population, this topic should be deepened with further studies.

### Surgical techniques

Several techniques have been proposed for reconstruction, since the first direct suture with silver wire described by McBurney and Pilvher,<sup>[18]</sup> including metalwork use, autograft, allograft,<sup>[19]</sup> fascial flaps, and synthetic augmentation.<sup>[20]</sup> The principal problem in reconstructing extensor mechanism rupture is to achieve an adequate protection of the suture allowing an early mobilization to avoid articular rigidity. In chronic lesions, the quality of the tissue is poor characterized by abnormal collagen distribution and increased production of type III collagen fibers by tenocytes,<sup>[21]</sup> with lower resistance to tensile forces and increased risk of rupture. The literature provides different choices of augmentation techniques, to face the challenge of achieving a satisfying QT reconstruction with autogenous graft, which is a suitable solution in young patients or allograft reconstruction.<sup>[22]</sup>

### Augmentation with synthetic ligaments

All the proposed techniques carry a high complication rate, including technical complexity and donor site morbidity, in case of autograft techniques, weakness of the repair and infection risk in case of allograft use, and lack of adequate strength observed in many synthetic ligaments.<sup>[23]</sup> Nevertheless, the use of synthetic ligaments shows good results in different articles, avoiding complications due to the autograft harvesting or the allograft implant. Fujikawa et al.<sup>[24]</sup> reported the use of the Leeds-Keio™ (Xiros Ltd., Leeds, UK) ligament in extensor mechanism reconstruction with excellent results. In addition, Toms et al.<sup>[23]</sup> observed good results in functional recovery and low complication rate in 12 knees of 11 patients.

The QuadsTape System™ (Neoligaments™, Xiros Ltd, Leeds, UK) is a 30-mm wide by 800 mm long polytape implant with an open-weave mesh structure made of polyethylene terephthalate (polyester) conceived as a cellular scaffold to be used in QT reconstruction. The device was developed from the predecessor Leeds-Keio™ ligament, adopted since 1982 (Figure 4).<sup>[25]</sup>

The Leeds-Keio™ graft, also known as polytapes (Xiros PLC., Neoligaments, Leeds, UK),



**FIGURE 4.** Leeds-Keio™ graft on the top side, QuadsTape System™ on the bottom.

is a non-absorbable synthetic polyester-ethylene-terephthalate prosthesis developed for tendon and ligament reconstruction by the University of Leeds and the Keio University. It was specifically designed for anterior cruciate ligament reconstruction, with a 60-cm in length tube-shape mesh with rectangular holes 1.5 to 2.5 mm<sup>2</sup> in area.

The QuadsTape System™ construct is non-absorbable woven mesh with longitudinal and transverse fibers crossing at right angles. Its open-structure is designed as an open weave polyester mesh, to act as a scaffold for soft tissue ingrowth and neoligament formation. Biological properties were investigated by Abdullah in an *in vitro* study showing growth of tenocytes and their migration at the site of the junction between the tendon and the scaffold in culture.<sup>[26]</sup> The device shows an excellent intrinsic strength that allows a good seal in tendons reconstruction allowing an early mobilization and it is simple to use, with a low learning curve.<sup>[23]</sup> Based on these characteristics, this device seems to be a valid option to face a simultaneous bilateral QT reconstruction, in which surgeon have to face a multiple problem, composed of the necessity to perform a valid suture, a good reconstruction of the degenerative area and of the lacking tendon tissue as well as a quick and satisfying ROM and functional activity recovery.

In conclusion, treatment of simultaneous bilateral QT rupture with polyethylene terephthalate tape augmentation, despite the small number of patients and mid-term follow-up in the literature provides a good structural support with a good grade of bio-integration, allowing a fast recovery. Surgical technique has a low learning curve, making of this

device an interesting and useful tool in the difficult challenge of QT reconstruction. However, further studies with larger cohorts are needed to confirm these data.

**Patient Consent for Publication:** A written informed consent was obtained from patient.

**Data Sharing Statement:** The data that support the findings of this study are available from the corresponding author upon reasonable request.

**Author Contributions:** Idea/concept: A.B., N.S.; Design: A.B., A.B.; Control/supervision: A.B., N.O., M.C.; Data collection and/or processing: A.B., A.B., G.D.M., N.S.; Analysis and/or interpretation: A.B., N.O., V.D.M., A.B.; Literature review: A.B., A.B., G.D.M., N.S.; Writing the article: A.B., A.B., V.D.M.; Critical review: M.C., N.O.; References and fundings: A.B., A.B.; Materials: N.S.

**Conflict of Interest:** The authors declared no conflicts of interest with respect to the authorship and/or publication of this article.

**Funding:** The authors received no financial support for the research and/or authorship of this article.

## REFERENCES

1. Okay E, Turgut MC, Tokyay A. Quadriceps reconstruction with suture anchor and Achilles allograft combination in quadriceps tendon re-rupture after primary surgical repair: A novel technique. *Jt Dis Relat Surg* 2021;32:798-803.
2. Rougraff BT, Reeck CC, Essenmacher J. Complete quadriceps tendon ruptures. *Orthopedics* 1996;19:509-14.
3. Atik OŞ. Which articles do the editors prefer to publish? *Jt Dis Relat Surg* 2022;33:1-2.
4. Langenhan R, Baumann M, Ricart P, Hak D, Probst A, Badke A, et al. Postoperative functional rehabilitation after repair of quadriceps tendon ruptures: A comparison of two different protocols. *Knee Surg Sports Traumatol Arthrosc* 2012;20:2275-8.
5. Clayton RA, Court-Brown CM. The epidemiology of musculoskeletal tendinous and ligamentous injuries. *Injury* 2008;39:1338-44.
6. Camarda L, D'Arienzo A, Morello S, Guarneri M, Balistreri F, D'Arienzo M. Bilateral ruptures of the extensor mechanism of the knee: A systematic review. *J Orthop* 2017;14:445-53.
7. Chiu M, Forman ES. Bilateral quadriceps tendon rupture: A rare finding in a healthy man after minimal trauma. *Orthopedics* 2010 [Epub 2010 Mar 10].
8. Glick R, Epstein DS, Aponso DT. Spontaneous bilateral quadriceps tendon rupture associated with norfloxacin. *Intern Med J* 2015;45:1313-5.
9. Deren ME, Klinge SA, Mukand NH, Mukand JA. Tendinopathy and tendon rupture associated with statins. *JBJS Rev* 2016;4:e4.
10. Celik EC, Ozbaydar M, Ofluoglu D, Demircay E. Simultaneous and spontaneous bilateral quadriceps tendons rupture. *Am J Phys Med Rehabil* 2012;91:631-4.
11. Rubin G, Haddad E, Ben-Haim T, Elmalach I, Rozen N. Bilateral, simultaneous rupture of the quadriceps tendon associated with simvastatin. *Isr Med Assoc J* 2011;13:185-6.

12. Nesselroade RD, Nickels LC. Ultrasound diagnosis of bilateral quadriceps tendon rupture after statin use. *West J Emerg Med* 2010;11:306-9.
13. Marie I, Delafenêtre H, Massy N, Thuillez C, Noblet C; Network of the French Pharmacovigilance Centers. Tendinous disorders attributed to statins: A study on ninety-six spontaneous reports in the period 1990-2005 and review of the literature. *Arthritis Rheum* 2008;59:367-72.
14. Beri A, Dwamena FC, Dwamena BA. Association between statin therapy and tendon rupture: A case-control study. *J Cardiovasc Pharmacol* 2009;53:401-4.
15. Gowdar SD, Thompson PD. Multiple tendon ruptures associated with statin therapy. *J Clin Lipidol* 2020;14:189-91.
16. Provelegios S, Markakis P, Cambouroglou G, Choumis G, Dounis E. Bilateral, spontaneous and simultaneous rupture of the quadriceps tendon in chronic renal failure and secondary hyperparathyroidism. Report of five cases. *Arch Anat Cytol Pathol* 1991;39:228-32.
17. Shah MK. Simultaneous bilateral rupture of quadriceps tendons: Analysis of risk factors and associations. *South Med J* 2002;95:860-6.
18. McBurney C, Pilvher J. II. Suture of the divided ends of a ruptured quadriceps extensor tendon with perfect recovery. *Annals of Surgery* 1887;6:170.
19. Leopold SS, Greidanus N, Paprosky WG, Berger RA, Rosenberg AG. High rate of failure of allograft reconstruction of the extensor mechanism after total knee arthroplasty. *J Bone Joint Surg [Am]* 1999;81:1574-9.
20. Miskew DB, Pearson RL, Pankovich AM. Mersilene strip suture in repair of disruptions of the quadriceps and patellar tendons. *J Trauma* 1980;20:867-72.
21. Maffulli N, Ewen SW, Waterston SW, Reaper J, Barrass V. Tenocytes from ruptured and tendinopathic achilles tendons produce greater quantities of type III collagen than tenocytes from normal achilles tendons. An in vitro model of human tendon healing. *Am J Sports Med* 2000;28:499-505.
22. Lamberti A, Balato G, Summa PP, Rajgopal A, Vasdev A, Baldini A. Surgical options for chronic patellar tendon rupture in total knee arthroplasty. *Knee Surg Sports Traumatol Arthrosc* 2018;26:1429-35.
23. Toms AD, Smith A, White SH. Analysis of the Leeds-Keio ligament for extensor mechanism repair: Favourable mechanical and functional outcome. *Knee* 2003;10:131-4.
24. Fujikawa K, Ohtani T, Matsumoto H, Seedhom BB. Reconstruction of the extensor apparatus of the knee with the Leeds-Keio ligament. *J Bone Joint Surg [Br]* 1994;76:200-3.
25. Matsumoto H, Fujikawa K. Leeds-Keio artificial ligament: A new concept for the anterior cruciate ligament reconstruction of the knee. *Keio J Med* 2001;50:161-6.
26. Abdullah S. Usage of synthetic tendons in tendon reconstruction. *BMC Proc* 2015;9(Suppl 3):A68.