









# Comparison of the radiological parameters between dynamic-referencing tactile guidance robotic system and Microplasty® instrumentation in unicompartmental knee arthroplasty

Haluk Çabuk, MD , Kaya Turan, MD , Osman Görkem Muratoğlu, MD , Tuğrul Ergün, MD ,  
Çağatay Öztürk, MD , Ramazan Erden Ertürer, MD 

Department of Orthopedics and Traumatology, İstinye University, İstanbul, Türkiye

Unicompartmental knee arthroplasty (UKA) is an effective treatment for anteromedial osteoarthritis of knee. It has certain advantages over total knee arthroplasty including faster recovery times, reduced perioperative morbidity and mortality, and improved return periods to work or sports.<sup>[1-3]</sup> With the help of strict patient selection criteria, advances in surgical techniques such as using intramedullary guides for condylar component positioning, improved implant and instrumentation designs, better polymer material processing and other factors, the literature indicates a five-year cumulative survival rate of UKAs ranging from 98.7 to 100% and a 10-year survival rate of 92 to 97.4%.<sup>[4]</sup> However, UKA is considered

## ABSTRACT

**Objectives:** This study aims to compare the radiological outcomes of unicompartmental knee arthroplasty (UKA) performed by a navigation-based robotic system versus Microplasty® instrumentation.

**Patients and methods:** Between January 2018 and January 2019, a total of 90 knees of 75 patients (65 males, 10 females; mean age: 62.0±9.4 years; range, 50 to 73 years) were included. Among these, 54 knees underwent Oxford mobile-bearing UKA with an Microplasty® instrumentation set and 36 knees were operated with the aid of a Restoris® MCK with MAKO navigation-based robotic system. Postoperative anteroposterior and lateral X-rays of all patients were evaluated according to nine different parameters. On the femoral side, femoral varus-valgus angle, flexion-extension angle, femoral condyle posterior fit; on tibial side, tibial component varus/valgus, tibial posterior slope, medial, anterior, posterior and lateral fit of tibial component assessed.

**Results:** There was no significant difference between groups in terms of age, sex, and affected side. On the femoral side, no significant difference was observed in the component position between groups. On the tibial side, tibial component medial fit (p=0.032) and anterior fit (p=0.007) were better in navigation-based robotic system group.

**Conclusion:** Microplasty® instrumentation may lead to comparable implant positioning compared to a tactile-based navigated robotic instrumentation.

**Keywords:** Component alignment, Microplasty®, navigation, robotics, unicompartmental knee arthroplasty.

Received: June 04, 2022

Accepted: August 16, 2022

Published online: October 21, 2022

**Correspondence:** Osman Görkem Muratoğlu, MD. İstinye Üniversitesi Tıp Fakültesi, Ortopedi ve Travmatoloji Anabilim Dalı, 34010 Zeytinburnu, İstanbul, Türkiye.

E-mail: osman.muratoglu@istinye.edu.tr

Doi: 10.52312/jdrs.2022.742

**Citation:** Çabuk H, Turan K, Muratoğlu OG, Ergün T, Öztürk Ç, Ertürer RE. Comparison of the radiological parameters between dynamic-referencing tactile guidance robotic system and Microplasty® instrumentation in unicompartmental knee arthroplasty. Jt Dis Relat Surg 2022;33(3):580-587.

©2022 All right reserved by the Turkish Joint Diseases Foundation

This is an open access article under the terms of the Creative Commons Attribution-NonCommercial License, which permits use, distribution and reproduction in any medium, provided the original work is properly cited and is not used for commercial purposes (<http://creativecommons.org/licenses/by-nc/4.0/>).

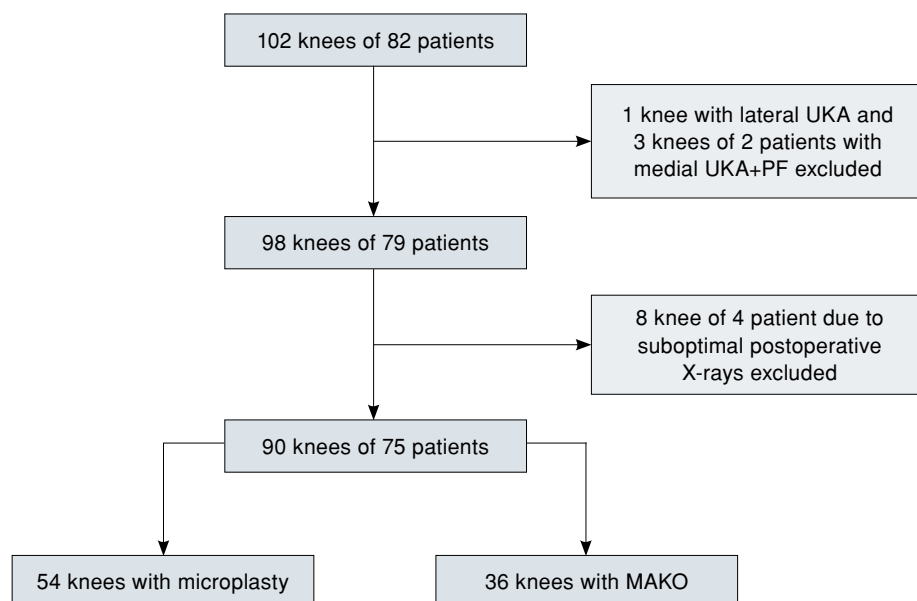
to be technically challenging to perform by many orthopedic surgeons. It has been shown that improper limb or implant alignment is the primary cause of early UKA failure associated with aseptic implant loosening, excessive polyethylene wear, and disease progression in the non-involved compartment.<sup>[5,6]</sup>

Recent advances in navigation and robotics may provide a useful tool to assist the surgeon in planning the operation and increasing the accuracy of intraoperative placement of implants. Unicompartmental knee arthroplasty is one of the surgeries best suited for this type of technology, since it uses a relatively small implant and requires complex surgical planning and challenging bone preparation.<sup>[7]</sup> Based on a pre-planned cutting volume, surgeon can freely move the bone with a tactile robot and robot allows the surgeon to remove out of that volume. Dynamic-referencing tactile-guidance robotic systems use optical motion capturing technology which dynamically tracks femur and tibia via marker arrays fixed on them. This allows the surgeon to adjust limb position and orientation freely during bone cutting. These robot-assisted surgical techniques have been shown to improve implant placement following UKA compared to conventional manual techniques utilizing improved bone preparation.<sup>[8]</sup> However, the main concerns of robotic systems are prolonged operation time, high installation cost, and additional radiation exposure time with image-based systems, particularly in low-volume centers performing under 100 UKA per year.<sup>[9,10]</sup>

The Oxford UKA, which is the most commonly performed UKA, has demonstrated excellent functional outcomes and long-term survival by the

Oxford group.<sup>[11]</sup> A new instrumentation known as Microplasty<sup>®</sup> (Zimmer Biomet, Bridgerd, United Kingdom) was introduced in 2011 to make surgery easier and improve the reproducibility of component positioning. The instrumentation has a stylus system to ensure a more consistent tibial resection level, a femoral drill guide linked to an intramedullary rod to improve femoral orientation, and slotted saw guides.<sup>[12,13]</sup> It has been shown that Microplasty<sup>®</sup> instrumentation for Oxford mobile-bearing UKA is more accurate and precise compared to both the conventional fixed-bearing UKA and the phase III instrumentation of Oxford UKA.<sup>[14,15]</sup>

Although the Microplasty<sup>®</sup> instrumentation and robot-assisted surgery have gained popularity performing UKA, to the best of our knowledge, there is no study comparing these techniques in terms of radiological parameters yet. This, indeed, constitutes the motivation of the work presented herein. In the present study, we aimed to compare the Microplasty<sup>®</sup> instrumentation with a dynamic-referencing tactile-guidance robotic system (MAKO/Stryker) in terms of implant positioning while performing UKA. Our hypothesis was that Microplasty<sup>®</sup> instrumentation could provide similar implant positioning as dynamic-referencing tactile-guidance robotic system did.



**FIGURE 1.** Study flowchart.

## PATIENTS AND METHODS

This single-center, retrospective, cross-sectional study was conducted at Istinye University, Department of Orthopedics and Traumatology, between January 2018 and January 2019. Radiological images of the patients who underwent UKA were examined utilizing hospital Picture Archiving and Communication Systems (Synapse 3D® software; Fujifilm Medical, Tokyo, Japan). There were 82 patients and a total of 102 knees were operated during this period. Patients with previous limb surgery, hip replacement and knee arthrosis due to previous trauma were excluded from the study. Patients with lateral UKA and medial UKA with patellofemoral resurfacing arthroplasty were also excluded. Additionally, suboptimal images that were not suitable for evaluation were excluded. Finally, a total of 90 knees of 75 patients (65 males, 10 females; mean age: 62.0±9.4 years; range, 50 to 73 years) were included in the study (Figure 1). Among these, 54 knees underwent Oxford mobile-bearing UKA with an Microplasty® instrumentation set (Zimmer Biomet, Bridgerd, United Kingdom), and 36 knees were operated with the aid of a Restoris® MCK with MAKO navigation-based robotic system (Restoris MCK/w MAKO Stryker Orthopaedics, Kalamazoo, MI, USA). All operations were carried out by two experienced surgeons who perform over 50 UKA cases per year over the last five years.

In all patients, anteroposterior (AP) radiographs aligned on the tibial component and lateral radiographs aligned on the femoral component were chosen for the evaluation. All radiographs were assessed by a single observer according to the criteria described in the manufacturer's surgical technique guide (Oxford Partial Knee Microplasty® Instrumentation Surgical Technique). Nine different parameters were collected from each radiograph (Figure 2).

On the femoral side, femoral component varus/valgus angle relative to femur was measured as the acute angle between the femoral component and the femoral diaphyseal axis in the coronal plane on the screened short leg X-rays (Figure 2a). The diaphyseal axis was drawn from the femoral notch to a point bisecting the cortex at a point 10 cm proximal to the notch position. Femoral component flexion/extension angle was measured as the acute angle between a line through the center of the femoral peg and the femoral axis in the lateral short leg screened view in UKA with Zimmer Biomet Oxford partial knee (Figure 2d). However, in the

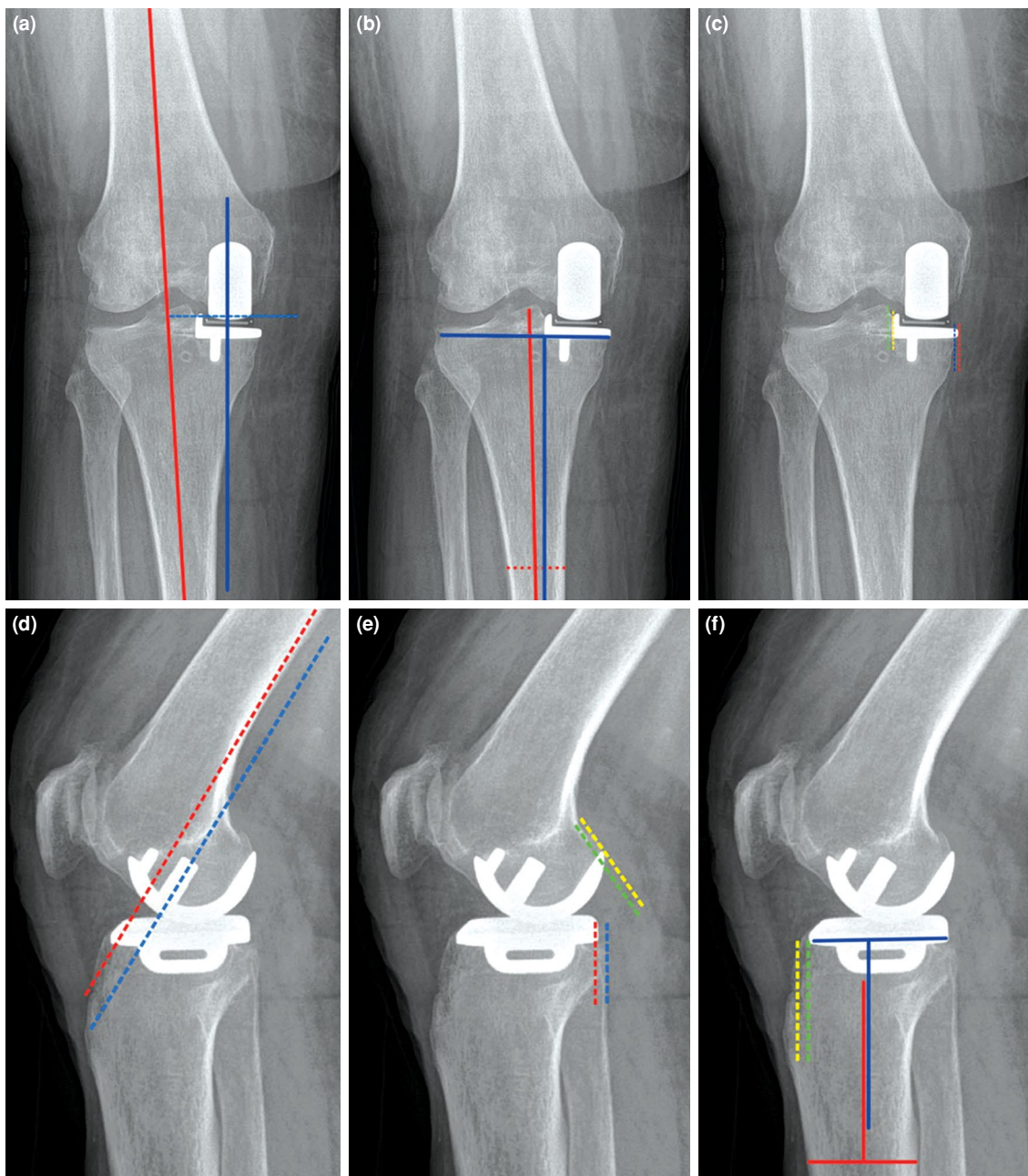
Restoris® MCK UKA, there is a 30° angle between the femoral condyle axis and the femoral peg, which was subtracted from the measured angle while evaluating the femoral component flexion/extension on Restoris® MCK UKA (Figure 3). Femoral component posterior fit was measured as the distance from the posterior tip of femoral component to posterior part of the femoral condyle (Figure 2e).<sup>[16]</sup>

On the tibial side, tibial component varus/valgus angle relative to the tibia was measured as the acute angle between a line perpendicular to the tibial axis and a line drawn across the tibial tray in the coronal plane on a short leg screened X-ray (Figure 2b). The axis was drawn between the midpoint of the spines, and a point bisecting the cortex 10 cm distal to this point. Tibial component posteroinferior tilt was measured as the acute angle between a line drawn along the tibial tray and a line perpendicular to the tibial axis in the lateral short leg screened view (Figure 2f). Tibial component medial fit was measured as the distance between medial spike of tibial component to lateral border of vertical bone cut (Figure 2c). Tibial component posterior fit was measured as distance between posterior tip of tibial component with posterior edge of tibia plateau (Figure 2e), and anterior fit was taken as the distance between anterior tip of tibial component with anterior edge of tibia plateau (Figure 2f). Tibial component lateral fit was measured as the distance between lateral edge of tibial component to lateral edge of tibial plateau (Figure 2c).<sup>[16]</sup>

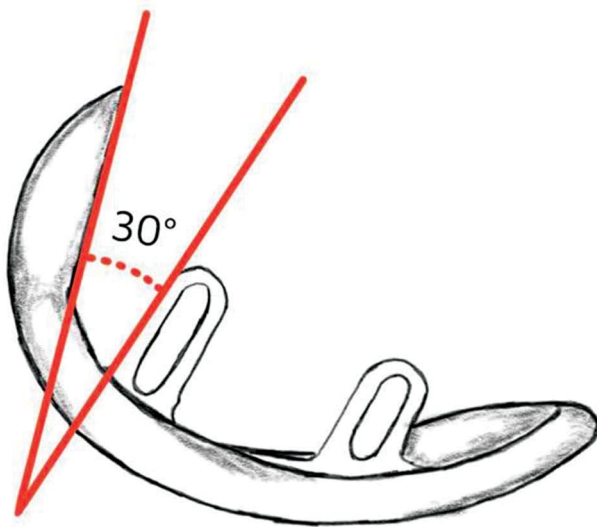
According to the manufacturer's surgical technique guide of Oxford Partial Knee, there are values that are accepted as in the range and literature with robotic navigation systems which mainly evaluates whether they are within the desired position versus implanted position. As the main objective of this study was to compare the radiological results in terms of normal anatomy, we attempted to provide the exact values rather than putting them in groups of a normal range.

### Statistical analysis

Statistical analysis was performed using the IBM SPSS version 20.0 software (IBM Corp., Armonk, NY, USA). Continuous variables were expressed in mean ± standard deviation (SD) or median (min-max), while categorical variables were expressed in number and frequency. The distributions of the variables were examined using the Kolmogorov-Smirnov test. Quantitative data were examined using the independent t-test for quantitative values, while the chi-square test was used to analyze qualitative data.



**FIGURE 2.** Measurements of implant positions in anteroposterior and lateral X-rays. **(a)** Measurements of femur and blue is the axis of femoral component. **(b)** Tibial component varus-valgus angle, red and blue lines are the mechanical axis of tibia and coronal axis of the tibial component, respectively. **(c)** Tibial component medial and lateral congruency, blue dashed line indicates medial border of tibial plateau, red and yellow dashed line is the medial and lateral borders of tibial component, green dashed line is the medial border of medial tibial eminence) and **(d)** Lateral femoral component flexion-extension angle, red dashed line is parallel to the posterior cortical line of femur, blue dashed line indicates the sagittal axis of femoral component and peg holes. **(e)** Femoral and tibial component posterior congruency, red dashed line is the posterior border of tibial component and blue dashed line is posterior border of tibial plateau, green dashed line indicates posterior condylar axis and yellow dashed line is started from the tip of posterior border of femoral component and goes to the parallel of the green line. **(f)** Tibial component anterior congruency and posterior tilt, Red line indicates tibial mechanical axis, blue line is the sagittal axis of tibial component, green dashed line is anterior margin of tibial component and parallel to sagittal axis of tibial component, yellow dashed line anterior border of tibial plateau and goes parallel to the green dashed line) radiographic views.



**FIGURE 3.** Restoris® MCK UKA has a 30° angle between the femoral condyle axis and the femoral peg.  
UKA: Unicompartmental knee arthroplasty.

The measurements on radiographs were examined using an independent test. A  $p$  value of  $<0.05$  was considered statistically significant.

## RESULTS

There were 34 right knees and 20 left knees in the Microplasty® group, whereas 21 right and 15 left knees were included in the MAKO group ( $p=0.572$ ). Both groups had similar baseline data.

There were nine different parameters considered in all the AP and lateral X-rays. On the femoral side, there was no significant difference between the two groups in terms of femoral varus/valgus angle, flexion/extension angle, and posterior fit ( $p=0.063$ ,  $p=0.375$  and  $p=0.071$ , respectively) (Table I). On the tibial side, however, tibial component medial fit ( $p=0.032$ ) and anterior fit ( $p=0.007$ ) were better in the MAKO group. There were no significant differences in the other measurements (Table I).

TABLE I					
Baseline characteristics of patients					
	Microplasty		Mako		$p$
	n	Mean±SD	n	Mean±SD	
Age (year)		62.9±9.6		60.6±9.3	0.658
Sex					0.781
Male	8		7		
Female	49		29		
Side					0.572
Right	34		21		
Left	20		15		

SD: Standard deviation.

TABLE II			
Results of the measurements			
	Microplasty	Robotic assisted	$p^*$
Femoral-side			
Varus/valgus ( $^{\circ}$ ±SD)	6.59±5.06	4.00±3.32	0.063
Flexion-extension ( $^{\circ}$ ±SD)	4.88±3.87	6.72±9.55	0.375
Posterior congruency (mm±SD)	1.70±1.77	0.66±1.94	0.071
Tibial-side			
Varus/valgus ( $^{\circ}$ ±SD)	3.04±1.95	3.50±2.4	0.482
Posterior tilt ( $^{\circ}$ ±SD)	6.18±3.02	6.33±3.39	0.879
Congruency (mm±SD)			
Medial	1.81±1.98	0.66±1.14	<b>0.032*</b>
Posterior	0.81±1.46	0.61±1.57	0.660
Anterior	1.18±1.66	0.05±0.23	<b>0.007*</b>
Lateral	0.03±0.19	0.0±0.0	0.420

SD: Standard deviation; Comparison of the groups on independent samples t-test, P values lower than 0,05 are considered as significant. \* Notice the tibial medial and anterior congruency were better in robotic-assisted group.

## DISCUSSION

The present study showed that Microplasty<sup>®</sup> implantation of UKA could be comparative with robotic system in terms of component alignment. Although popularity of robotic systems has recently increased, the majority of the UKAs are still performed conventionally. Following the release of Microplasty<sup>®</sup> instrumentation in 2011, it has been shown that Microplasty<sup>®</sup> instrumentation increases the accuracy of implant positioning compared to the older version phase III instrumentation. A comparison of the Microplasty<sup>®</sup> instrumentation with the phase III instrumentation revealed that there was no femoral component out of the prespecified range (0-10°) in the case of Microplasty<sup>®</sup> as opposed to 30% out-of-range placements in the case of phase III instrumentation. On the tibial side, the success rates were 24% and 18%, favoring Microplasty<sup>®</sup> instrumentation, and overall, the success rates were 44% and 18%, favoring Microplasty<sup>®</sup>.<sup>[14]</sup>

It was shown by Cobb et al.<sup>[17]</sup> that, with a robotic technique, implant positioning in the coronal plane was within 2° of the computed tomography plan for all cases, whereas with the use of conventional techniques it was within 2° of the computed tomography plan in only 40% of the cases. In this study conducted in 2016, Cobb et al.<sup>[17]</sup> used an older version of the Oxford UKA. Following the release of Microplasty<sup>®</sup> instrumentation, Ng et al.<sup>[15]</sup> showed that it was more accurate and precise compared to conventional fixed-bearing UKA in sagittal, coronal, and axial alignment. The femoral drill guide linked to an intramedullary rod and a stylus system for tibial cut improved the femoral orientation and slotted saw guides of tibia, resulting in a more accurate implant positioning. In our study, we compared the Microplasty<sup>®</sup> instrumentation with the navigation-tracked tactile robotic system MAKO, and we found no significant difference in component positioning on the femoral side, although the results slightly favored the MAKO in terms of varus-valgus positioning. Also, there was no significant difference in the tibial component alignment, except for the medial and anterior fit. This difference between the two different UKA designs could be due to different sizing options of Oxford UKA with Restoris<sup>®</sup> UKA tibial base plate: there were seven sizes in the Oxford UKA and eight in the Restoris<sup>®</sup> UKA.

Postoperative mechanical axis alignments with 8° of varus or more and varus under corrections of 5° are associated with significantly high

polyethylene wear rates and revisions.<sup>[18,19]</sup> However, even an overcorrection changing the mechanical axes from varus to valgus indicates significantly a higher risk of lateral compartment degeneration and cartilage wear rates.<sup>[18]</sup> High tibial slopes over 7° is associated with the increased loosening rates.<sup>[20]</sup> Consequently, to minimize the early implant failure and polyethylene wear, over- and undercorrections should be avoided. The target for the navigated specification of mechanical alignment must be 0° with a 2° to 3° tolerance. Dunbar et al.<sup>[21]</sup> reported averaged placement errors of 1.6 mm/3° along any single axis for femoral component and 1.5 mm/2.6° along any single axis for the tibial component using a tactile-guided robotic system from MAKO surgical group in 20 knees. Lonner et al.<sup>[22]</sup> examined an image-free navigation system on cadavers and obtained results with an accuracy in the ranges of 0.8 mm to 1.3 mm of translation and 1° to 2° of alignment in all planes both in femoral and tibial components. Similarly, Khare et al.<sup>[23]</sup> compared a navigated robotic system with conventional methods and found that maximum femoral implant orientation error was less than 2.81° for the robotically navigated approach and less than 7.52° for the conventional approach, while on the tibial side the implant orientation error was 2.96° to 4.06°, favoring the navigational approach. Cobb et al.<sup>[17]</sup> compared a conventional method with an image-free navigated system instrumentation and found more accurate positioning in both components with robotic system; however, they reported longer operation times and three complications out of 13 knees in case of robotic system, as opposed to only one complication out of 15 knees in the conventional group. However, Jenny et al.<sup>[24]</sup> compared 60 UKA operated with minimally invasive surgery with 60 navigation-guided surgery and found no significant difference between the rates of patients in both groups' achieving the desired implant position.

The experience of surgeon is also an important factor for component alignment. An experienced surgeon can achieve 66% component alignment within the preoperative target, exceeding published values in a study comparing robotics (58%) with manual (41%) UKA.<sup>[25,26]</sup> All the operations in our study were performed by two experienced surgeons. This can be the reason that the results can be comparative in two systems.

Despite many reports of robotic systems increasing the proper implant positions, there are still concerns about these systems. These computed

tomography-based systems align the components using a three-dimensional visualization, yet they fail to incorporate soft tissue tension into planning, such as gap kinematics. Besides, their utility significantly increases the operation duration, including a set-up time of the robotic system which is held by a specialized technician.<sup>[8]</sup>

Nonetheless, there are some limitations to this study. First, since this is a one-year, cross sectional study, the number of patients included in the robotic group is relatively small and, thus, the effect of component positions on clinical results was unable to be analyzed. Second, our study only aims to compare radiological implant position, which may not represent the functional status of patients and patient satisfaction. When we analyzed the power of the study according to femoral component varus-valgus alignment, the power of the study turned out to be 88%. Furthermore, we compared two different implant designs, but made corrections to match each other.

The main strength of this study is that all operations were performed by two senior surgeons who are highly experienced in performing UKA with high caseloads. Overall, we show that Microplasty<sup>®</sup> instrumentation may lead to comparable implant positioning compared to a tactile-based navigated robotic instrumentation.

In conclusion, accurate implant alignment is important in UKA. Our study results indicate that Microplasty<sup>®</sup> instrumentation is associated with comparable implant positioning compared to a tactile-based navigated robotic instrumentation in experienced hands. Nevertheless, further large-scale, well-designed studies are needed to confirm these findings.

**Ethics Committee Approval:** The study protocol was approved by the Istinye University Ethics Committee (date: 2/2020 no: K432). The study was conducted in accordance with the principles of the Declaration of Helsinki.

**Patient Consent for Publication:** A written informed consent was obtained from each patient.

**Data Sharing Statement:** The data that support the findings of this study are available from the corresponding author upon reasonable request.

**Author Contributions:** Contribute the design and writing of manuscript: H.Ç.; Contribute the data analyzing and archiving: K.T., O.G.M.; Contribute for the design and forming of figures: E.E.; Contribute the analyzing of figures and collection of data and literature search: Ç.Ö., T.E.

**Conflict of Interest:** The authors declared no conflicts of interest with respect to the authorship and/or publication of this article.

**Funding:** The authors received no financial support for the research and/or authorship of this article.

## REFERENCES

1. Çankaya D, Aktı S, Ünal ŞB, Sezgin EA. Unicompartmental knee arthroplasty results in a better gait pattern than total knee arthroplasty: Gait analysis with a smartphone application. *Jt Dis Relat Surg* 2021;32:22-7.
2. Brown NM, Sheth NP, Davis K, Berend ME, Lombardi AV, Berend KR, et al. Total knee arthroplasty has higher postoperative morbidity than unicompartmental knee arthroplasty: A multicenter analysis. *J Arthroplasty* 2012;27(8 Suppl):86-90.
3. Hopper GP, Leach WJ. Participation in sporting activities following kneereplacement: Total versus unicompartmental. *Knee Surg Sports Traumatol Arthrosc* 2008;16:973-9.
4. Campi S, Pandit HG, Dodd CAF, Murray DW. Cementless fixation in medial unicompartmental knee arthroplasty: A systematic review. *Knee Surg Sports Traumatol Arthrosc* 2017;25:736-45.
5. Saenz CL, McGrath MS, Marker DR, Seyler TM, Mont MA, Bonutti PM. Early failure of a unicompartmental knee arthroplasty design with an all-polyethylene tibial component. *Knee* 2010;17:53-6.
6. Atik OŞ, Sever GB. The survivorship of unicompartmental knee arthroplasty is poorer compared with total knee arthroplasty. *Jt Dis Relat Surg* 2021;32:274-5.
7. Jaramaz B, Nikou C. Precision freehand sculpting for unicondylar knee replacement: Design and experimental validation. *Biomed Tech (Berl)* 2012;57:293-9.
8. Beyaz S. A brief history of artificial intelligence and robotic surgery in orthopedics & traumatology and future expectations. *Jt Dis Relat Surg* 2020;31:653-5.
9. Begum FA, Kayani B, Morgan SDJ, Ahmed SS, Singh S, Haddad FS. Robotic technology: Current concepts, operative techniques and emerging uses in unicompartmental knee arthroplasty. *EFORT Open Rev* 2020;5:312-8.
10. Nherera LM, Verma S, Trueman P, Jennings S. Early economic evaluation demonstrates that noncomputerized tomography robotic-assisted surgery is cost-effective in patients undergoing unicompartmental knee arthroplasty at high-volume orthopaedic centres. *Adv Orthop* 2020;2020:3460675.
11. Pandit H, Jenkins C, Gill HS, Barker K, Dodd CA, Murray DW. Minimally invasive Oxford phase 3 unicompartmental knee replacement: Results of 1000 cases. *J Bone Joint Surg [Br]* 2011;93:198-204.
12. Hurst JM, Berend KR, Adams JB, Lombardi AV Jr. Radiographic comparison of mobile-bearing partial knee single-peg versus twin-peg design. *J Arthroplasty* 2015;30:475-8.
13. Hurst JM, Berend KR. Mobile-bearing unicondylar knee arthroplasty: The Oxford experience. *Clin Sports Med* 2014;33:105-21.
14. Malhotra R, Kumar V, Wahal N, Clavé A, Kennedy JA, Murray DW, et al. New instrumentation improves patient satisfaction and component positioning for mobile-bearing medial unicompartmental knee replacement. *Indian J Orthop* 2019;53:289-96.
15. Ng JP, Fan JCH, Lau LCM, Tse TTS, Wan SYC, Hung YW. Can accuracy of component alignment be improved with

- Oxford UKA Microplasty® instrumentation? *J Orthop Surg Res* 2020;15:354.
16. Sarmah SS, Patel S, Hossain FS, Haddad FS. The radiological assessment of total and unicompartmental knee replacements. *J Bone Joint Surg [Br]* 2012;94:1321-9.
  17. Cobb J, Henckel J, Gomes P, Harris S, Jakopec M, Rodriguez F, et al. Hands-on robotic unicompartmental knee replacement: A prospective, randomised controlled study of the acrobot system. *J Bone Joint Surg [Br]* 2006;88:188-97.
  18. Collier MB, Engh CA Jr, McAuley JP, Engh GA. Factors associated with the loss of thickness of polyethylene tibial bearings after knee arthroplasty. *J Bone Joint Surg [Am]* 2007;89:1306-14.
  19. Hernigou P, Deschamps G. Alignment influences wear in the knee after medial unicompartmental arthroplasty. *Clin Orthop Relat Res* 2004;(423):161-5.
  20. Hernigou P, Deschamps G. Posterior slope of the tibial implant and the outcome of unicompartmental knee arthroplasty. *J Bone Joint Surg [Am]* 2004;86:506-11.
  21. Dunbar NJ, Roche MW, Park BH, Branch SH, Conditt MA, Banks SA. Accuracy of dynamic tactile-guided unicompartmental knee arthroplasty. *J Arthroplasty* 2012;27:803-8.e1.
  22. Lonner JH, Smith JR, Picard F, Hamlin B, Rowe PJ, Riches PE. High degree of accuracy of a novel image-free handheld robot for unicondylar knee arthroplasty in a cadaveric study. *Clin Orthop Relat Res* 2015;473:206-12.
  23. Khare R, Jaramaz B, Hamlin B, Urish KL. Implant orientation accuracy of a hand-held robotic partial knee replacement system over conventional technique in a cadaveric test. *Comput Assist Surg (Abingdon)* 2018;23:8-13.
  24. Jenny JY, Ciobanu E, Boeri C. The rationale for navigated minimally invasive unicompartmental knee replacement. *Clin Orthop Relat Res* 2007;463:58-62.
  25. Bush AN, Ziemba-Davis M, Deckard ER, Meneghini RM. An Experienced surgeon can meet or exceed robotic accuracy in manual unicompartmental knee arthroplasty. *J Bone Joint Surg [Am]* 2019;101:1479-84.
  26. Bell SW, Anthony I, Jones B, MacLean A, Rowe P, Blyth M. Improved accuracy of component positioning with robotic-assisted unicompartmental knee arthroplasty: Data from a prospective, randomized controlled study. *J Bone Joint Surg [Am]* 2016;98:627-35.